

TOMOGRAPHIC DIMENSIONS FOR THE INSTALLATION OF RAPID MAXILLARY EXPANSION MINI-IMPLANTS IN DIFFERENT AGE GROUPS

Dimensiones tomográficas para la instalación de miniimplantes de expansión rápida maxilar en diferentes grupos de edad

Alina K. Cardozo-Muñoz,¹ Marcos J. Carruitero.^{1,2}

1. Escuela de Odontología, Universidad Católica Santo Toribio de Mogrovejo, Chiclayo, Perú.

2. Escuela de Medicina Humana, Universidad Privada Antenor Orrego, Trujillo, Perú.

ABSTRACT

Objective: The purpose of the research was to compare the dimensions of the upper jaw between different age groups for the installation of mini-implants for rapid maxillary expansion.

Materials and Methods: The study was descriptive, retrospective and observational. Cone beam computed tomography was used for the evaluation of 30 patients between 7 and 56 years of age, divided into three groups, ten up to 14 years, ten from 15 to 30 years, and ten from 31 years and older. The premolar and molar regions were selected for the measurement of the maxilla in the coronal plane, both bone and soft tissue. To compare the measurements, the Kruskal Wallis and Mann-Whitney U tests were used.

Results: No statistically significant differences were found between the groups. The thicknesses of the bone tissue decreased from the first premolar to the second molar from 9.48 +/-3.71 mm to 5.40 +/-2.80 mm respectively, while the soft tissue thicknesses were more homogeneous with measurements of 0.56 +/-0.74 mm to 2.76 +/- 2.42 mm.

Conclusions: The dimensions of the bone and soft tissue of the upper jaw, evaluated vertically for the installation of mini-implants, were similar in all the age groups studied, with larger dimensions in men than in women at the premolar level. The dimensions of the maxilla for the palatal miniimplants were close to 9 mm in bone tissue and 3 mm of soft tissue at the level of premolars and 5 mm in hard tissue with 1 mm of soft tissue at the level of molars.

Keywords: *Palatal expansion technique; Dental implants; Mini implants; Maxilla; Cone-beam computed tomography; Age groups*

RESUMEN

Objetivo: El propósito de la investigación fue comparar las dimensiones del maxilar superior entre diferentes grupos de edad para la instalación de miniimplantes de expansión rápida maxilar (ERM).

Materiales y Métodos: El estudio fue descriptivo, retrospectivo y observacional. Se utilizaron tomografías computarizadas de haz cónico para la evaluación de 30 pacientes entre 7 a 56 años de edad, divididos en tres grupos, diez hasta 14 años, diez de 15 a 30 años y diez de 31 años a más. Se seleccionaron las regiones de premolares y molares para la medición del maxilar en el plano coronal, tanto de tejido óseo como blando. Para comparar las medidas se utilizaron las pruebas Kruskal Wallis y U de Mann-Whitney.

Resultados: No se encontraron diferencias estadísticamente significativas entre los grupos. Los grosores del tejido óseo fueron disminuyendo desde el primer premolar hasta el segundo molar de 9.48 +/-3.71 mm hasta 5.40 +/-2.80 mm respectivamente, mientras que los de tejido blando fueron más homogéneos con medidas de 0.56 +/-0.74 mm hasta 2.76 +/-2.42 mm.

Conclusión: Las dimensiones del tejido óseo y blando del maxilar superior, evaluadas en sentido vertical para la instalación de miniimplantes, fueron similares en todos los grupos de edad estudiados, con mayores dimensiones en hombres que en mujeres a nivel de premolares. Las dimensiones del maxilar para los miniimplantes palatinos se acercaron a los 9 mm en el tejido óseo y 3 mm de tejido blando a nivel de premolares y 5 mm en tejido duro con 1 mm de tejido blando a nivel de molares.

Palabras Clave: *Técnica de Expansión Palatina; Implantes dentales; Mini-implantes; Maxilar; Tomografía computarizada de haz cónico; Grupos de edad*

CORRESPONDING AUTHOR: Marcos J. Carruitero.
Universidad Católica Santo Toribio de Mogrovejo. Avda San Josemaría Escrivá de Balaguer #855, Chiclayo, Perú. E-mail: m_carruitero@hotmail.com

CITE AS: Cardozo-Muñoz AK & Carruitero MJ. Tomographic dimensions for the installation of rapid maxillary expansion mini-implants in different age groups. *J Oral Res.* 2023; 12(1): 288-298. doi:10.17126/joralres.2023.025

Received: February 03, 2023

Accepted: October 09, 2023

Published online: December 30, 2023

ISSN Print 0719-2460

ISSN Online 0719-2479.

INTRODUCTION

Rapid maxillary expansion (RME) is considered a common treatment for transverse maxillary deficiencies,¹⁻⁴ present in all age groups,⁵ which consists of increasing the transverse dimension of the maxilla using different types of devices that achieve considerable maxillary expansion.⁶⁻⁸ Knowledge of the linear values of the upper jaw is the basis for planning orthodontic treatments that require RME,⁹⁻¹¹ such as mini-implant-assisted rapid palatal expansion (MARPE), which generates an increase significant in the transverse maxillary skeletal dimension, showing a more parallel radiolucency of the palatal suture than traditional methods, causing fewer collateral effects on the posterior teeth, such as the greater angulation of the molars generated by dental support methods.⁸

Palate has become an important site for the placement of anchorage devices, due to its bone quantity and quality,⁹ especially if RME is desired.⁶ The morphology of the craniofacial region is predominantly controlled by genetic factors; however, functional demands can have a significant effect on growth and development.^{10,12} The width of palate increases from the primary to the permanent stage, the palatal height and the palatal height index decrease from the primary to the mixed dentition and then increase from the mixed to the permanent dentition.^{11,13} However, it is necessary to know if these dimensional changes also occur with age in the area where mini-implants for RME are usually placed.

Eslami *et al.*,¹¹ observed a progressive increase in various measurements of the palate from birth to the period of permanent dentition. Berwig *et al.*,¹⁴ indicated that the dimensions

of the maxilla were different according to sex, being larger in men. Liu *et al.*¹⁵ indicated that the thickness of the palate was influenced by sex, age, and their interaction. Mallick *et al.*¹⁶ evaluated the thickness of the cortical bone of the lingual and palatal jaws to choose the optimal locations to place the mini-implants, but they did it just at the interradicular level. To perform RME, the mini-implants need to be placed in the region paramedial to the palatine raphe.¹⁷ By comparing the dimensions of the upper jaw between different age groups using computed tomography in this region, it could provide more information to the orthodontist about the base dimensions in both hard and soft tissue to take into account when selecting mini-implants for RME.

The purpose of the study was to compare the dimensions of the jaw between different age groups for the installation of RME mini-implants.

MATERIALS AND METHODS

The execution of this research work was approved by the research committee of the Santo Toribio de Mogrovejo Catholic University, with resolution number 199-2022-USAT-FMED.

An observational, descriptive, retrospective study was carried out. The study population was made up of patients who attended a local radiological center in the city of Trujillo, Peru, between 2021 and 2022, from which a sample of 30 tomography scans was extracted, in which 1260 tomographic sectors were evaluated. The sample was calculated using the formula for comparison of means, with data obtained from a pilot study, carried out with 168 tomographic sectors from first premolars to second molars

(42 sectors per tooth) obtained from tomography scans of two patients who were not considered in the final study. For this calculation, a confidence level of 99.5%, a maximum type I error of 0.01, power of 95%, a maximum type II error of 0.05, variances of 3.9 and 2.4, as well as a maximum estimated difference of 4.1 mm, obtained in said pilot study, was considered. The calculation result was 6.68, with which a sample of 7 was obtained, which was finally rounded up to 10 tomographies per group.

The inclusion criteria were: tomography scans taken in the period 2021-2022 by a single type of tomographic equipment and with the same parameters.

The exclusion criteria were: tomography scans with defects in the shot, which make it difficult to determine the dimensions of the maxilla, that do not have a report on the degree of magnification of the shot, patients without complete permanent dentition up to upper second molars, tomography scans of patients with orthodontic appliances, patients with previous orthognathic or orthodontic surgery, anomalies, trauma or craniofacial syndromes reported in the radiological center.

Planmeca dental image processing software ProMax 3D Mid (MCT-1, J. Morita Mfg. Corp., Kyoto, Kyoto-fu, Japan) with the following settings were used:

Anodic voltage 60–90kV, 60–120kV, anodic current 1-14 mA, focal spot 0.5mm, fixed anode, flat screen image detector, image acquisition 200/360-degree rotation, recovery time scanning 9–33 seconds, typical reconstruction time 2–55 seconds and maximum volume without stitching Ø20 x 10 cm.

The dimensions considered for the present study were the height of the upper jaw, both soft tissue and bone tissue, according to the method proposed by Lyu.¹⁵ Measurements were made at the level of each posterior tooth: first premolars (P1), second premolars (P2), first molars (M1) and second molars (M2), with a separation of 1 mm between each measurement, -10 to +10 mm, with the palatine raphe being measurement 0 (Figure 1).

Method error

The error of the method was evaluated with 42 tomographic sectors (corresponding to two patients, 168 tomographic sectors at each observation moment) through inter-examiner calibration between the researcher and a specialist radiologist, after the researcher's training; and intra-examiner calibration between the same researcher at two different times, with two weeks of separation between measurements.

In order to evaluate the agreement, the Intra-class Correlation Coefficient was used, obtaining values greater than 0.90 ($p < 0.05$) for both measurements.

Statistic analysis

The data were processed using the SPSS Statistics 22.0 statistical program (IBM, Armonk, NY, USA). The means, standard deviations, medians, minimum and maximum values were calculated. To determine the comparison of the dimensions of the upper jaw between the different age groups, the Kruskal Wallis test was used for multiple comparisons and the Mann-Whitney U test for post-hoc comparisons and for comparisons between men and

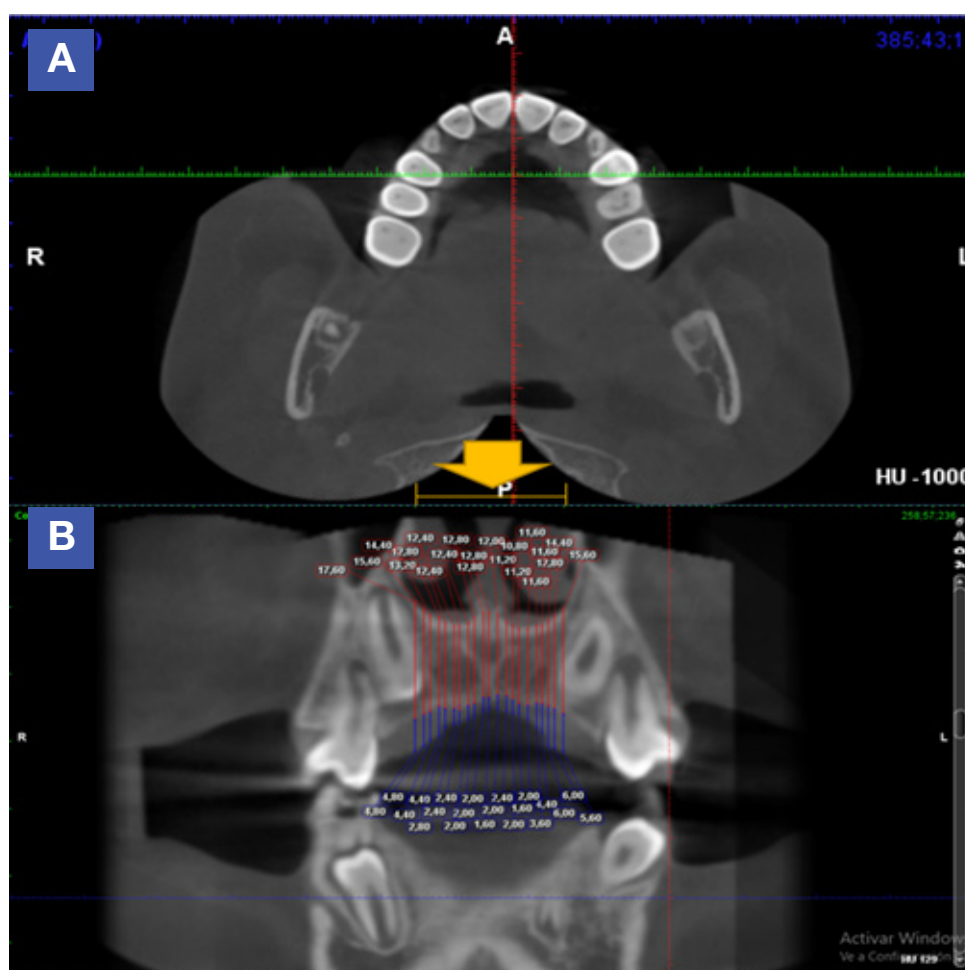
women, due to non-compliance assumption of normality, evaluated using the Shapiro-Wilk test. A significance level of 5% was considered.

RESULTS

A number of 30 tomography scans of subjects between 7 and 56 years of age were evaluated, divided into three groups of 10 tomography each: up to 14 years (11.30 +/-2.45, range: 7 - 14 years), from 15 to 30 years (23.20 +/- 4.83, range:

17 - 30 years) and from 31 years and older (41.90 +/- 7.92, range: 31 - 56 years); of which 16 were women (24.06 +/-14.31, range: 7 - 56 years) and 14 were men (27.07 +/-13.73, range: 11 - 49 years). No statistically significant differences were found between the age groups studied ($p > 0.05$). The bone tissue thicknesses decreased from the first premolar to the second molar from 9.48 +/- 3.71 mm to 5.40 +/-2.80 mm respectively, while the soft tissue thicknesses were more homogeneous with measurements

Figure 1. Representative tomographic image of the measurement of the height of the maxillary bone, carried out at the level of the upper first premolars, in the axial plane, in A. In B, the coronal plane is shown at the level of the first premolars themselves with the 11 measurements made for both soft tissue (in blue) and bone tissue (in red), with a separation of 1 mm for each measurement, as seen in the area with the yellow arrow.



of 0.56 +/- 0.74 mm up to 2.76 +/- 2.42 mm. In the group up to 14 years of age, bone tissue thicknesses ranged between 5.12 +/- 3.53 mm at the level of the second premolar and 7.84 +/- 5.76 mm at the level of the first premolar; while in the soft tissue they ranged between 0.80 +/- 0.60 mm at the level of the first molar and 2.72 +/- 3.06 mm at the level of the first premolar. In the group aged 31 years or older, bone tissue thicknesses ranged between 5.72 +/- 1.90 mm at the level of the second molar and 9.48 +/- 3.71 mm at the level of the first premolar; while in the soft tissue they ranged between 0.56 +/-

0.74 mm at the level of the first molar and 2.76 +/- 2.42 mm at the level of the first premolar (Table 1). When comparing the dimensions according to sex, it was observed statistically significant differences between males and females at the level of the 1st premolar in the soft tissue ($p=0.008$), where a greater dimension was observed in men, with 5.90 +/- 2.00 mm, which, in women, with 3.60 +/- 1.00 mm. Similarly, in the 2nd premolar bone tissue ($p= 0.034$), with a greater dimension in men, with 8.80 +/- 3.19 mm, than in women, with 6.40 +/- 0.80 mm.

Table 1 . Comparison of the dimensions of the upper jaw between the different groups of age in study.

Dimensions of the upper jaw	Age groups	n	Mean	SD	Range	Me	IR	p-value*
1st premolar bone tissue (n=30)	Up to 14 years	10	7.84	5.76	16.8	7.2	11.2	0.253
	15 to 30 years	10	9.48	3.71	12.0	9.0	5.8	
	31 years or more	10	5.84	4.91	14.8	6.4	9.5	
1st soft tissue premolar (n=30)	Up to 14 years	10	2.72	3.06	8.0	1.8	5.1	0.905
	15 to 30 years	10	2.24	1.57	5.6	2.0	1.8	
	31 years or more	10	2.76	2.42	8.0	2.4	2.8	
2nd premolar bone tissue (n=30)	Up to 14 years	10	5.12	3.53	10.4	6.0	6.5	0.309
	15 to 30 years	10	7.60	2.53	8.8	7.2	1.5	
	31 years or more	10	6.68	2.39	8.4	6.0	3.2	
2nd premolar soft tissue (n=30)	Up to 14 years	10	1.00	1.53	5.2	0.4	0.9	0.911
	15 to 30 years	10	0.76	0.97	2.8	0.4	1.6	
	31 years or more	10	0.88	0.98	2.8	0.8	1.4	
1st molar bone tissue (n=30)	Up to 14 years	10	5.76	2.54	8.0	7.0	3.7	0.836
	15 to 30 years	10	5.76	1.56	4.8	5.8	2.8	
	31 years or more	10	5.72	2.24	6.8	5.6	4.0	
1st soft tissue molar (n=30)	Up to 14 years	10	0.80	0.60	1.6	1.0	1.2	0.382
	15 to 30 years	10	0.56	0.74	2.0	0.2	1.0	
	31 years or more	10	1.04	0.87	2.4	1.0	1.7	
2nd molar bone tissue (n=30)	Up to 14 years	10	5.40	2.80	8.4	6.2	3.7	0.766
	15 to 30 years	10	6.40	1.96	5.2	6.8	3.8	
	31 years or more	10	5.72	1.90	6.4	6.4	2.42	
2nd molar soft tissue (n=30)	Up to 14 years	10	1.36	2.16	7.2	1.0	1.6	0.681
	15 to 30 years	10	1.16	0.79	2.4	1.2	1.1	
	31 years or more	10	0.92	0.63	2.0	0.8	0.7	

*: Kruskal Wallis test. **SD:** Standard Deviation. **Me:** Median. **IR:** Interquartile Range.

Table 2. Comparison of the dimensions of the upper jaw between the different age groups, according to sex.

Maxilla dimensions	Age groups	Male (n=14)					Female (n=16)					MF Comparison
		n	Mean	SD	Me	p-value*	n	Mean	SD	Me	p-value*	p-value**
1 st premolar bone tissue	Up to 14 years	4	10.30	6.08	10.60		6	6.20	5.44	6.00		0.286
	15 to 30 years	5	11.20	3.96	10.80	0.476	5	7.76	2.81	6.40	0.317	0.117
	31 years or more	5	8.56	4.06	6.40		5	3.12	4.39	0.00		0.117
1 st premolar soft tissue	Up to 14 years	4	5.90 ^b	2.00	5.80		6	3.60	1.00	0.00		0.008
	15 to 30 years	5	1.76 ^a	1.43	1.20	0.029	5	2.72	1.71	2.00	0.108	0.395
	31 years or more	5	3.52 ^b	2.64	2.80		5	2.00	2.17	2.00		0.399
2 nd premolar bone tissue	Up to 14 years	4	6.20	4.45	7.20		6	4.40	3.00	6.00		0.234
	15 to 30 years	5	8.80	3.19	7.60	0.678	5	6.40	0.80	6.40	0.588	0.034
	31 years or more	5	7.04	3.27	6.00		5	6.32	1.34	6.00		0.915
2 nd premolar soft tissue	Up to 14 years	4	0.60	0.52	0.60		6	1.27	1.97	0.40		0.912
	15 to 30 years	5	0.48	0.72	0.00	0.822	5	1.04	1.19	0.80	0.998	0.432
	31 years or more	5	0.88	1.18	0.40		5	0.88	0.87	1.20		0.913
1 st molar bone tissue	Up to 14 years	4	6.20	1.74	6.60		6	5.47	3.08	7.00		0.668
	15 to 30 years	5	6.09	1.62	6.40	0.763	5	5.44	1.61	5.20	0.845	0.675
	31 years or more	5	5.44	2.13	5.60		5	6.00	2.56	5.60		0.834
1 st molar soft tissue	Up to 14 years	4	1.10	0.20	1.20		6	0.60	0.70	0.40		0.264
	15 to 30 years	5	0.40	0.40	0.40	0.080	5	0.72	1.00	0.00	0.958	0.911
	31 years or more	5	1.36	0.96	1.60		5	0.72	0.72	0.80		0.242
2 nd molar bone tissue	Up to 14 years	4	6.80	1.35	7.40		6	4.47	3.23	5.40		0.238
	15 to 30 years	5	6.32	2.18	6.40	0.643	5	6.48	1.97	7.20	0.572	0.834
	31 years or more	5	5.52	2.36	6.40		5	5.92	1.56	6.40		0.916
2 nd molar soft tissue	Up to 14 years	4	0.30	0.60	0.00		6	2.07	2.59	1.40		0.077
	15 to 30 years	5	1.60	0.63	1.60	0.053	5	0.72	0.72	0.80	0.408	0.091
	31 years or more	5	1.12	0.52	0.80		5	0.72	0.72	0.80		0.448

*: Kruskal Wallis test. **: Different superscript letters indicate difference (Mann-Whitney U). SD: Standard Deviation.

Me: Median.

Likewise, statistically significant differences were found in the thickness of the soft tissue ($p=0.029$) between the group up to 14 years old and the group from 15 to 30 years old, where the latter showed lower thickness with 1.76 +/- 1.43 mm (Table 2).

DISCUSSION

Mini-implant-assisted for RME, or MARPE, is a means of expanding basal bone without surgical intervention in adolescent patients¹⁸ and young adults,⁸ which has been shown to

be a treatment modality that is associated with a high success rate in maxillary expansion, skeletal and dental,¹⁹ which is why it is important to know how the dimensions of the maxilla are manifested, in the palatal region, where the mini-implants intended to be used with MARPE are placed.

The findings of the present study showed no evidence of differences in the dimensions of the upper jaw for the insertion of rapidly expanding mini-implants between the age groups studied; however, the dimensions decreased from the first premolar to the second

molar in a similar way to that reported by Oh *et al.*,²⁰ while those of soft tissue were more homogeneous, agreeing with Yadav *et al.*²¹

Although the age groups studied were constructed based on what was reported by previous studies,^{11,14-16,20,21} the possibility of conducting more studies should be taken into account considering different age groups or other characteristics such as types of dentition, the stages of growth, dental calcification, skeletal age or biological age and not just chronological age.

It was identified that the areas with the greatest bone height in the group up to 14 years of age ranged between 5.12 +/- 3.53 mm at the level of the second premolar and 7.84 +/- 5.76 mm at the level of the first premolar, which is why they could be considered that the most favorable dimensions of mini-implants in young people could range between 5 to 8 mm. The dimensions of the soft tissue ranged between 0.80 +/- 0.60 mm at the level of the first molar and 2.72 +/- 3.06 mm at the level of the first premolar, important information to take into account the length of the transmucosal region of the mini-implant to be used with the MARPE, from which it follows that mini-implants with a smaller transmucosal area would be required in the molar region than for the premolar region.

Regarding the areas of greatest bone thickness in the group aged 31 years or older, they ranged between 5.72 +/- 1.90 mm at the level of the second molar and 9.48 +/- 3.71 mm at the level of the first premolar; while the dimensions of the soft tissue ranged between 0.56 +/- 0.74 mm at the level of the first molar and 2.76 +/- 2.42 mm at the level of the first premolar, coinciding with the studies of

Mallick *et al.*,¹⁶ with similar values.

On the other hand, Hu *et al.*,²² states that between the second premolars and the first molar were the areas between which most of the values were concentrated.

The bone tissue measurements in patients in the 15 to 30 year old group recorded the highest measurements in P1, P2, M1 and M2, followed by the second age group of 31 years and older, except for P1 in the group up to 14 years old, where it recorded to a greater extent, coinciding with the study by Lyu *et al.*,¹⁵ where the hard tissue was thickest in P1, followed by the planes of P2, M1 and M2, while the thickness of the soft tissue was similar in the four planes.¹⁵

Differences were recorded in P1 for soft tissue in the group up to 14 years old between males and females, and in P2 for hard tissue in the group from 15 years to 30 years between males and females. In both cases, larger dimensions were observed in men than in women, similar to what was reported by Berwing *et al.*,¹⁴ who found larger dimensions in men than in women in both the first and second premolars. On the other hand, Eslami *et al.*,¹¹ stated that there are no differences in the height of the palate and in the molar area between men and women, coinciding with this study in the area of M1 and M2.

Yu *et al.*,²² and Ning *et al.*,²⁴ stated that the palatine bone was thicker in men than in women and that there were no sex-related differences in the posterior palate. There was a trend for thickness to decrease in the posterior direction, but less pronounced in women. These results differ from the present study since in the measurements carried out no differences were found according to sex at

the level of the entire bone tissue, but only in the group of 15 to 30 years at the level of the second premolar.

At the level of the palatal soft tissue, the dimensions were greater in men than in women only in the group up to 14 years of age, at the level of the first premolar, which differs from what was reported by Yu *et al.*,²⁵ who found such differences in all the positions.

The present study was a single-center retrospective cross-sectional study, so its sample size, despite having been carried out with 1260 tomographic slices, could be considered restricted and become a limitation, making it necessary to carry out similar prospective studies in other populations, with multicenter approach and with larger samples, a last aspect of great importance since it can affect the results significantly, which is why the findings of the present study should be taken with caution.

However, it is the first time that tomographic measurements of the hard palate and soft tissue have been reported in a sample with characteristics specific to the region, aimed at the use of MARPE, a device that has shown promising expansion results mainly in adults.²⁶ Selection of the appropriate length of the mini-implant for the use of MARPE is an important factor in obtaining good anchorage. The results of the present study show that the lengths of the mini-implants for all groups could be around 9 mm at the premolar level and around 5 mm at the molar level, with transmucosal zones, for soft tissue, close to 3 mm in pre-molars and 1 mm in molars. These reference data are important and could be considered as a basis to more accurately iden-

tify more personalized values in each patient with their own planning tomography.

Likewise, it is important to consider the greater thickness of some dimensions in men, especially at the level of premolars. It is relevant to also take into account the presence of other factors for the success of maxillary disjunction, such as stationary quality, insertion sites, placement procedure, immediate or early loading assignment, minimum compliance with indications by of the patient, the characteristics of the oral mucosa, the state of health of the organism and the quality of oral hygiene.

CONCLUSION

The dimensions of the bone and soft tissue of the upper jaw, evaluated vertically for the installation of mini-implants, were similar in all the age groups studied, with larger dimensions in men than in women at the premolar level. The dimensions of the maxilla for the palatal miniimplants were close to 9 mm in bone tissue and 3 mm of soft tissue at the level of premolars and 5 mm in hard tissue with 1 mm of soft tissue at the level of molars.

CONFLICT OF INTERESTS

The authors declare that they have no conflicts of interest.

ETHICS APPROVAL

This research work was approved by the research committee of the Santo Toribio de Mogrovejo Catholic University, with resolution number 199-2022- USAT-FMED.

FUNDING

The research was funded with the principal investigator ACM's own resources.

AUTHORS' CONTRIBUTIONS

Alina K. Cardozo-Muñoz: Data curation; formal analysis; funding acquisition; investigation; project administration; resources; writing – original draft.

Marcos J. Carruitero: Conceptualization; methodology; supervision; writing – original draft; writing – review and editing.

ACKNOWLEDGEMENTS

We thank Drs. Miriam Arellanos and Rosa Roncal, for their valuable support in methodological aspects of the study.

ORCID

Alina K. Cardozo-Muñoz

 0000-0003-0966-1254

Marcos J. Carruitero

 0000-0001-8339-5076

PUBLISHER'S NOTE

All statements expressed in this article are those of the authors alone and do not necessarily represent those of the publisher, editors, and reviewers.

COPYRIGHT

This is an open-access article distributed under the terms of the [Creative Commons Attribution License \(CC BY 4.0\)](https://creativecommons.org/licenses/by/4.0/). The use, distribution or reproduction in other forums is permitted, provided the original author(s) and the copyright owner(s) are credited and that the original publication in this journal is cited, in accordance with accepted academic practice. No use, distribution or reproduction is permitted which does not comply with these terms. © 2023.



PEER REVIEW

This manuscript was evaluated by the editors of the journal and reviewed by at least two peers in a double-blind process.

PLAGIARISM SOFTWARE

This manuscript was analyzed by Turnitin's Original plagiarism detector software. Analysis report of document (ID. 3d45e5b5b96a781076485a7efb73e9bcd6d5a57c)

ISSN Print 0719-2460 - ISSN Online 0719-2479.

<https://www.joralres.com/index.php/JOralRes/issue/archive>

REFERENCES.

1. Davoudi A, Amrolahi M, Khaki H. Effects of laser therapy on patients who underwent rapid maxillary expansion; a systematic review. *Lasers Med Sci.* 2018;33(6):1387–95.
2. Cannavale R, Chiodini P, Perillo L, Piancino MG. Rapid palatal expansion (RPE): Meta-analysis of long-term effects. *Orthodox Craniofac Res.* 2018;21(4):225–35.
3. Lyu CX, Yang L, Chen LL, Yu FY, Lu HP. [Advance and review: miniscrew-assisted rapid palatal expansion]. *Zhonghua Kou Qiang Yi Xue Za Zhi.* 2019;54(11):778-782. Chinese. doi: 10.3760/cma.j.isn.1002-0098.2019.11.011. PMID: 31683387.
4. Cunha ACD, Lee H, Nojima LI, Nojima MDCG, Lee KJ. Miniscrew-assisted rapid palatal expansion for managing arch perimeter in an adult patient. *Dental Press J Orthod.* 2017;22(3):97-108. doi: 10.1590/2177-6709.22.3.097-108.oar. PMID: 2874 6493; PMCID: PMC5525451.
5. Brunetto DP, Sant'Anna EF, Machado AW, Moon W. Non-surgical treatment of transverse deficiency in adults using Microimplant-assisted Rapid Palatal Expansion (MARPE). *Dental Press J Orthod.* 2017;22(1):110-125. doi: 10.1590/2177-6709.22.1.110-125.sar. PMID: 28444019; PMCID: PMC5398849.
6. de la Iglesia G, Walter A, de la Iglesia F, Winsauer H, Puigdollers A. Stability of the anterior arm of three different Hyrax hybrid expanders: an in vitro study. *Dental Press J Orthod.* 2018;23(1):37-45. doi: 10.1590/2177-6709.23.1.037-045.oar. PMID: 29791684; PMCID: PMC5962246.
7. Choneima A, Abdel-Fattah E, Hartsfield J, El-Bedwehi A, Kamel A, Kula K. Effects of rapid maxillary expansion on the cranial and circummaxillary sutures. *Am J Orthod Dentofacial Orthop.* 2011; 140(4):510-9. doi: 10.1016/j.ajodo.2010.10.024. PMID: 21967938; PMCID: PMC5161454.
8. Rojas V, Macherone C, Zursiedel MI, Valenzuela JG. Rapid maxillary expansion in young adults: comparison of tooth-borne and bone-borne appliances, a cohort study. *J Oral Res* 2019; 8(3):201-209. doi: 10.17126/joralres.2019.031
9. Chang CJ, Lin WC, Chen MY, Chang HC. Evaluation of total bone and cortical bone thickness of the palate for temporary anchorage device insertion. *J Dent Sci.* 2021;16(2):636-642. doi: 10.1016/j.jds.2020.09.016. Epub 2020 Oct 21. PMID: 33854713; PMCID: PMC8025190.
10. Negishi S, Richards LC, Hughes T, Kondo S, Kasai K. Genetic contribution to palatal morphology variation using three-dimensional analysis in Australian twins. *Arch Oral Biol.* 2020;115:104740. doi: 10.1016/j.archoralbio.2020.104740. Epub 2020 May 5. PMID: 32417704.
11. Eslami Amirabadi G, Golshah A, Derakhshan S, Khandan S, Saeidipour M, Nikkardar N. Palatal dimensions at different stages of dentition in 5 to 18-year-old Iranian children and adolescent with normal occlusion. *BMC Oral Health.* 2018 15;18(1):87. doi: 10.1186/s12903-018-0538-y. PMID: 29764428; PMCID: PMC5952467.
12. Cantarella D, Dominguez-Mompell R, Moschik C, Mallya SM, Pan HC, Alkahtani MR, Elkenawy I, Moon W. Midfacial changes in the coronal plane induced by microimplant-supported skeletal expander, studied with cone-beam computed tomography images. *Am J Orthod Dentofacial Orthop.* 2018;154(3):337-345. doi: 10.1016/j.ajodo.2017.11.033. PMID: 30173836.
13. Angelieri F, Cevidanes LH, Franchi L, Gonçalves JR, Benavides E, McNamara JA Jr. Midpalatal suture maturation: classification method for individual assessment before rapid maxillary expansion. *Am J Orthod Dentofacial Orthop.* 2013;144(5):759-69. doi: 10.1016/j.ajodo.2013.04.022. PMID: 24182592; PMCID: PMC4185298.
14. Berwig LC, Marquezan M, Milanese JM, Montenegro MM, Ardenghi TM, Toniolo da Silva AM. Do gender and age influence hard palate dimensions? A systematic review. *Codas.* 2018;30(5):e20170216. Portuguese, English. doi: 10.1590/2317-1782/20182017 216. PMID: 30379195.
15. Lyu X, Guo J, Chen L, Gao Y, Liu L, Pu L, Lai W, Long H. Assessment of available sites for palatal orthodontic mini-implants through cone-beam computed tomography. *Angle Orthod.* 2020;90(4):516-523. doi: 10.2319/070719-457.1. PMID: 33378492; PMCID: PMC8028458.
16. Mallick S, Murali PS, Kuttappa MN, Shetty P, Nair A. Optimal sites for mini-implant insertion in the lingual or palatal alveolar cortical bone as assessed by cone beam computed tomography in South Indian population. *Orthod Craniofac Res.* 2021;24(1):121-129. doi: 10.1111/ocr.12415. Epub 2020 Aug 20. PMID: 32749047.
17. Caetano GR, Soares MQ, Oliveira LB, Junqueira JL, Nascimento MC. Two-dimensional radiographs versus cone-beam computed tomography in planning mini-implant placement: A systematic review. *J Clin Exp Dent.* 2022;14(8):e669-e677. doi: 10.4317/jced.59384. PMID: 36046172; PMCID: PMC9422966.
18. Cantarella D, Dominguez-Mompell R, Moschik C, Sfolgiano L, Elkenawy I, Pan HC, Mallya SM, Moon W. Zygomaticomaxillary modifications in the horizontal plane induced by micro-implant-supported skeletal expander, analyzed with CBCT images. *Prog Orthod.* 2018;19(1):41. doi: 10.1186/s40510-018-0240-2. PMID: 30345476; PMCID: PMC61 96147.

19. Kapetanović A, Theodorou CI, Bergé SJ, Schols JGJH, Xi T. Efficacy of Miniscrew-Assisted Rapid Palatal Expansion (MARPE) in late adolescents and adults: a systematic review and meta-analysis. *Eur J Orthod.* 2021;43(3):313-323. doi: 10.1093/ejo/cjab005. PMID: 33882127; PMCID: PMC8186837.
20. Oh SH, Lee SR, Choi JY, Kim SH, Hwang EH, Nelson G. Quantitative cone-beam computed tomography evaluation of hard and soft tissue thicknesses in the midpalatal suture region to facilitate orthodontic mini-implant placement. *Korean J Orthod.* 2021;51(4):260-269. doi: 10.4041/kjod.2021.51.4.260. PMID: 34275882; PMCID: PMC8290086.
21. Yadav S, Sachs E, Vishwanath M, Knecht K, Upadhyay M, Nanda R, Tadinada A. Gender and growth variation in palatal bone thickness and density for mini-implant placement. *Prog Orthod.* 2018;19(1):43. doi: 10.1186/s40510-018-0241-1. PMID: 30393829; PMCID: PMC6215790.
22. Hu KS, Kang MK, Kim TW, Kim KH, Kim HJ. Relationships between dental roots and surrounding tissues for orthodontic miniscrew installation. *Angle Orthod.* 2009;79(1):37-45. doi: 10.2319/083107-405.1. PMID: 19123704.
23. Yu SK, Cho Y, Seo YS, Kim JS, Kim DK, Kim HJ. Radiological evaluation of the bone and soft tissue thicknesses of the palate for using a miniscrew-supported maxillary skeletal expander. *Surg Radiol Anat.* 2021;43(6):1001-1008. doi: 10.1007/s00276-020-02634-0. Epub 2021 Jan 2. PMID: 33386930.
24. Ning R, Guo J, Li Q, Martin D. Maxillary width and hard palate thickness in men and women with different vertical and sagittal skeletal patterns. *Am J Orthod Dentofacial Orthop.* 2021;159(5):564-573. doi: 10.1016/j.ajodo.2019.12.023. Epub 2021 Mar 2. PMID: 33674159.
25. Al Amri MS, Sabban HM, Alsaggaf DH, Alsulaimani FF, Al-Turki GA, Al-Zahrani MS, Zawawi KH. Anatomical consideration for optimal position of orthodontic miniscrews in the maxilla: a CBCT appraisal. *Ann Saudi Med.* 2020;40(4):330-337. doi: 10.5144/0256-4947.2020.330. Epub 2020 Aug 6. PMID: 32757983; PMCID: PMC7410228.
26. Cardozo AK, Carruitero MJ. Non-surgical rapid maxillary expansion with mini-implants in adults: A narrative review. *Journal Oral Research.* 2022;11(6):1-14. doi:10.17126/joralres.2022.064