

# EFFICIENCY OF TOPICAL OZONE GEL AS AN ADJUNCT TO ANTIBIOTICS AND ANALGESICS ON SEQUELAE AFTER EXTRACTION OF IMPACTED MANDIBULAR THIRD MOLAR

Eficiencia del gel de ozono tópico como complemento de antibióticos y analgésicos en las secuelas tras la extracción del tercer molar mandibular impactado

Osama A. Alhelu,<sup>1</sup> Zainab F. Mahdi,<sup>2</sup> Balsam Saadi Abdulhameed.<sup>3</sup>

1. Institute of laser for postgraduate studies, University of Baghdad, Iraq.

2. College of Dentistry, University of Baghdad, Iraq.

3. Al-Imamen Al-Kadmen Medical City, Ministry of Health, Iraq.

## ABSTRACT

**Introduction:** Extraction of the impacted mandibular third molar is a common procedure in dentistry. Many complications may arise after this operation, the most common being pain, trismus, and swelling. Systemic medications have been used in an attempt to manage these problems, but because of their side effects, the need for non-medication treatment arises to treat these complications without side effects, such as cryotherapy, ice packs, low-level laser therapy, and ozone. Ozone is one of the most effective antimicrobials used in the dentistry field, and it also has a positive effect on soft tissue healing, activates cellular metabolism, and can react with blood components; for these reasons ozone is used to manage trismus, swelling, and pain after removal of the mandibular third molar. **Aim:** The purpose of the study was to assess the effects of topical ozone gel on complications from the extraction of the impacted mandibular third molar.

**Materials and Methods:** Thirty patients were enrolled in the current study and were randomly divided into two equal groups. Preoperatively clinical examination included measurement of facial swelling measurements and maximum mouth opening. The position and configuration of the impacted lower third molar, the surrounding bone, the mandibular canal, and the neighboring tooth were all assessed using a panoramic X-ray. On days 2 and 7, after surgery, the facial swelling dimensions and maximum mouth opening were again assessed. Statistics were used to analyze results.

**Results:** Findings indicate statistical significance for pain, but not for swelling or mouth opening.

**Conclusions:** After lower third molar surgery, topical ozone gel helps reduce postoperative pain.

**Keywords:** Molar, third; Tooth, impacted; Ozone; Pain; Trismus; Edema.

## RESUMEN

**Introducción:** La extracción del tercer molar mandibular retenido es un procedimiento común en odontología. Pueden surgir muchas complicaciones después de esta operación, siendo las más comunes dolor, trismo e edema. Se han utilizado medicamentos sistémicos en un intento de controlar estos problemas, pero debido a sus efectos secundarios, surge la necesidad de tratamientos sin medicamentos para tratar estas complicaciones sin efectos secundarios, como crioterapia, bolsas de hielo, terapia con láser de baja intensidad y ozono. El ozono es uno de los antimicrobianos más eficaces utilizados en el campo de la odontología, además tiene un efecto positivo en la cicatrización de los tejidos blandos, activa el metabolismo celular y puede reaccionar con los componentes san-guíneos; Por estas razones, el ozono se utiliza para controlar el trismo, la hinchazón y el dolor después de la extracción del tercer molar mandibular. **Objetivo:** El propósito del estudio fue evaluar los efectos del gel de ozono tópico sobre las complicaciones de la extracción del tercer molar mandibular impactado.

**Materiales y Métodos:** Se inscribieron treinta pacientes en el estudio actual y se dividieron aleatoriamente en dos grupos iguales. El examen clínico preoperatorio incluyó la medición de la hinchazón facial y la apertura máxima de la boca. La posición y configuración del tercer molar inferior impactado, el hueso circundante, el canal mandibular y el diente vecino se evaluaron mediante una radiografía panorámica. Los días 2 y 7, después de la cirugía, se evaluaron nuevamente las dimensiones de la hinchazón facial y la apertura máxima de la boca. Se utilizaron estadísticas para analizar los resultados.

**Resultados:** Los hallazgos indican significación estadística para el dolor, pero no para la hinchazón o la apertura de la boca.

**Conclusión:** Después de la cirugía del tercer molar inferior, el gel de ozono tópico ayuda a reducir el dolor postoperatorio.

**Palabras Clave:** Tercer molar; Diente impactado; Ozono; Dolor; Trismo; Edema.

**CORRESPONDING AUTHOR:** Osama A. Alhelu. Institute of laser for postgraduate studies, University of Baghdad, Iraq.  
E-mail: Usama.abdulkadim1202a@ilps.uobaghdad.edu.iq

**CITE AS:** Alhelu OA, Mahdi ZF & Saadi Abdulhameed B. Efficiency of topical ozone gel as an adjunct to antibiotics and analgesics on sequelae after extraction of impacted mandibular third molar. *J Oral Res.* 2023; 12(1): 168-181. doi:10.17126/joralres.2023.015

**Received:** June 13, 2023  
**Accepted:** September 3, 2023  
**Published online:** October 18, 2023  
ISSN Print 0719-2460  
ISSN Online 0719-2479.

## INTRODUCTION

One of the most frequent operations in the field of oral and maxillofacial surgery is third molar surgery. However, this intervention warrants precise planning and surgical experience. Complications with surgical operations in general are always possible. Between 2.6 percent and 30.9 percent of third molar extraction, procedures result in complications. The range of possible issues ranges from moderate, normal post-operative pain and swelling to irreversible nerve damage, mandibular fractures, and life-threatening infections.<sup>1,2</sup>

The most prevalent third molar surgery complications are limited mouth opening, pain, and edema. Pain reaches maximum intensity between three to five hours after local anesthesia has worn off, continues for two to three days, and gradually reduces until the 7<sup>th</sup> day.<sup>3</sup> Swelling reaches peak intensity in 12–48 h, resolving between the 5<sup>th</sup> and 7<sup>th</sup> day.<sup>4</sup> Trismus subsides when pain and edema decrease.<sup>5</sup> They are regarded as the result of tissue damage or infection-related inflammation. Systemic medications such as antibiotics, glucocorticoids, and analgesics, have been used in attempts to manage these problems and achieve satisfactory postoperative recovery.<sup>2,6</sup>

The use of surgical closure procedures with or without the incorporation of drains, cold packs, platelet-rich plasma, platelet-rich fibrin, herbals, and cryotherapy have been recommended as nonpharmacological adjunctive therapies,<sup>7-12</sup> but due to their limited

effectiveness and accompanying side effects, they have not been widely adopted. Ozone therapy and low-level laser therapy (LLLT) have been introduced as these alternatives over the past 20 years.

The stratosphere of the Earth contains Ozone (O<sub>3</sub>) in its gaseous state, with a molecular weight of 48 grams/mol. As a result of changes in temperature and pressure, it is an unstable gas that is regularly converted into oxygen (O<sub>2</sub>).<sup>13,14</sup> Research on this subject supports the use of ozone in the fields of medicine and dentistry. This recommendation is given due to its special effects on the human body, such as its effective antimicrobial action (fungicidal, bactericidal, and virucidal). Other well-known benefits include immunological modulatory and stimulating effects and anti-inflammatory, biosynthetic, anti-hypoxic, and bioenergetics effects.<sup>15-18</sup>

Ozone can be applied topically or parenterally<sup>19</sup> and is available as a gas, gel, or liquid.<sup>20</sup> Ozone therapy's therapeutic success may partly be attributed to the regulated oxidative stress brought on by the reactions of ozone with various biological elements. Ozone can interact with blood components in the right amounts to positively impact oxygen metabolism and cell energy while also triggering antioxidant defense mechanisms.<sup>21</sup> Ozone therapy has been utilized in dentistry to treat temporomandibular joint dysfunction,<sup>25,26</sup> endodontic,<sup>23</sup> and periodontal diseases,<sup>24</sup> as well as caries.<sup>22</sup>

Additionally, this treatment has been appli-

ed during maxillofacial surgery to facilitate hemostasis, improve local oxygen delivery, and reduce discomfort following surgery.<sup>27,28</sup>

In this study, the impact of intra-oral topical ozone therapy was assessed on the post-operative parameters of pain, trismus, and edema as well as patient ozone tolerance. However, the gel form was selected for our study because of advantages,<sup>29</sup> such as ease of application, the existence of a higher concentration of ozone molecules, and the compound's stability for a longer time. Ozone gel may be produced and stored without the use of a complicated arsenal, unlike ozone gas. Additionally, it has been demonstrated that aqueous ozone preserves cell biology more effectively than gaseous ozone.<sup>30</sup> Ozone is present in the gel in the form of ozonides, which release active ozone over an extended time when in contact with a wound surface at the temperature of body.<sup>31</sup>

### Hypothesis

**Ho:** The ozone gel is not-significantly effective in reducing swelling, pain, and trismus following extraction of the mandibular impacted third molar.

**H1:** The ozone gel is significantly effective in the reduction of swelling, trismus, and pain following extraction of the lower impacted third molar.

**Aim:** This clinical trial aims to evaluate ozone gel on pain, trismus, and swelling after removal of impacted mandibular third molar.

## MATERIALS AND METHODS

### Study population

This study was conducted at the Oral Surgery Department at the College of Dentistry/ University of Babil and the Oral Surgery Clinic at the specialized center in Babil government between March and August of 2022.

Participants were registered volunteers for the study after signing the informed consent sheet to participate in the research study and submitted to a questionnaire comprising their name, age, gender, medical history, and dental history followed by a complete clinical and radiographic examination.

### Inclusion criteria

Patients with impacted mandibular third molars (Class II-III and position B, according to Pell and Gregory's classification) who required surgical extraction, should have good oral hygiene, be free of any acute illnesses, and be between the ages of 18 and 40. They should also be willing to comply with the study and be available for follow-up.

### Exclusion criteria

Ozone therapy contraindications, systemic illness, local infection, tobacco use, and pregnancy were among the exclusion criteria. All patients signed a written informed consent after being given information re-garding the study's purpose, the specifics of the surgical procedures, any expected complications, and potential adverse effects of the medications being used.

Following surgery, the patients were given Augmentin® 625 mg (amoxicillin 500mg and

clavulanate 125mg) and Panadol® 500 mg (acetaminophen) as needed.

### Study design

This blind placebo-controlled randomized prospective clinical study involved 30 patients, 12 male and 18 female, aged between 18 and 36 years, with lower impacted third molars in similar positions (Class II-III and B position, according to Pell and Gregory's classification). They were randomly assigned to the study and control groups using the coin toss method, divided in two equal groups, with fifteen patients in each.

**Group (1) (study group):** injection of ozone gel (0.5cc) after removal of impacted mandibular third molar.

**Group (2) (control placebo group):** removal of the impacted mandibular third molar followed by 0.5cc of normal saline was injected into the socket as shown in the flow chart (Figure 4).

### At baseline

1. Radiographic and clinical examination.
2. Measurements of mouth openings were assessed by measuring the maximum distance between the cutting edges of the maxillary and mandibular central incisors. The mouth opening was measured three times using a digital Vernier.
3. Facial measurement, the distances between the lateral corner of the eye and the mandibular angle (line A), the tragus and the outer corner of the mouth (line B), and the tragus and soft tissue pogonion (line C) were measured using a measuring tape and recorded in centimeters,<sup>32</sup> (Figure 5).

The average of the three different values of line A, line B, and line C was calculated and reflected the swelling for that day.<sup>33,34</sup>

The difference between measurements taken before surgery and each postoperative measurement done on the 2<sup>nd</sup> and 7<sup>th</sup> days was recorded.

### At first recall

On the 2<sup>nd</sup> day, the same measurement at baseline was repeated in addition to the measurement of pain using a numeric rating scale (NRS), the intensity of the pain was estimated. Whose ratings range from zero (absence of pain) to ten (the most severe pain conceivable).

### On the second recall

On the 7<sup>th</sup> day, the same measurement on the first recall. Third-molar extractions were performed using local anesthesia, which was obtained by inferior alveolar, lingual, and long buccal nerve block injection using the (lidocaine hydrochloride 2% local anesthetic cartridge 1.8ml with adrenaline 1:80,000 (Septodont®, France).

A three-sided mucoperiosteal flap was then made, and bone was removed using a round bur in a surgical straight handpiece (Castellini®, Germany) with copious saline irrigation to expose the tooth,

Following the extraction of the tooth, the surgical site was adequately irrigated using a normal saline solution (0.9%) then the flap was repositioned, and the wound was stitched. From the incision to the final suturing, the time required for the tooth

extraction was recorded. Patients in the ozone group received 0.5cc of ozonated olive oil gel (purO<sub>3</sub>, USA) inserted into a disposable syringe with a blunt needle in the socket right away following surgery, whereas those in the control group received 0.5cc of regular saline in disposable syringes.

### Statistical analysis

Data description, analysis, and presentation were performed using Statistical Package for Social Science (SPSS version 21, Chicago In press, Illionis, USA), Minimum, maximum, mean, standard deviation (SD), and standard error (SE) for quantitative

**Table 1.** Statistical and descriptive test of age among groups.

Groups	N	Mean	Std. Deviation	Std. Error	Minimum	Maximum	T-test	p-value
Ozone	15	23.400	5.040	1.301	18.000	36.000	0.038	0.970
Control	15	23.467	4.658	1.203	18.000	32.000		

**Table 2.** Descriptive and statistical test of surgical duration among groups.

Groups	Mean	Std. Deviation	Std. Error	Minimum	Maximum	T-test	p-value
Ozone	35.600	4.852	1.253	25.000	43.000	0.149	0.883
Control	35.933	7.176	1.853	27.000	56.000		

**Table 3.** Demographic data among groups.

Variables		Ozone		Control		test	p-value
		N	%	N	%		
Gender <sup>a</sup>	Male	5	33.33	7	46.67	0.556	0.456
	Female	10	66.67	8	53.33		
Classification <sup>a</sup>	Male	6	40.00	5	33.33	0.144	0.705
	Female	9	60.00	10	66.67		
Angulation <sup>a</sup>	Mesioangulation	8	53.33	8	53.33	0.667	1.00
	Vertical	4	26.67	4	26.67		
	Horizontal	1	6.67	2	13.33		
	Distoangulation	2	13.33	1	6.67		
Side <sup>b</sup>	Right	6	40.00	8	53.33	0.536	0.464
	Left	9	60.00	7	46.67		

a: Fisher's exact test. b: chi square

**Table 4.** Statistical and Descriptive test of Pain among groups and time.

Groups	Median	MR1	MR2	Median	MR1	MR2	Wilcoxon	p-value
		2 <sup>nd</sup>			7 <sup>th</sup>		sign rank	
Ozone	2	6.5	11.20	1	0	10.63	3.108	0.002
Control	4	8	19.80	3	0	20.37	3.471	0.001
Mann-Whitney U test		2.704			3.106			
p-value		0.007			0.002			

MR1: Intragroup. MR2: Intergroup.

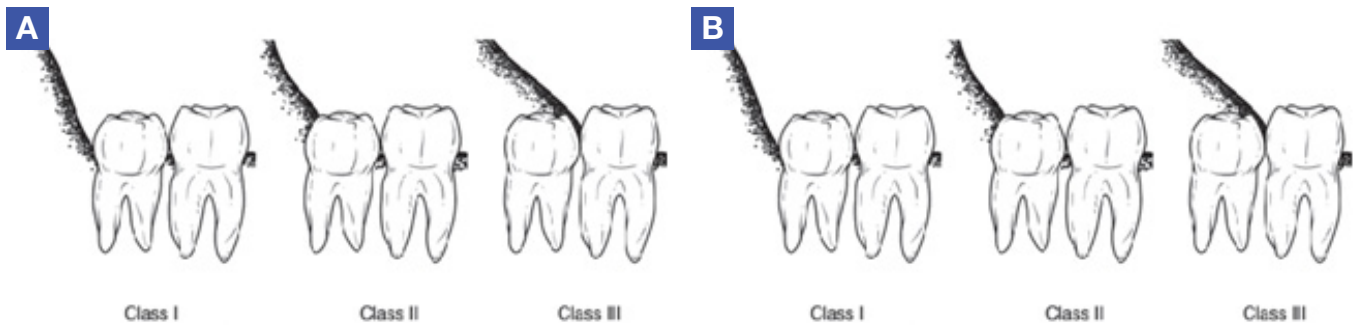
**Table 5.** p-values and mean values ±SD of mouth opening (measured in millimeters) along the different observation periods for all groups.

Groups		Baseline	2-day	7 <sup>th</sup>	F	p-value	ES
Ozone	Min.	29.400	20.500	25.800	14.324	0.000	0.515
	Max.	52.000	46.000	46.300			
	Mean	40.627	30.633	37.433			
	±SD	5.487	7.007	5.195			
Control	Min.	26.000	13.100	21.400	24.036	0.000	0.640
	Max.	50.600	40.900	43.800			
	Mean	41.040	29.400	36.200			
	±SD	6.733	8.033	6.052			
Fisher's exact test (F)	0.034	0.201	0.359				
p-value	0.855	0.658	0.554				

**Table 6.** p-values and mean values ±SD of facial swelling dimensions (in millimeters) along the different observation periods for all groups.

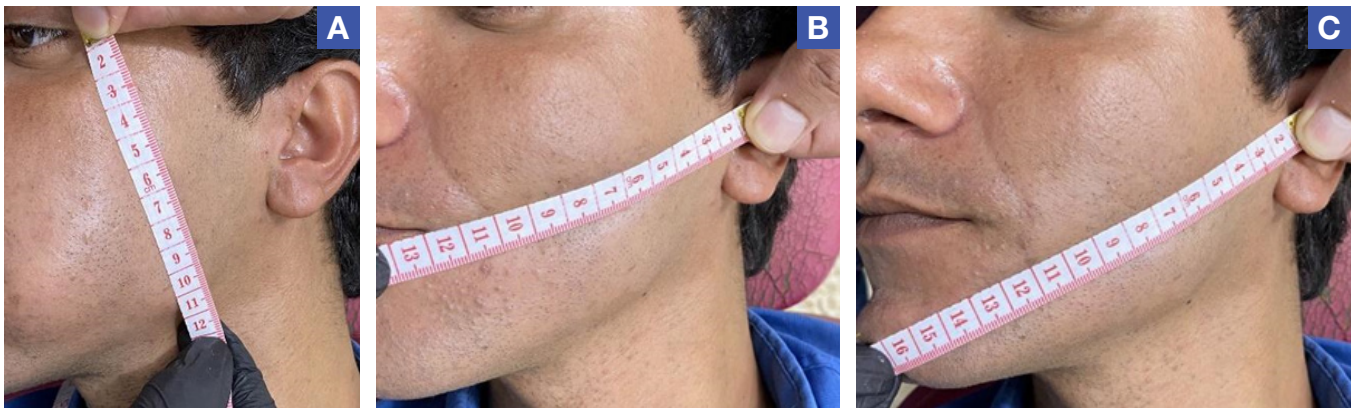Groups		Baseline	2-day	7 <sup>th</sup>	F	p-value	ES
Ozone	Min.	316.000	346.000	327.000	48.487	0.000	0.782
	Max.	367.000	391.000	372.000			
	Mean	343.867	370.267	350.667			
	±SD	14.701	15.975	14.301			
Control	Min.	320.000	341.000	335.000	23.404	0.000	0.634
	Max.	385.000	385.000	385.000			
	Mean	344.067	364.600	353.800			
	±SD	16.211	14.247	14.219			
Fisher's exact test (F)	0.001	1.051	0.362				
p-value	0.972	0.314	0.552				

**Figure 1:** Pell and Gregory classification of the third molar.



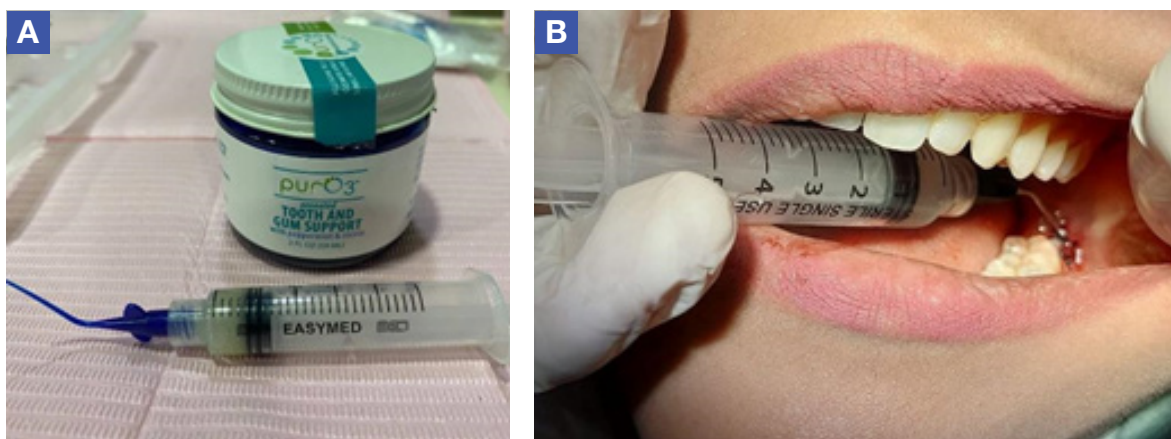
**A:** Pell and Gregory classes I, II, and III.<sup>54</sup> **B:** Classification according to occlusal plane.<sup>54</sup>

**Figure 2:** Facial swelling measurement.

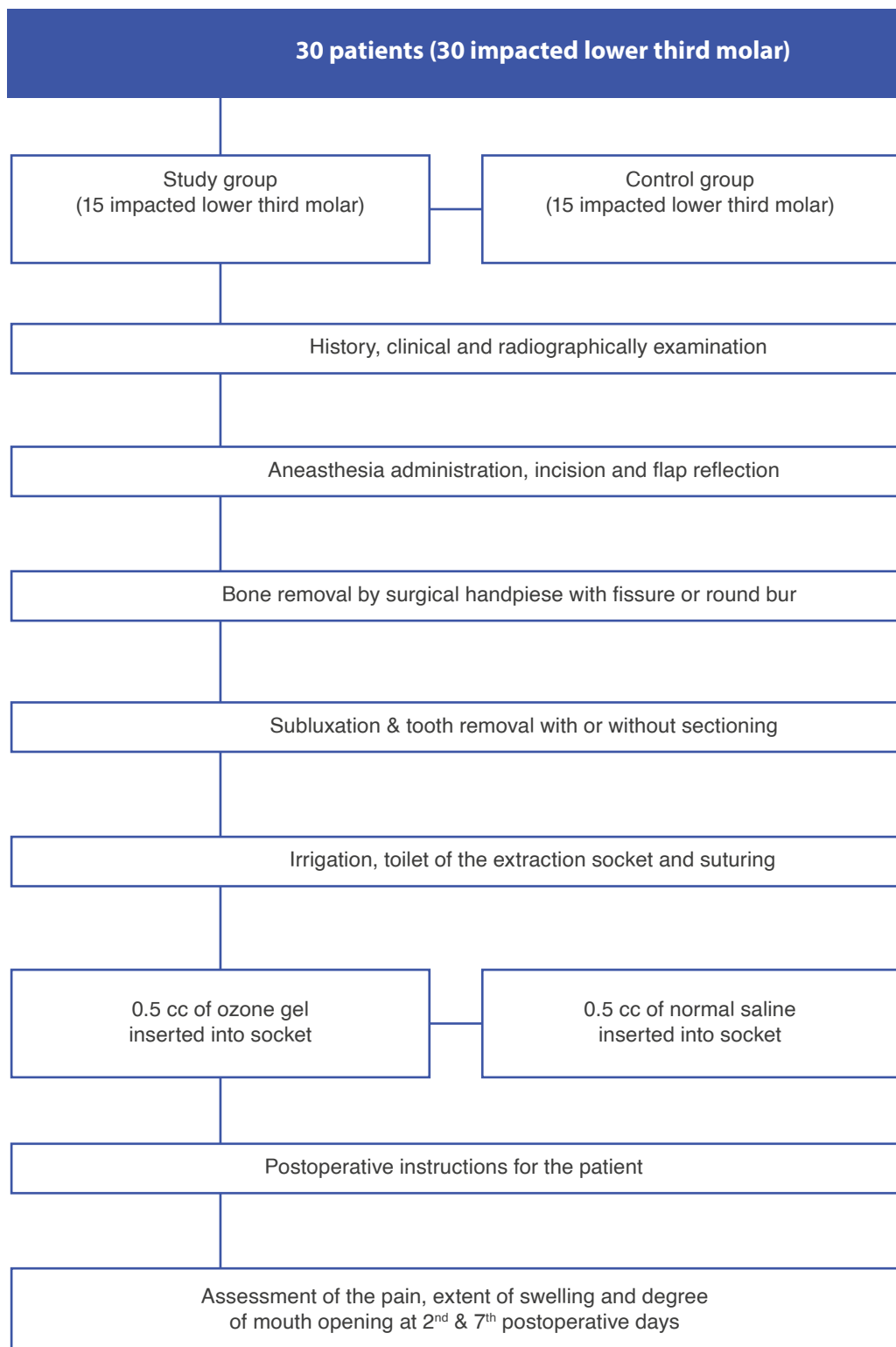


**A:** Pell and Gregory classes I, II, and III.<sup>54</sup> **B:** Classification according to occlusal plane.<sup>54</sup>

**Figure 3:** Application of Ozone gel (PurO<sub>3</sub>, USA) is composed of organic Olea europaea (olive) oil, Stevia rebaudiana (stevia), Cannabis sativa (hemp) seed oil, natural cherry, activated oxygen (ozone), Piperita (peppermint) oil (\*Organic Peppermint and stevia flavor).



**Figure 4.** Study flow chart illustrating the basic steps of the study.





variable while, median, mean rank frequency and percentage for qualitative variable, Fisher exact chi-square, Shapiro Wilk test of normality, Repeated Measure Analysis of variance, Wilcoxon Sign rank test and Mann-Whitney U test.

## RESULTS

Thirty patients with asymptomatic lower impacted third teeth participated in the trial. These had a mean age of  $23.4 \pm 4.8$  years (range, 18–36 years), (Table 1). Thirty tooth extractions were carried out without complications. The average procedure time was  $35.92 \pm 7.1$  min for the control group and  $35.6 \pm 4.8$  min for the ozone group ( $p > 0.05$ ), measuring the duration between the initial surgical incision and the final closure using sutures, (Table 2).

Eleven impacted teeth were classified as cl II and 19 impacted teeth as cl III by Pell and Gregory ( $p > 0.05$ ). Sixteen mesioangulation, eight vertical, three horizontal, and three distoangulation of impacted teeth ( $p > 0.05$ ), (Table 3).

All patients experienced primary healing and no abnormal bleeding throughout the procedures. There was no ecchymosis or hematoma-related alteration in skin color. None of the patients had any negative reactions to the medication or ozone therapy.

Recalled patients had their pain, edema, and trismus assessed. In all assessments (Table 4), the NRS ratings for the ozone group were substantially lesser than those for the control

(placebo) group ( $p$ -values of 0.039 and 0.016 for the second and seventh postoperative days, respectively). 2 patients in the ozone group did not require analgesics.

Both groups experienced trismus and postoperative edema. There was no noticeable difference between the study group and the control group in terms of trismus (Table 5) and edema (Table 6) on the second and seventh days ( $p > 0.05$ ).

## DISCUSSION

One of the most effective antimicrobials utilized in the dentistry field is ozone, which is bactericidal, veridical, and fungicidal.<sup>35</sup> The cell membrane is damaged and disrupted, and the intracellular components are broken down and oxidized, all of which have bactericidal effects. In just a few 10–20 seconds, it eradicates 99% of microflora. Reverse transcriptase inhibits the synthesis of proteins of viral in viruses, and it affects cell development negatively in fungi at selective stages.<sup>36,37</sup> a 3500 times more quickly and effectively than chlorine, ozone may kill and eliminate bacteria.<sup>38</sup> It has rheological characteristics,<sup>39</sup> activates cellular metabolism,<sup>30</sup> and stimulates the expression of cytokines as well as increases intracellular ATP (adenosine triphosphate) concentration.<sup>40</sup>

In particular, the transforming growth factor-B1 (TGF-B1) has a positive impact on the healing of soft tissue injuries.<sup>41</sup> In addition to improving oral soft tissue repair, these growth

factors when activated together with local antioxidant processes, reduce postoperative disturbance and pain.<sup>42</sup>

A frequent clinical symptom of impacted molar removal surgery is pain. Biochemical mediators of inflammation and pain like serotonin, prostaglandins, bradykinin, and histamine are up-regulated as a result of surgical trauma.<sup>43</sup> Such post-operative pain is generally treated with analgesics, which have systemic side effects.<sup>44</sup> However, we found that the NRS scores, which are easily understood by patients and do not require a language translation, accurately indicate post-operative pain. Velio Bocci's alternative theory, which established the inherent analgesic activity of ozone by stimulating the secretion of vasodilators such as nitric oxide (NO),<sup>45</sup> identified the mechanism by which pain is reduced.

Additionally, the initial postoperative phase protective layer of ozone gel above the area of surgery may prevent wound contamination and also covers the exposed nerve ends, greatly lowering pain.

The current study's findings revealed that all groups experienced the most pain during the first two days following surgery. There was a significant difference between the days in each group after that, with the pain score tending to diminish over time until the seventh day.

When comparing to the control (placebo) group, the study group's pain scores decreased ( $p < 0.05$ ) on the second and seventh days.

The results of this study are in agreement with those of Kazancioglu *et al.*,<sup>16</sup> Sivalingam *et al.*,<sup>20</sup> Silva *et al.*,<sup>45</sup> and Bahl *et al.*,<sup>53</sup> who showed that ozone can lessen postoperative pain following surgical removal of the mandibular third molar. However, ozone had no beneficial effect on pain, per the findings of research carried out by Gloria *et al.*<sup>46</sup>

The results of the current study indicated that ozone had no statistically significant impact on trismus. The difference among the groups was, however, statistically not significant ( $p > 0.05$ ). On the 7<sup>th</sup> postoperative day, patients in the ozone group had nearly reached their preoperative mouth opening value, even though the difference among the groups was statistically insignificant. Within the control group, this was not the case. Ozone's analgesic and biosynthetic qualities aid in better wound healing, which is why the ozone group returned to healthy mouth opening more quickly than other groups.<sup>20,47</sup>

The findings of the present study are consistent with those of Kazancioglu *et al.*,<sup>16</sup> who discovered that ozone does not influence trismus. Sivalingam *et al.*,<sup>20</sup> Shokry *et al.*,<sup>48</sup> and Erdemci *et al.*,<sup>49</sup> on the other hand reported an effect. Topical ozone therapy was observed by Sivalingam *et al.*,<sup>20</sup> to significantly lessen postoperative trismus after extraction of the lower impacted third molar, resulting in great patient comfort.

According to Schultze-Mosgau *et al.*,<sup>50</sup> facial edema was measured in the current study, and no appreciable difference was seen between

the control and study groups. While Alkholy *et al.*,<sup>51</sup> reported no statistically significant difference in trismus between the study and control groups, Yousef *et al.*,<sup>52</sup> and Sivalingam *et al.*,<sup>20</sup> found that there is a beneficial effect of ozone on swelling, in disagreement with the result of this study, which is in agreement with the results reported by Kazancioglu *et al.*,<sup>16</sup> who found there is no beneficial effect of ozone on swelling.

## CONCLUSION

Ozone as a supportive therapy may be useful in lowering pain, but it was ineffective in the reduction of trismus and swelling, according to the findings of the current study.

It is impossible to provide a practical suggestion for employing ozone as a supportive therapy to reduce trismus, pain, and swelling in lower third molar extractions due to the limits of this research and the extremely low certainty of the studies' findings. To increase the certainty of the evidence, more standardized protocols must be established for this therapy.

Future research should therefore be done to clarify the effect of ozone therapy in the practice of oral surgery.

## CONFLICT OF INTERESTS

We have no conflict of interest

## ETHICS APPROVAL

Participants provided informed consent to participate in the research study.

## FUNDING

The study is self-funded

## AUTHORS' CONTRIBUTIONS

**Alhelu OA:** Data curation; Writing; Original draft.

**Mahdi ZF:** Supervision; Methodology; Writing, review and editing.

**Abdulhameed BS:** Supervision; Methodology; Writing; Review and editing.

## ACKNOWLEDGEMENTS

Acknowledgments: We are grateful to Dr. Dhiaa El-Din and Dr. Bashar Mohamed for their help in the surgical aspect

## ORCID

Osama A. Alhelu

 0009-0004-7350-1874

Zainab F. Mahdi

 0000-0003-4071-0456

Balsam Saadi Abdulhameed

 0009-0005-8358-3639

## PUBLISHER'S NOTE

All statements expressed in this article are those of the authors alone and do not necessarily represent those of the publisher, editors, and reviewers.

## COPYRIGHT

This is an open-access article distributed under the terms of the [Creative Commons Attribution License \(CC BY 4.0\)](https://creativecommons.org/licenses/by/4.0/). The use, distribution or reproduction in other forums is permitted, provided the original author(s) and the copyright owner(s) are credited and that the original publication in this journal is cited, in accordance with accepted academic practice. No use, distribution or reproduction is permitted which does not comply with these terms. © 2023.



## PEER REVIEW

This manuscript was evaluated by the editors of the journal and reviewed by at least two peers in a double-blind process.

## PLAGIARISM SOFTWARE

This manuscript was analyzed by Turnitin's Original plagiarism detector software. Analysis report of document (ID: a3b3ea3671e047af7d3d3d774c490bad8817f5b1)

ISSN Print 0719-2460 - ISSN Online 0719-2479.

<https://www.joralres.com/index.php/JOralRes/issue/archive>

## REFERENCES.

- Green R, Pynn B, Brauer H. Complications During and After Surgical Removal of Third Molars. *Oral Heal Gr.* 2013;1:1–11.
- Deliverska E, Petkova M. Complications After Extraction of Impacted Third Molars - Literature Review. *J IMAB.* 2016;22(3):1202–11.
- Lago ML, Dinitz FM, Serna RC, Gude-Sampedro F, Gándara Rey JM, García-García A. Relationships between surgical difficulty and postoperative pain in lower third molar extractions. *J Oral Maxillofac Surg.* 2007;65:979–983
- Ra'ed Mohammed Ayoub Al-Delayme, Waleed Kh. Ismael, Mona Abdulhadee Alsafi. Factors associated with facial swelling severity following impacted lower third molar surgery: A prospective study. *J Baghdad Coll Dent.* 2013;25:122-128
- Ferrante M, Petrini M, Trentini P, Perfetti G, Spoto G. Effect of low-level laser therapy after extraction of impacted lower third molars. *Lasers Med Sci.* 2013;28(3):845-9.
- Thaer Abdul Lateef, Salwan Y. H. Bede, Jamal A. Mohammed. The influence of prophylactic Dexamethasone on postoperative swelling and trismus following impacted mandibular third molar surgical extraction. *J Baghdad Coll Dent.* 2010;22:85-90
- Mocan A, Kixsnisxi R, Uçok C. Stereophotogrammetric and clinical evaluation of morbidity after removal of lower third molars by two different surgical techniques. *J Oral Maxillofac Surg.* 1996;54:171–175.
- van der Westhuijzen AJ, Becker PJ, Morkel J, Roelse JA. A randomized observer blind comparison of bilateral facial ice pack therapy with no ice therapy following third molar surgery. *Int J Oral Maxillofac Surg.* 2005;34:281–286.
- Al-Noaman Ahmed Salah. Platelet-rich plasma in oral and dental surgery: A review. *Med J Babylon.* 2021;8:59-65
- Ehsan Mansoor Kadhim, Bushra Karem Amin, Bassam Karem Amin. The Antibacterial Effect of Green Tea on *Enterococcus faecalis*. *med j Babylon.* 2022;19:676-679
- Ali S. Abdul-Kareem, Ali H. Al-Hussaini. Effect of platelet rich-fibrin on alveolar osteitis incidence following surgical removal of impacted mandibular third molars: A comparative study. *j baghdad coll dent.* 2019;34:63-70
- Gelesko S, Long L, Faulk J, Phillips C, Dicus C, White RP Jr. Cryotherapy and topical minocycline as adjunctive measures to control pain after third molar surgery: an exploratory study. *J Oral Maxillofac Surg.* 2011;69:324–332.
- Baysan A, Lynch E. The use of ozone in dentistry and medicine. *Prim Dent Care.* 2005(2):47-52.
- Lynch E. Evidence-based caries reversal using ozone. *J Esthet Restor Dent.* 2008;20(4):218-22.
- Seidler V, Linetskiy I, Hubálková H, Stanková H, Smucler R, Mazánek J. Ozone and its usage in general medicine and dentistry. A review article. *Prague Med Rep.* 2008;109(1):5-13.
- Kazancioglu HO, Kurklu E, Ezirganli S. Effects of ozone therapy on pain, swelling, and trismus following third molar surgery. *Int J Oral Maxillofac Surg.* 2014;43(5):644-8.
- Clavo B, Catalá L, Pérez JL, Rodríguez V, Robaina F. Ozone Therapy on Cerebral Blood Flow: A Preliminary Report. *Evid Based Complement Alternat Med.* 2004;1(3):315-319.
- Stübinger S, Sader R, Filippi A. The use of ozone in dentistry and maxillofacial surgery: a review. *Quintessence Int.* 2006;37(5).
- Bocci V. A. Scientific and medical aspects of ozone therapy. *Arch Med Res.* 2006;37(4):425–435.
- Sivalingam VP, Panneerselvam E, Raja KV, Gopi G. Does topical ozone therapy improve patient comfort after surgical removal of impacted mandibular third molar? A randomized controlled trial. *J Oral Maxillofac surg.* 2017;75(1):51-e1.
- Bocci V. Ozone as Janus: this controversial gas can be either toxic or medically useful. *Mediators inflamm.* 2004;13(1):3–11.
- Lim D, Ngeow WC. A Comparative Study on the Efficacy of Submucosal Injection of Dexamethasone Versus Methylprednisolone in Reducing Postoperative Sequelae After Third Molar Surgery. *J Oral Maxillofac Surg.* 2017;75(11):2278–2286.
- Ajeti NN, Pustina-Krasniqi T, Apostolsk S. The Effect of Gaseous Ozone in Infected Root Canal. *Open Access Maced J Med Sci.* 2018;6(2):389–396.
- Walker K, Perkins M, Dray A. Kinins and kinin receptors in the nervous system. *Neurochem Int.* 1995;26(1):1–26.
- Domb WC. Ozone therapy in dentistry. A brief review for physicians. *Interv neuroradiol.* 2014;20(5):632–636.
- Dray A. Inflammatory mediators of pain. *Br J Anaesth.* 1995;75(2):125–131.
- Bianco E, Maddalone M, Porcaro G, Amosso E, Baldoni M. Treatment of Osteoradionecrosis of the Jaw with Ozone in the Form of Oil-based Gel: 1-year follow-up. *J Contemp Dent Prac.* 2019;20(2):270–276.
- Wang J. Neutrophils in tissue injury and repair. *Cell tissue res.* 2018;371(3):531–539.
- Gupta G, Mansi B. Ozone therapy in periodontics. *J Med Life.* 2012;5:59
- Huth KC, Jakob FM, Saugel B, Cappello C, Paschos E, Hollweck R, Hickel R, Brand K. Effect of ozone on oral cells compared with established antimicrobials. *Eur J Oral Sci.* 2006;114(5):435-40. doi: 10.1111/j.1600-0722.2006.00390.x. PMID: 17026511.

31. Patel PV, Gujjari SK. The Morphometrical and Histopathological Changes which were observed after Topical Ozone Therapy on an Exophytic Fibrous Gingival Lesion: A Case Report. *J Clin Diagn Res.* 2013;7:1239.
32. Latt MM, Kiattavorncharoen S, Boon-siriseth K, Pairuchvej V, Wongsirichat. The efficacy of dexamethasone injection on postoperative pain in lower third molar surgery. *Jdent anesth pain med.* 2016;16:95-102.
33. Raouâa B, Samèh S, Nour B, Abdellatif C, Jamil S. Effects of low-level-laser therapy versus corticotherapy on pain, trismus and edema after surgical removal of third mandibular molars: A comparative study. *Family Med Med Sci Res.* 2013;2:1-4.
34. ZHANG, W., LI, J., LI, Z.-B. & LI, Z. 2018. Predicting postoperative facial swelling following impacted mandibular third molars extraction by using artificial neural networks evaluation. *Sci rep.* 2018;8:12281.
35. Chanem WM, Al-Moudallal Y, Droubi M, Al-Nerabieah Z. Effect of intrasocket application of ozonized olive oil gel on postsurgical pain and soft tissue healing of impacted mandibular third molars surgery: Split-mouth randomized controlled trial. *Int J Dent Oral Sci.* 2021 Feb 12;8(2):1408-14.
36. A SR, Reddy N, Dinapadu S, Reddy M, Pasari S. Role of ozone therapy in minimal intervention dentistry and endodontics - a review. *J Int Oral Health.* 2013 Jun;5(3):102-8.
37. Mohammadi Z, Shalavi S, Soltani MK, Asgary S. A review of the properties and applications of ozone in endodontics: an update. *Iran Endod J.* 2013 Spring;8(2):40-3.
38. Srikanth A, Sathish M, Harsha AV. Application of ozone in the treatment of periodontal disease. *J pharm bioallied sci.* 2013 Jun;5(Suppl 1):89.
39. Verrazzo G, Coppola L, Luongo C, Sammartino A, Giunta R, Grassia A, Ragone R, Tirelli A. Hyperbaric oxygen, oxygen-ozone therapy, and rheologic parameters of blood in patients with peripheral occlusive arterial disease. *Undersea Hyperb Med.* 1995;22(1):17-22. PMID: 7742706.
40. Oosting RS, Van Rees-Verhoef M, Verhoef J, Van Golde LM, Van Bree L. Effects of ozone on cellular ATP levels in rat and mouse alveolar macrophages. *Toxicology.* 1991;70(2):195-202.
41. Bocci V, Luzzi E, Corradeschi F, Silvestri S. Studies on the biological effects of ozone. *J Biol Regul Homeost Agents.* 1994;8(4):108-12
42. Martínez-Sánchez G, Al-Dalain SM, Menéndez S, Re L, Giuliani A, Candelario-Jalil E, et al. Therapeutic efficacy of ozone in patients with diabetic foot. *Eur J Pharmacol.* 2005 Oct 31;523(1-3):151-61.
43. Kim K, Brar P, Jakubowski J, Kaltman S, Lopez E. The use of corticosteroids and nonsteroidal anti-inflammatory medication for the management of pain and inflammation after third molar surgery: a review of the literature. *Oral Surg Oral Med Oral Pathol Oral Radiol Endod.* 2009;107(5):630-40. doi: 10.1016/j.tripleo.2008.11.005. PMID: 19157919.
44. Azuma K, Mori T, Kawamoto K, Kuroda K, Tsuka T, Imagawa T, Osaki T, Itoh F, Minami S, Okamoto Y. Anti-inflammatory effects of ozonated water in an experimental mouse model. *Biomed Rep.* 2014;2(5):671-674. doi: 10.3892/br.2014.290. Epub 2014 May 26. PMID: 25054009; PMCID: PMC4106612.
45. da Silva RP, de Almeida VL, de Andrade Vieira W, Rocha FS, Herval AM, Nascimento GG, Figueiredo CE, Paranhos LR. Is ozone effective in reducing pain, edema, and trismus after third molar surgery? A systematic review. *Research, Society and Development.* 2020 17;9(10):e319108407-.
46. Glória JC, Douglas-de-Oliveira DW, e Silva LD, Falci SG, Dos Santos CR. Influence of ozonized water on pain, oedema, and trismus during impacted third molar surgery: a randomized, triple blind clinical trial. *BMC oral health.* 2020;20:1-9.
47. Balakrishnan G, Narendar R, Kavin T, Venkataraman S, Gokulanathan S. Incidence of Trismus in Transalveolar Extraction of Lower Third Molar *J Pharm Bioallied Sci.* 2017;9(1):222-27.
48. Shokry M, Alshaimaa S. Effect of xenograft-ozonated gel mixture on alveolar bone healing following removal of impacted third molar: A randomized controlled clinical trial. *Egypt Dent J .* 2016;62(4):4749-57.
49. Erdemci F, Gunaydin Y, Sencimen M, Bassorgun I, Ozler M, Oter S, Gulses A, Gunal A, Sezgin S, Bayar GR, Dogan N, Gider IK. Histomorphometric evaluation of the effect of systemic and topical ozone on alveolar bone healing following tooth extraction in rats. *Int J Oral Maxillofac Surg.* 2014;43(6):777-83. doi: 10.1016/j.ijom.2013.12.007. Epub 2014 Jan 31. PMID: 24491848.
50. Schultze-Mosgau S, Schmelzeisen R, Frölich JC, Schmele H. Use of ibuprofen and methylprednisolone for the prevention of pain and swelling after removal of impacted third molars. *J oral maxillofac surg.* 1995;53(1):2-7.
51. Alkholly SS, Abdallah MA, Abdullah AB. Evaluation of Topical Ozone Gel on Postoperative Sequelae Following Impacted Lower Third Molar Surgery. *Al-Azhar Assiut Dent J.* 2019;2(2):125-33.
52. Yousef E, Ateia I, Mansour N, Abdelsameaa S. Impact of Ozone gel, PRF & A-PRF on Pain and Trismus during Tissue Healing after Extraction of Mandibular Third Molars. *Egypt Dent J.* 2021;67(3):2075-89.
53. Bahl D, Samuel S, Charyulu RN, Dole S. Use of topical ozone therapy for wound healing after transalveolar extractions: a miracle alternative therapy. *World Journal of Dentistry.* 2021;13(1):57-61.
54. Varghese G. Management of impacted third molars. *Oral and Maxillofacial Surgery for the Clinician.* 2021:299-328.