

# CONCORDANCE OF THE VESTIBULAR BONE THICKNESS AT THE LEVEL OF POINT A BETWEEN TELERADIOGRAPHY AND CONE BEAM COMPUTED TOMOGRAPHY

Concordancia del espesor óseo vestibular a nivel del Punto A entre Telerradiografía y Tomografía computarizada de haz cónico

Carolina Vergara,<sup>1</sup> Sebastián Espinoza,<sup>2,3</sup> Paulina González,<sup>1</sup> Camila Martens,<sup>1</sup> Patricio Rojas,<sup>1</sup> Pedro Córdova.<sup>1</sup>

1. Faculty of Dentistry, Universidad Andres Bello, Viña del Mar, Chile.

2. Brain Dynamics Laboratory. Universidad de Valparaíso. Chile.

3. Dentistry School, Universidad de Valparaíso. Chile.

## ABSTRACT

**Objective:** The aim of this study was to determine the concordance of the vestibular bone thickness measured at the level of point A between Teleradiography and Cone Beam Computed Tomography (CBCT).

**Materials and Methods:** This study consisted of a cross-sectional analytical design of concordance that evaluated the teleradiographies and CBCTs of 32 patients. The measurements were performed by three evaluators, specialists in orthodontics. Two of them measured the CBCTs and one evaluated the teleradiographs. The concordance of both tests was determined using the Concordance Correlation Coefficient.

**Results:** When evaluating the value of the vestibular bone thickness at the level of point A between the CBCT and the teleradiography, it was observed that the mean value of the absolute difference between the two was 0.9540.74, 95%CI [0.68-1.22], being statistically significant ( $p=0.0027$ ). When the concordance between both tests was analyzed, it was observed that it was poor (CCC=0.204 95%CI [0.014-0.394]), although statistically significant ( $p<0.00001$ ).

**Conclusions:** It was possible to conclude that there is no concordance in the measurement of the vestibular bone thickness at the level of Point A between the Teleradiography and the CBCT.

**Keywords:** *Cone-beam computed tomography; Orthodontics; Cephalometry; Incisor; Patients; Cross-sectional studies*

## RESUMEN

**Objetivo:** El objetivo de este estudio fue determinar la concordancia del espesor óseo vestibular medido a nivel del punto A entre la Telerradiografía y la Tomografía computarizada de haz cónico (CBCT).

**Materiales y Métodos:** Esta investigación presentó un diseño analítico transversal de concordancia en el que se evaluaron las telerradiografías y CBCT de 32 pacientes. Las mediciones fueron realizadas por tres evaluadores especialistas en ortodoncia, dos de ellos midieron los CBCT y uno las telerradiografías. La concordancia de ambos exámenes fue medida mediante Coeficiente de Correlación de Concordancia.

**Resultados:** Al evaluar el valor del grosor óseo vestibular a nivel del punto A entre el CBCT y la telerradiografía, se observó que el valor promedio de diferencia absoluta entre ambos fue de 0,9540,74 IC95% [0,68-1,22], siendo estadísticamente significativas ( $p=0,0027$ ). Cuando se analizó la concordancia entre ambos exámenes se observó que esta fue pobre (CCC=0,204 IC95 % [0,014-0,394]), aunque estadísticamente significativa ( $p<0,00001$ ).

**Conclusión:** Se pudo concluir que no existe concordancia en la medición del espesor óseo vestibular medido a nivel del Punto A entre la Telerradiografía y el CBCT.

**Palabras Clave:** *Tomografía computarizada de haz cónico; Ortodoncia; Cefalometría; Incisivo; Pacientes; Estudios transversales.*

## INTRODUCTION

The diagnosis of craniofacial alterations is essential for planning and developing treatments that allow the prevention, detection, or correction of dento-maxillary anomalies. One of the tools used for this purpose is lateral cephalometry by teleradiography. It is useful for treatment planning, comparison of results, assessment of patient growth, as well as confirmation of compliance with the proposed objectives.<sup>1</sup> Within the cephalometric references, Point A is a widely used skeletal reference point to establish the sagittal and vertical cephalometric position of the upper jaw, in addition to establishing the diagnosis of the skeletal class. This corresponds to the deepest midpoint of the premaxilla, between the Anterior Nasal Spine (ANS) and prosthion<sup>2</sup> generally related to the apex of the maxillary central incisor (MCI).

The evaluation of the position of the central incisors using a lateral cephalogram is done routinely for orthodontic diagnosis. Their inclination and relationship with the surrounding alveolar bone is used for making treatment decisions involving anteroposterior movements of the incisors within the maxillae.<sup>9</sup>

The thickness of the alveolar bone establishes the limits of orthodontic movement. Challenging these limits can cause undesirable side effects in the periodontal tissues<sup>4</sup> and in the dental root, and root resorption can occur when its apical region touches the bone cortex during the movement.<sup>5</sup>

As teleradiography is a two-dimensional radiographic method, it shows some limitations such as image superimposition, distortion, magnification typical of the technique, and difficulty in identifying individual teeth, which makes it impossible to carry out an objective measurement of the area.<sup>6,7</sup> Most orthodontists rely only on cephalograms to assess the alveolar thickness of the maxillary incisors,<sup>8</sup> which can result in diagnostic errors. There are structures such as ANS that, being in the midline, could mask the real amount of bone on the apical portion of the incisor root. Another problem that arises is the actual identification of the root of the incisor to be measured, since adjacent structures, such as the roots of the other incisors, canines, and canine eminence, can mask the contour of this root.<sup>9</sup>

In the field of orthodontics, CBCT is considered an effective diagnostic method to measure initial bone levels and analyze changes that may occur during orthodontic treatment.<sup>6</sup> It provides accurate images of the vestibular and palatal/lingual tables, which are not clearly visible on conventional 2D images.<sup>10</sup> Despite its higher cost and higher level of radiation, CBCT provides comprehensive data and has proven to be suitable for measuring the amount of alveolar bone with a precision of 0.6 mm, as well as detecting the presence of bone dehiscence and fenestrations with excellent accuracy, high sensitivity, and specificity.<sup>11</sup> In this context, it is important to consider that the bone thickness observed by teleradiography, represented by the horizontal distance between the root of the

central incisor and the maxillary cortex, may not be representative of the actual amount of bone existing in this area; however, even so, it is still a routine examination performed by the clinician. The aim of this study was to determine the concordance of the vestibular bone thickness measured at the level of point A between Teleradiography and Cone Beam Computed Tomography (CBCT).

## MATERIALS AND METHODS

This study is based on an analytical, cross-sectional concordance design. It was approved by the Research and Ethics Committee of the School of Dentistry of Universidad Andrés Bello (Approval Code No. 4420). It complies with the Declaration of Helsinki and the data protection of the patients who participated in it.

The studied sample was obtained from an anonymous database of 565 patients from a private orthodontic clinic in Santiago, Chile. Of this, 72 patients who had a lateral teleradiography of the skull and the corresponding CBCT images were selected. Only 32 patients (5.7%) met the inclusion criteria. Sampling was non-probabilistic.

The exams were taken with the same imaging equipment, under a standardized protocol in which all the images obtained showed the patient in maximum intercuspation, with lips at rest and in a natural position of the head.

Imaging exams of lateral teleradiography and CBCT of the upper jaw, taken with a maximum of 2 months apart, without or-

thodontic appliances, were included. Those radiographs that presented upper central incisors with open apex or those where the dental apex was observed under Point A in a sagittal view were excluded. Imaging exams were kept listed anonymously in individual folders.

The Nemoceph™ program (11.3.1) was used to perform the measurements in the lateral teleradiography. The vestibular bone thickness in the lateral teleradiography was obtained by parallelizing the ANS and Posterior Nasal Spine (PNS) points on the same horizontal axis and measuring at point A the distance between the root of the most protruded upper central incisor and the maxillary vestibular cortex (Figure 1).

The PlanMeca Romexis Viewer (4.4.1.R) program was used to measure vestibular bone thickness on the CBCT images. When opening the files, in each one of them the view of the CBCT was restored, and then in the sagittal section, ANS was positioned in the center of the cross of the vertical and horizontal axis. Subsequently, in this same section, the image was rotated so that ANS and PNS were on the same horizontal axis (Figure 2).

Then, in the axial section, ANS was also positioned in the center of the cross of the vertical and horizontal axis, making sure that ANS coincided with PNS now on the vertical axis. Returning to the sagittal section, the center of the cross was located at point A, defined in the study as the deepest point of the maxillary cortex between ANS and Prosthion (Figure 3).

In the axial section, the center of the cross was positioned in the center of tooth 1.1 (Figure 4) and then in the sagittal section, the bone thickness was measured between the vestibular face of the incisor root and the vestibular cortex on the horizontal axis. (Figure 5).

Subsequently, the measurements were taken in tooth 2.1, positioning the center of the cross in the center of tooth 2.1 in the axial section, to then measure the bone thickness between the vestibular face of the root of the incisor and the vestibular cortex in the sagittal section on the horizontal axis.

Measurements were performed by three evaluators specialized in orthodontics. Two of them performed the CBCT measurements, each one independently. The measurement of the teleradiography was carried out by a specialist in orthodontics with proven experience in the field. The two evaluators responsible for measuring the CBCTs were previously calibrated by performing the evaluation of 15 CBCT images.

### Statistic analysis

In the analysis of the results, descriptive measures of central tendency and dispersion were used for the quantitative variables, while proportions were calculated for the qualitative ones. For all cases, 95% confidence intervals were obtained using normal approximation. The difference between the mean vestibular bone thickness obtained by CBCT for tooth 1.1 and tooth 2.1, and the difference between the mean vestibular bone thickness for teeth 1.1 and 2.1, measured by teleradiography and CBCT, was evaluated using the Wilcoxon rank test.

The Proportions Test was used to measure the difference between the distribution of representative teeth on the CBCT. To analyze the concordance between the imaging tests, the concordance correlation coefficient was calculated, the product of the Pearson correlation and the bias correction factor.

All results with *p*-values lower than 0.05 were considered significant and were calculated using the STATA 16.1 software.

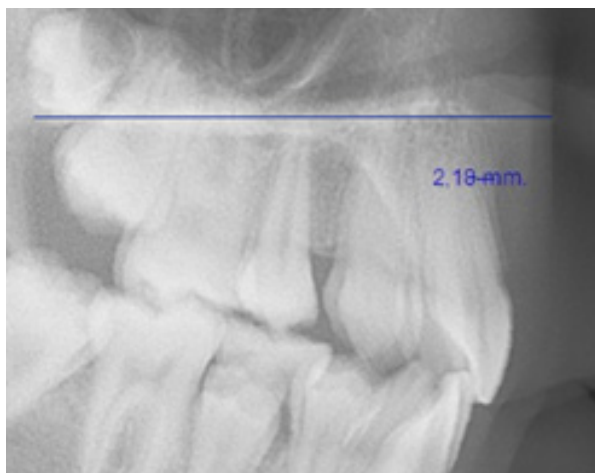
## RESULTS

The results obtained in the calibration were evaluated and compared statistically, finding a CCC=0.87 (*p*-value<0.0001, 95%CI [0.79-0.96]). Table 1 describes the results obtained by measuring the vestibular bone thickness at the level of point A in lateral teleradiography and CBCT.

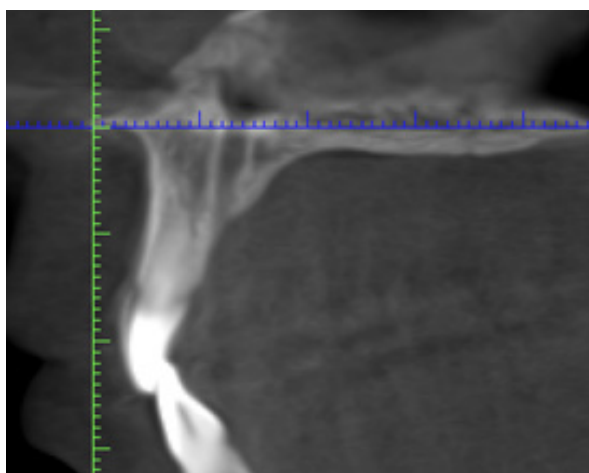
The mean vestibular bone thickness obtained by CBCT for the upper right central incisor, tooth 1.1, was 1.18 ± 0.49, 95%CI [1 - 1.36], while for the upper left central incisor, tooth 2.1, was 1.22 ± 0.49, 95%CI [1.03 - 1.4], without presenting statistically significant differences between the groups (*p*-value=0.97) (Table 2).

On the other hand, the mean obtained when analyzing the teleradiography was 2.1340.99, 95%CI [1.77 - 2.5]. Now, when the comparison is made between the representative value of CBCT (the highest value of the patient) with that obtained in the teleradiography, it is observed that the

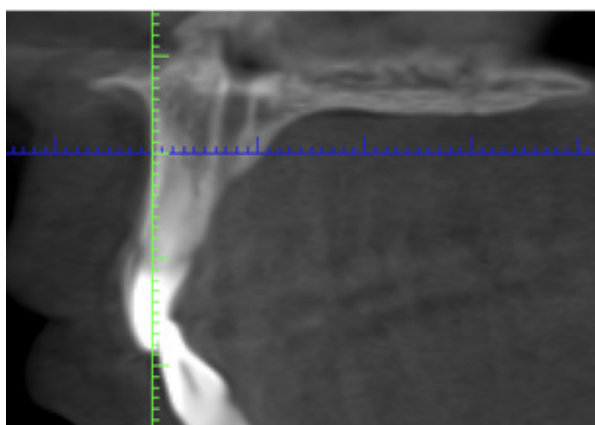
**Figure 1:** Measurement of vestibular bone thickness in lateral teleradiography parallel to the axis formed between points ANS and PNS at the level of Point A.



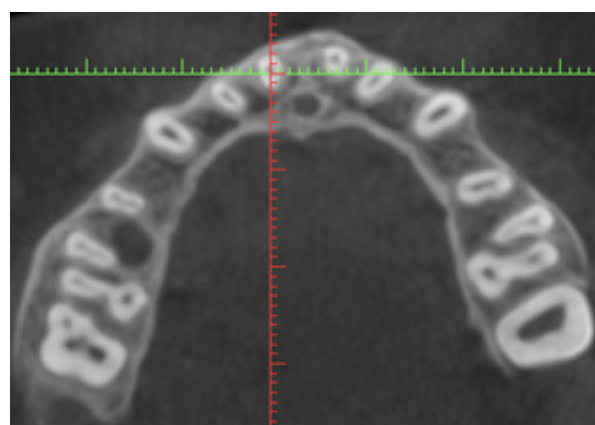
**Figure 2:** Bispinal plane (from ANS to PNS) parallelized in sagittal section on CBCT.



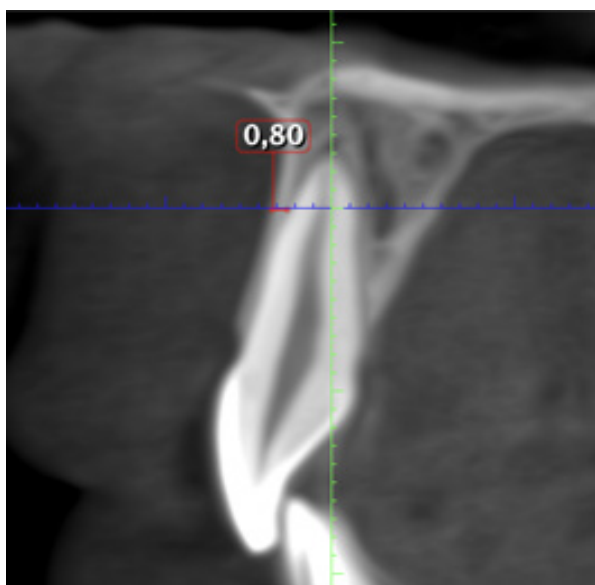
**Figure 3:** Location of Point A in the sagittal plane on CBCT.



**Figure 4:** Axial section showing the center of the central incisor 1.1 on CBCT.



**Figure 5:** Measurement of vestibular bone thickness at the level of Point A, measured in a sagittal section on CBCT.



**Table 1:** Measurement in millimeters of the vestibular bone thickness established by cone-beam computed tomography (CBCT) image in teeth 1.1 and 2.1 and by lateral teleradiography in the most protruded incisor.

Patient	Teleradiography Most protruding central incisor	CBCT Tooth 1.1	CBCT Tooth 2.1
1	4.82	1.00	0.80
2	2.18	1.00	1.60
3	1.89	0.80	1.40
4	1.53	1.20	1.20
5	2.91	1.00	2.20
6	1.94	1.00	1.20
7	2.25	2.80	2.40
8	3.18	1.40	0.80
9	3.83	1.80	0.80
10	3.71	2.00	2.00
11	2.10	< 0.80	1.00
12	0.86	< 0.80	0.80
13	1.36	< 0.80	< 0.80
14	2.28	1.40	0.80
15	2.93	1.02	1.40
16	1.10	< 0.80	< 0.80
17	2.53	2.00	2.40
18	1.48	< 0.80	1.20
19	1.60	< 0.80	< 0.80
20	1.83	1.00	0.80
21	1.84	1.20	0.80
22	2.40	1.00	1.00
23	1.08	1.60	1.40
24	1.87	1.20	0.80
25	0.51	0.80	1.60
26	1.47	< 0.80	< 0.80
27	2.26	< 0.80	< 0.80
28	3.22	1.40	1.20
29	0.28	0.80	0.80
30	2.00	< 0.80	1.40
31	3.41	1.60	1.20
32	2.71	1.80	1.60



**Table 2:** Detail of the statistical analyses carried out on the sample.

<b>Comparison of vestibular bone thickness measured on CBCT</b>						
	<b>Mean</b>	<b>SD</b>	<b>Median</b>	<b>95%CI</b>		<b>p-value</b>
CBCT 1.1	1.18	0.48	100	1.01	0.36	0.97
CBCT 2.1	1.20	0.49	1.10	1.02	1.38	
<b>Comparison and absolute difference between CBCT and teleradiography</b>						
	<b>Mean</b>	<b>SD</b>	<b>Median</b>	<b>95%CI</b>		<b>p-value</b>
CBCT	1.35	0.51	1.20	1.35	1.54	<0.00001
Teleradiography	2.13	0.99	200	1.77	2.49	
Diff (ABS)	0.95	0.74	0.71	0.68	1.23	<0.00001
<b>Comparison between teeth 1.1 and 2.1 on CBCT</b>						
	<b>fr</b>	<b>%</b>	<b>Diff</b>	<b>95%CI</b>		<b>p-value</b>
Tooth 1.1	11.00	35.48	-0.29	0.07	0.63	0.0602
Tooth 2.1	20.00	64.52		0.43	0.85	
<b>Concordance Correlation Coefficient (CCC)* measurement</b>						
<b>CCC</b>	<b>EE</b>	<b>95%CI</b>	<b>R Pearson</b>	<b>bias-correction factor</b>		<b>p-value</b>
0.204	0.097	0.014	0.394	0.378	0.539	0.036

\***CCC:** is the product between the Pearson correlation (precision of the data) and the bias correction factor (accuracy)

mean value of the absolute difference between the two is 0.9540.74, 95%CI [0.68 - 1.22], these differences are statistically significant ( $p$ -value=0.0027) (Table 2).

However, to know the distribution of representative teeth on the CBCT, in most samples it was obtained in 2.1 with 64.52% (n=20), while in 1.1 this percentage was 35.48% (n=11). There were no statistically significant differences ( $p$ -value=0.0602) (Table 2).

Finally, when the concordance, resulting between the Pearson correlation and the bias correction factor, is analyzed, it is observed that it is poor between the techniques (CCC=0.204, 95%CI [0.014 - 0.394]), with a statistically significant difference ( $p$ -value<0.00001) (Table 2).

## DISCUSSION

One of the factors that affect the longevity of a tooth is its periodontal health. Evidence shows that orthodontic treatment can result in loss of periodontal support in the presence of plaque and inflammation.<sup>12</sup>

Strong tilting movements in the vestibule-palatal or vestibule-lingual direction are considered a risk factor for dehiscence and fenestrations,<sup>13</sup> which can be explained by the thin thickness of the alveolar bone surrounding the roots.<sup>14,15</sup>

In this context, it is essential to carry out a thorough diagnosis of each patient, before starting orthodontic treatment and planning dental movements, always considering

the preservation of periodontal health. For orthodontists to accurately plan treatments and ensure positive results, a complete and accurate assessment of the alveolar bone thickness of the maxillary incisor is very important.<sup>8</sup>

Lateral teleradiography is a common method for the evaluation and planning of orthodontic treatments. It used to estimate the amount of vestibular alveolar bone in the incisor area. Some authors suggest that this test does not have adequate scientific support, reporting a lack of evidence on its validity and reliability.<sup>15,16</sup>

In orthodontics, CBCT images have overcome the limitations of 2D imaging by allowing accurate description of the craniofacial anatomy and providing comprehensive data on anatomical relationships and individual patient findings, without overlap or distortion.<sup>17</sup> Regarding its accuracy in measuring alveolar bone thickness or height, current evidence suggests that there are no significant differences between CBCT and direct measurement of human skulls or living patients, which correspond to the Gold Standard.<sup>18</sup>

In the present study, the concordance of the measurement of vestibular bone thickness at the level of Point A between lateral teleradiography and CBCT was evaluated. When studying the selected sample, it was found that there were no statistically significant differences in the mean vestibular bone thickness, measured by CBCT, between teeth 1.1 and 2.1. On the contrary, when evaluating the concordance of these values with the teleradiography sample, a statistically

significant difference was found between both tests. This is how the concordance correlation coefficient (CCC=0.204) gave a statistically significant difference, when comparing both exams.

Similar results were found by Kula *et al.*,<sup>9</sup> who reported that when 2D cephalograms extracted from CBCT images are compared with 3D images, the thickness of the alveolar bone that covers the roots of the maxillary central incisors is overestimated in the cephalograms, compared to CBCT images, which could be due to the presence of ANS, which could mask the vestibular bone and dental apices. On the other hand, Wei *et al.* determined that the alveolar bone thickness of the maxillary incisor is always overestimated in cephalograms compared to CBCT-based measurements.

This overestimation ranges from 0.3 to 1.3 mm. Cephalometric measurement bias increases when measurement lines move apically, therefore CBCT should be recommended when accurate assessment of alveolar bone thickness is required.<sup>8</sup>

The literature describes that, in general, the anterior bone thickness of the maxilla, measured by CBCT, is less than or equal to 1 mm,<sup>11,14,19-21</sup> which is consistent with the results found in this study. However, Fuentes *et al.* evaluated the vestibular alveolar bone of the maxillary incisors, finding that <10% of the sites showed that the vestibular bone wall was more than 2 mm thick.<sup>22</sup>

A systematic review and a meta-analysis carried out in 2020 suggests that few maxi-



llary teeth have a vestibular bone thickness greater than 2 mm, and this measurement can be found in maxillary incisors at the apical level. Most of the studies that reported a thickness of more than 2 mm were conducted in the Asian population.<sup>23</sup>

Point A corresponds to a cephalometric reference point located in an area of maxillary bone subjected to fewer dimensional changes caused by bone remodeling processes compared to those observed in other areas of alveolar bone such as the bone crest.<sup>14,24</sup> Despite this, it corresponds to a point that is difficult to identify in 2 dimensions due to the overlapping of images and the positioning of the head.<sup>9</sup>

Deguchi *et al.*,<sup>25</sup> measured the bone thickness at the level of Point A by CBCT, finding a value of 1.4 ± 0.5 mm, a value that is similar to those found in this study. However, no evidence was found that they measured the vestibular bone thickness of maxillary central incisors by lateral

teleradiography at the level of point A, nor was there scientific evidence to directly compare the concordance between both tests when analyzing these variables at this point, even though numerous studies suggest that images obtained with CBCT are more accurate than those obtained with lateral teleradiography.<sup>26,27</sup>

Even though the sample of this study was small, it presented great homogeneity, so the results are significant. It is suggested to carry out the same study following this standardized methodology with a larger multicenter sample.

## CONCLUSION

In this study, no concordance was found when evaluating the vestibular bone thickness measured at the level of point A between Teleradiography and Cone Beam Computed Tomography (CBCT).

## CONFLICT OF INTERESTS

The authors declare no conflict of interest.

## ETHICS APPROVAL

Study was approved by the Research and Ethics Committee of the Faculty of Dentistry, Andrés Bello University, (No.4420).

## FUNDING

None.

## AUTHORS' CONTRIBUTIONS

**Vergara C:** Validation - data curation- visualization- methodology - writing - original draft - writing - review and editing

**Espinoza S:** Data curation - formal análisis - software - validation

**González P:** Methodology- investigation - data curation

**Martens C:** Methodology- investigation - data curation

**Rojas P:** Supervisión- writing - review and editing

**Córdova P:** Conceptualization - supervisión- writing - review and editing

## ACKNOWLEDGEMENTS

We thank Dr. Kiyoko Suzuki Barrera for her contribution and her critical comments to this manuscript.

## ORCID

Carolina Vergara

 0000-0002-1218-3954


Sebastián Espinoza

 0000-0001-9678-2665

Paulina González

 0000-0002-8232-7757


Camila Martens

 0000-0003-3835-1861

Patricio Rojas

 0000-0002-4681-2624

Pedro Córdova

 0000-0001-5032-5362

## PUBLISHER'S NOTE

All statements expressed in this article are those of the authors alone and do not necessarily represent those of the publisher, editors, and reviewers.

## COPYRIGHT

This is an open-access article distributed under the terms of the [Creative Commons Attribution License \(CC BY 4.0\)](https://creativecommons.org/licenses/by/4.0/). The use, distribution or reproduction in other forums is permitted, provided the original author(s) and the copyright owner(s) are credited and that the original publication in this journal is cited, in accordance with accepted academic practice. No use, distribution or reproduction is permitted which does not comply with these terms. © 2023.



## PEER REVIEW

This manuscript was evaluated by the editors of the journal and reviewed by at least two peers in a double-blind process.

## PLAGIARISM SOFTWARE

This manuscript was analyzed by Turnitin's Original plagiarism detector software. Analysis report of document (ID fe87f8051fc72d).

ISSN Print 0719-2460 - ISSN Online 0719-2479.

<https://www.joralres.com/index.php/JOralRes/issue/archive>

## REFERENCES.

1. Sandoval P, García N, Sanhueza A, Romero A, Reveco R. Medidas cefalométricas en telerradiografías de perfil de pre-escolares de 5 años de la ciudad de Temuco. *Int J Morphol.* 2011;29(4):1235-40.
2. Downs WB. Variations in facial relationships; their significance in treatment and prognosis. *Am J Orthod.* 1948;34(10):812-40. [https://doi.org/10.1016/0002-9416\(48\)90015-3](https://doi.org/10.1016/0002-9416(48)90015-3). PMID: 18882558.
3. Andrews WA, Abdulrazzaq WS, Hunt JE, Mendes LM, Hallman LA. Incisor position and alveolar bone thickness. *Angle Orthod.* 2022;92(1):3-10. <https://doi.org/10.2319/022320-122.1>. PMID: 34383019; PMCID: PMC8691463.
4. Garib DG, Yatabe MS, Ozawa TO, da Silva Filho OG. Alveolar bone morphology under the perspective of the computed tomography: Defining the biological limits of tooth movement. *Dental Press J Orthod.* 2010;15(5):192-205.
5. Zhang X, Gao J, Sun W, Zhang H, Qin W, Jin Z. Evaluation of alveolar bone morphology of incisors with different sagittal skeletal facial types by cone beam computed tomography: A retrospective study. *Heliyon.* 2023;9(4):e15369. <https://doi.org/10.1016/j.heliyon.2023.e15369>. PMID: 37113777; PMCID: PMC10126934.
6. Picanço PR, Valarelli FP, Cançado RH, de Freitas KM, Picanço GV. Comparison of the changes of alveolar bone thickness in maxillary incisor area in extraction and non-extraction cases: computerized tomography evaluation. *Dental Press J Orthod.* 2013;18(5):91-8. <https://doi.org/10.1590/s217694512013000500016>. PMID: 24352394.
7. Tong H, Enciso R, Van Elslande D, Major PW, Sameshima GT. A new method to measure mesiodistal angulation and faciolingual inclination of each whole tooth with volumetric cone-beam computed tomography images. *Am J Orthod Dentofacial Orthop.* 2012;142(1):133-43. <https://doi.org/10.1016/j.ajodo.2011.12.027>. PMID: 22748999.
8. Wei D, Zhang L, Li W, Jia Y. Quantitative Comparison of Cephalogram and Cone-Beam Computed Tomography in the Evaluation of Alveolar Bone Thickness of Maxillary Incisors. *Turk J Orthod.* 2020;33(2):85-91. <https://doi.org/10.5152/TurkJOrthod.2020.19097>. PMID: 32637188; PMCID: PMC7316481.
9. Kula TJ 3rd, Ghoneima A, Eckert G, Parks ET, Utreja A, Kula K. Two-dimensional vs 3-dimensional comparison of alveolar bone over maxillary incisors with A-point as a reference. *Am J Orthod Dentofacial Orthop.* 2017;152(6):836-847.e2. <https://doi.org/10.1016/j.ajodo.2017.05.030>. PMID: 29173863.
10. Carmo De Menezes C, Janson G, Da C, Massaro S, Cambiaghi L, Garib DG. Reproducibility of bone plate thickness measurements with Cone-Beam Computed Tomography using different image acquisition protocols. *Dental Press J Orthod.* 2010;15(5):143-9.
11. García-Sanz V, Bellot-Arcis C, Montiel J, Paredes V, Gandia JL. Relación entre la posición de incisivos y el hueso alveolar. *Rev Esp de Ortod.* 2015;45(3):129-135.
12. Bollen AM, Cunha-Cruz J, Bakko DW, Huang GJ, Hujuel PP. The effects of orthodontic therapy on periodontal health: a systematic review of controlled evidence. *J Am Dent Assoc.* 2008;139(4):413-22. <https://doi.org/10.14219/jada.archive.2008.0184>. PMID: 18385025.
13. Sendyk M, Linhares DS, Pannuti CM, Paiva JB, Rino Neto J. Effect of orthodontic treatment on alveolar bone thickness in adults: a systematic review. *Dental Press J Orthod.* 2019;24(4):34-45. <https://doi.org/10.1590/21776709.24.4.034-045.oar>. PMID: 31508705; PMCID: PMC6733232.
14. Bonta H, Carranza N, Gualtieri AF, Rojas MA. Morphological characteristics of the facial bone wall related to the tooth position in the alveolar crest in the maxillary anterior. *Acta Odontol Latinoam.* 2017;30(2):49-56. PMID: 29248938.
15. Devereux L, Moles D, Cunningham SJ, McKnight M. How important are lateral cephalometric radiographs in orthodontic treatment planning? *Am J Orthod Dentofacial Orthop.* 2011;139(2):e175-81. <https://doi.org/10.1016/j.ajodo.2010.09.021>. PMID: 21300228.
16. Durão AR, Pittayapat P, Rockenbach MI, Olszewski R, Ng S, Ferreira AP, Jacobs R. Validity of 2D lateral cephalometry in orthodontics: a systematic review. *Prog Orthod.* 2013;14(1):31. <https://doi.org/10.1186/2196-1042-14-31>. PMID: 24325757; PMCID: PMC3882109.
17. Mah JK, Huang JC, Choo H. Practical applications of cone-beam computed tomography in orthodontics. *J Am Dent Assoc.* 2010;141 Suppl 3:7S-13S. <https://doi.org/10.14219/jada.archive.2010.0361>.
18. Li Y, Deng S, Mei L, Li J, Qi M, Su S, Li Y, Zheng W. Accuracy of alveolar bone height and thickness measurements in cone beam computed tomography: a systematic review and meta-analysis. *Oral Surg Oral Med Oral Pathol Oral Radiol.* 2019;128(6):667-679. <https://doi.org/10.1016/j.oool.2019.05.010> Epub 2019 May 24. PMID: 31311766.
19. El Nahass H, N Naiem S. Analysis of the dimensions of the labial bone wall in the anterior maxilla: a cone-beam computed tomography study. *Clin Oral Implants Res.* 2015;26(4):e57-e61. <https://doi.org/10.1111/clr.12332>. Epub 2014 Jan 23. PMID: 24450845.

20. Lee SL, Kim HJ, Son MK, Chung CH. Anthropometric analysis of maxillary anterior buccal bone of Korean adults using cone-beam CT. *J Adv Prosthodont.* 2010;2(3):92-6. <https://doi.org/10.4047/jap.2010.2.3.92>. Epub 2010 Sep 30. PMID: 21165276; PMCID: PMC2994701.
21. Rojo-Sanchis J, Soto-Peñaloza D, Peñarrocha-Oltra D, Peñarrocha-Diago M, Viña-Almunia J. Facial alveolar bone thickness and modifying factors of anterior maxillary teeth: a systematic review and meta-analysis of cone-beam computed tomography studies. *BMC Oral Health.* 2021;21(1):143. <https://doi.org/10.1186/s12903-021-01495-2>. PMID: 33752651; PMCID: PMC7986564.
22. Fuentes R, Flores T, Navarro P, Salamanca C, Beltrán V, Borie E. Assessment of buccal bone thickness of aesthetic maxillary region: a cone-beam computed tomography study. *J Periodontal Implant Sci.* 2015; 45(5):162-8. <https://doi.org/10.5051/jpis.2015.45.5.162>. Epub 2015 Oct 26. PMID: 26550524; PMCID: PMC4635437.
23. Tsigarida A, Toscano J, de Brito Bezerra B, Geminiani A, Barmak AB, Caton J, Papaspyridakos P, Chochlidakis K. Buccal bone thickness of maxillary anterior teeth: A systematic review and meta-analysis. *J Clin Periodontol.* 2020;47(11):1326-1343. <https://doi.org/10.1111/jcpe.13347>. Epub 2020 Sep 16. PMID: 32691437.
24. Ghassemian M, Nowzari H, Lajolo C, Verdugo F, Pirronti T, D'Addona A. The thickness of facial alveolar bone overlying healthy maxillary anterior teeth. *J Periodontol.* 2012;83(2):187-97. <https://doi.org/10.1902/jop.2011.110172>. Epub 2011 Jun 21. PMID: 21692627.
25. Deguchi T, Nasu M, Murakami K, Yabuuchi T, Kamioka H, Takano-Yamamoto T. Quantitative evaluation of cortical bone thickness with computed tomographic scanning for orthodontic implants. *Am J Orthod Dentofacial Orthop.* 2006;129(6):721.e7-12. <https://doi.org/10.1016/j.ajodo.2006.02.026>. PMID: 16769488.
26. Pittayapat P, Bornstein MM, Imada TS, Coucke W, Lambrechts I, Jacobs R. Accuracy of linear measurements using three imaging modalities: two lateral cephalograms and one 3D model from CBCT data. *Eur J Orthod.* 2015;37(2):202-8. <https://doi.org/10.1093/ejo/cju036>. Epub 2014 Aug 26. PMID: 25161199.
27. Teerakanok S, Charoemratrote C, Chanmanee P. The Accuracy of Lateral Cephalogram in Representing the Anterior Maxillary Dentoalveolar Position. *Diagnostics.* 2022;12(8):1840. <https://doi.org/10.3390/diagnostics12081840>. PMID: 36010191; PMCID: PMC9406342.