

NON-SURGICAL RAPID MAXILLARY EXPANSION WITH MINI-IMPLANTS IN ADULTS: A NARRATIVE REVIEW.

Expansión rápida maxilar no quirúrgica con
miniimplantes en adultos: Una revisión narrativa

Alina K. Cardozo.¹
Marcos J. Carruitero.^{1,2}

AFFILIATIONS:

¹Universidad Católica Santo Toribio de
Mogrovejo, Chiclayo, Perú.

²Universidad Privada Antenor Orrego,
Trujillo, Perú.

CORRESPONDING AUTHOR:

Marcos J. Carruitero. Antenor Orrego
Private University. Av. América Sur
#3145 Monserrate. Trujillo. Perú. **E-mail:**
mcarruitero@usat.edu.pe.com

CITE AS:

Cardozo AK & Carruitero MJ.

Non-surgical rapid maxillary expansion
with mini-implants in adults: A narrative
review.

J Oral Res.2022;11(6):1-14

doi:10.17126/joralres.2022.064

ABSTRACT:

Introduction: In recent years, rapid maxillary expansion (RME) in prepubertal growth stages has been deeply investigated; however, its study has recently been increasing in adults without need for surgery. The objective of this review is to present the results reported in the scientific literature about RME in adults.

Material and Methods: Six databases were used to carry out the secondary search of the review. The search was performed virtually and studies from the last six years were considered, with a last search performed until November, 2022.

Results: A total of 253 studies were found, from which 20 studies were finally selected. RME in adults can result in substantial expansion similar to that obtained in patients who have not yet completed the ossification of the mid-palatal suture.

Conclusion: The reviewed scientific literature shows evidence that there are various devices supported by mini-implants as non-surgical treatment options to correct transverse deficiency and help expand the maxilla in adult patients.

KEYWORDS:

Palatal expansion technique; Adult; Malocclusion; mini-implants; Maxilla; Review

RESUMEN:

Introducción: En los últimos años se ha investigado profundamente la expansión maxilar rápida (ERM) en etapas de crecimiento prepuberal; sin embargo, recientemente se ha ido incrementando su estudio en adultos sin necesidad de cirugía. El objetivo de esta revisión es presentar los resultados reportados en la literatura científica sobre ERM en adultos.

Material y Métodos: Se utilizaron seis bases de datos para realizar la búsqueda secundaria de la revisión. La búsqueda se realizó de manera virtual y se consideraron estudios de los últimos seis años, con una última búsqueda realizada hasta noviembre de 2022.

Resultados: Se encontraron un total de 253 estudios, de los cuales finalmente se seleccionaron 20 estudios. La ERM en adultos puede dar como resultado una expansión sustancial similar a la obtenida en pacientes que aún no han completado la osificación de la sutura palatina media.

Conclusión: La literatura científica revisada muestra evidencia que existen diversos dispositivos apoyados en mini-implantes como opciones de tratamiento no quirúrgico para corregir la deficiencia transversal y ayudar a generar disyunción maxilar en pacientes adultos.

PALABRAS CLAVE:

Técnica de expansión palatina; Adulto; Maloclusión; Mini-implantes; Maxilar; Revisión.

INTRODUCTION.

A prevalence of posterior crossbite between 8.5% and 10.3%¹ has been reported and 30% of adults who seek for treatment of dentofacial deformity have a component of transverse maxillary deficiency.² This is one of the most detrimental problems for facial growth and the integrity of the dentoalveolar structures. Maxillary constriction can cause various problems, such as poor aesthetics, occlusal disharmony, narrowing of the pharyngeal airways, nasal and breathing resistance increased, generating mouth breathing, alteration of the tongue position, and obstructive sleep apnea.³

Rapid maxillary expansion (RME) is considered a gold standard treatment in transverse maxillary deficiencies, which consists of increasing the transverse dimension of the maxilla using different types of devices that achieve considerable maxillary expansion, separating the palatal suture,⁴ also affecting the circummaxillary sutures laterally,⁵ thanks to the application of heavy forces.⁶ Traditionally RME has been able to be performed in prepubertal stages; however, evidence has recently emerged of opening the maxillary suture in post-adolescent stages.⁷ and even more in the adult stage,⁸ in which it would be very useful, considering that this approach has been conventionally performed by surgery only.³ For this reason, it is necessary to synthesize all the current information about this therapeutic procedure in adulthood. The objective of this narrative review is to present the results reported in the scientific literature about RME with skeletal anchorage in adults.

MATERIALS AND METHODS.

Six databases were used to carry out the secondary search of the review: PubMed, Scopus, Web of Science, ScienceDirect, SciELO, and BVS, whose search strategies are shown in Table 1. The primary manual search sources were: *The American Journal of Orthodontics and Dentofacial Orthopedics*, *The Angle Orthodontist*, *European Journal of Orthodontics*, and *The Korean Journal of Orthodontics*. For searching in these journals, the MeSH terms used were: "palatal

expansion", "maxillary expansion", *child**, and *adult**; also, the non-MeSH terms: *miniscrew**, *microscrew**, *miniimplant**, "transverse maxillary deficiency", and "maxillary expander"; as well as the DeCS terms: "expansión palatina", "expansión maxilar", and "expansión rápida maxilar". The Boolean operators used were AND and OR. All searches were run without language filtering. The search was performed virtually and studies from the last six years were considered, with a first search performed until June 06, 2021 and an update on November 10, 2022. The included studies were systematic reviews, meta-analyses, clinical trials, observational studies, and case reports. Letters to the editor, narrative reviews, opinion pieces, books, and newsletters were excluded.

RESULTS.

A total of 253 studies were found. After eliminating duplicate studies, 121 were selected, of which nine were from *PubMed*, 35 from *Scopus*, 26 from *Web of Science*, 42 from *ScienceDirect*, three from *SciELO*, and six from *BVS*.

These studies were reviewed individually to determine their inclusion in the present study, leaving 12 studies for the qualitative synthesis. After an update carried out in November 2022, eight more studies were incorporated for the qualitative analysis, leaving finally 20 studies (Figure 1).

1. GENERAL CONSIDERATIONS OF RME

1.1 Definition

RME It is an orthopedic procedure that is used in various clinical situations.⁹ It could be the best option for patients with bilateral crossbites, even if it is widely used for the correction of asymmetries or other types of malocclusions such as posterior unilateral crossbites and for class II malocclusions with maxillary atresia.⁶

Transverse balanced relationship between the maxillary and mandibular dentition is a prerequisite for searching an ideal occlusion¹⁰ regardless of the age of the patient. In particular, considering the

high prevalence among adults, transverse maxillary deficiency does not seem to be adequately diagnosed and treated, possibly due to the lack of adequate diagnostic and treatment measures. The transverse dimension perspective is helpful for clinicians to understand the pattern and severity of transverse discrepancy and to decide on a non-surgical maxillary expansion.¹¹

The mid-palate suture has bony margins with thick connective tissue interposed, and does not represent fusion of maxillary palatine processes only, but also fusion of maxillary palatine processes and the horizontal bony plates of palatine bones. Changing it involves affecting neighboring areas; therefore, it presents three segments that should be considered for both analysis and therapeutic or experimental procedures: the anterior segment (before the incisive foramen, or intermaxillary segment), the median segment (from the incisive foramen to the transverse suture to the palatine bone), and the posterior segment (after suture transverse to the palatine bone).¹¹

1.2 Conventional maxillary expansion in children and adults

Traditionally, in children, the maxilla can be expanded daily by 0.4mm to 0.8mm in the direction of the suture using tooth-anchored intraoral appliances. The rapid maxillary expansion protocol can produce different effects on the palatal suture, periodontium, and alveolar anatomy, such as lateral flexion of the alveolar processes, root resorption, bone fenestration, and anchoring teeth may show different degrees of inclination and displacement. In order to reduce these side effects, it has been proposed maxillary expansion devices anchored by mini-implants.¹²

In adults, the mid-palatal suture of the maxilla has considered merged; therefore, in most cases, even before the use of mini-implants, a surgical procedure has been required to aid maxillary expansion.¹³ Angelieri *et al.*,¹⁴ in 2013, proposed a classification method with the potential to avoid the side effects of failed rapid maxillary expansion or unnecessary

surgically assisted rapid maxillary expansion for late adolescents and young adults. However, the application of such a method should be taken with caution by clinicians, since mild to poor inter-examiner agreement has recently been reported.¹⁵

1.3 Indications for RME in adults

RME may be recommended for patients in the final stage of pubertal growth, as well as adult patients with maxillary constriction, as a prior consideration in treatment that can potentially avoid maxillary expansion surgery.¹¹

Correction of transverse discrepancies in skeletally mature patients can considerably reduce dento-alveolar side effects. It should be considered as an alternative to control the length of the arch perimeter, especially in orthodontic treatment with limitations in adults, especially when the incisors present considerable underlying crowding, periodontal problems or restrictions related to the profile of the soft tissues.¹⁶

Transverse discrepancy is very common among adult orthodontic patients, even in the absence of obvious posterior crossbite. For this reason, it is recommended to cautiously recognize the transverse discrepancy from the perspectives of the center of resistance, in order to better deal with challenging problems such as severe crowding, posterior crossbite, facial asymmetry, among others.^{8,11} Likewise, it is important to consider in the RME protocol, the expansion force directly anchored to the bony structures of the palatal and nasal cortical bone through the use of mini-implants.¹⁷

1.4 Diagnostic methodology to decide the use of a maxillary expander in adults

Ideally, in addition to clinical evaluation, the use of tomographic images is suggested to identify transverse skeletal discrepancy prior to performing RME either for pre-RME diagnosis, pre-surgery, and as post-treatment records.¹⁸ The characteristics of the mid-palatal suture can be evaluated by means of the axial palatal section of the tomography.⁸

The difficulty in diagnosing the precise moment

Figure 1. Flowchart for the selection of articles.

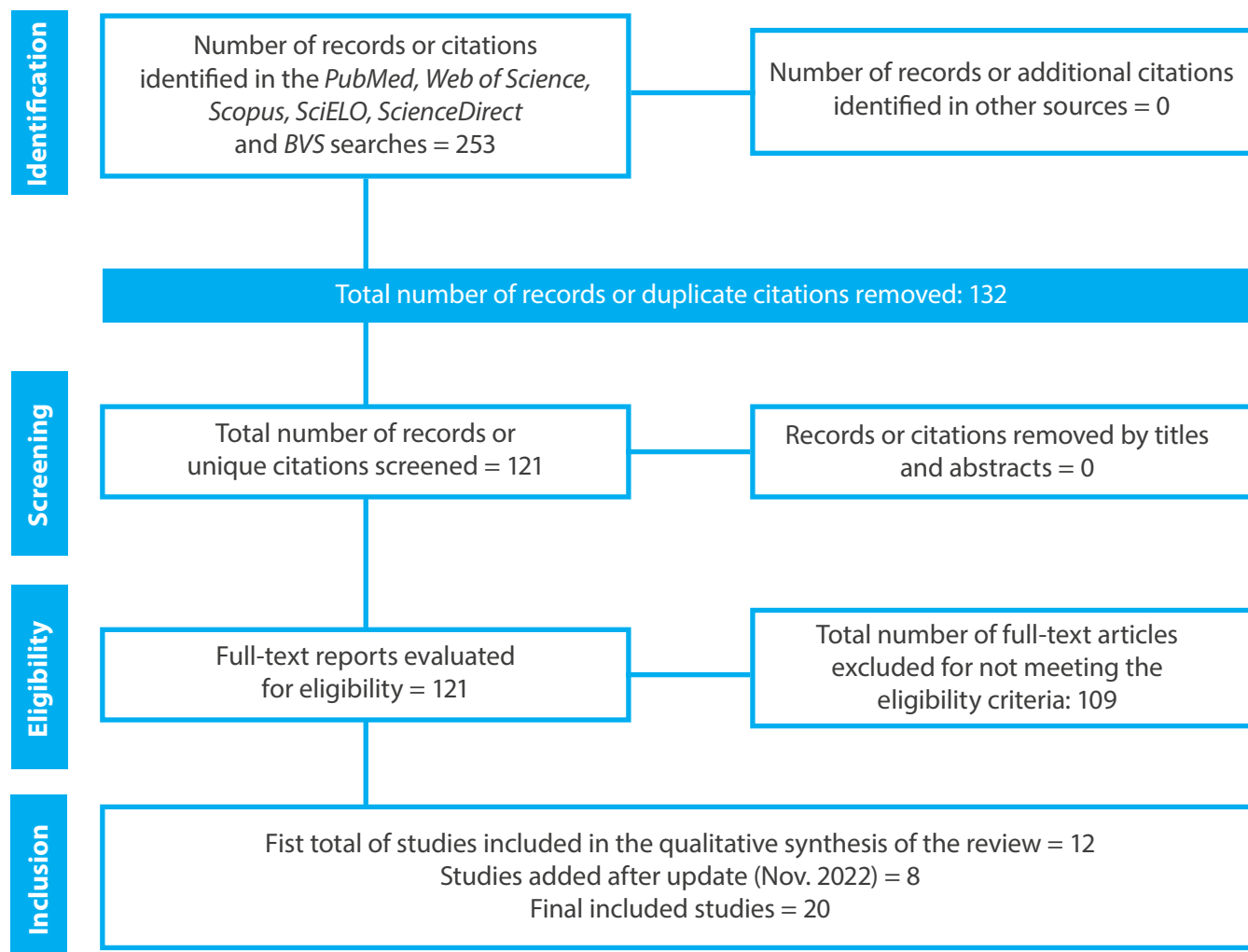


Table 1. Search strategies used in the consulted databases.

Database	Search expression
PubMed, Web of Science, Scopus, SciELO	("palatal expansion" OR "maxillary expander" OR "maxillary expansion" OR "transverse maxillary deficiency") AND (child* OR adult*) AND (miniscrew* OR microscrew* OR miniimplant*)
ScienceDirect	("palatal expansion" OR "maxillary expander" OR "maxillary expansion" OR "transverse maxillary deficiency") AND (child\$ OR adult\$) AND (miniscrew\$ OR microscrew\$ OR miniimplant\$)
BVS	("expansión palatina" OR "expansión maxilar" OR "expansión rápida maxilar") AND (niño OR adulto*) AND (minitornillo* OR microtornillo* OR miniimplante*)

Table 2. Devices and protocols used to generate rapid maxillary expansion in adults.

Method	Author the device	Origin of participants	Age of the participants	Amount of mini-implants	Description of protocol	Activation
MSE (Maxillary skeletal expander, type of MARPE)	Cantarella et al. ¹⁷ (2018)	Biomaterials (Korea, Seoul, Korea).	17.2 ± 4.2 years; range, 13.9-26.2 years	15	Four mini-implants at the rear of the palate with bicortical involvement. The diameter of the mini-implants was 1.5 mm	The expansion rate was 2 turns per day (0.25 mm per turn).
MARPE (Rapid palatal expansion assisted by mini-implants)	Calil et al. ²³ (2020)	PecLab (Belo Horizonte, Minas Gerais, Brazil).	24.92 ± 7.60 years	18	Quantity: 4 mini-implants: 1.8 mm in diameter and 8 mm in length	2/4 turns a day
MARPE (Rapid palatal expansion assisted by mini-implants)	Choi et al. ³¹ (2021)	KBE, Biomaterials (Korea, Seoul, Korea).	24 years	1	1.8 mm mini-implant, length 9.0 mm in the wrinkle area and 7.0mm in the mid-sagittal	1 turn / day with a quarter turn (0.2 mm/ turn). The x MARPE apparatus was maintained for 4 months.
MARPE (Rapid palatal expansion assisted by mini-implants)	Seong et al. ²⁸ (2018)	Nissin Dental Products (Kyoto, Japan).	20 years	1	Four mini-implants (2.0 mm diameter, 7 mm length).	Multiple laps.
MARPE (Rapid palatal expansion assisted by mini-implants)	DaCunha et al. ¹⁶ (2017)	Orlus, Ortholution (Seoul, Korea).	24 years	1	Four mini-implants (1.8mm diameter x 8mm and 7mm length)	One quarter turn (0.2 mm) once daily, with a full activation period of 40 days and a 3 mm retention period.
MARPE (Rapid palatal expansion assisted by mini-implants)	Lee et al. ²² (2018)	-----	18 years	1	Four Mini-implants	One turn a day was applied.
MARPE (Rapid palatal expansion assisted by mini-implants)	Suzuki et al. ²⁹ (2018)	PecLab, (Belo Horizonte, Brazil)	35 years	1	Expander screw (9mm) and 4 mini implants The mini-implants they were 1.8 mm in diameter and their length were 11 mm for the previous ones (7 mm thread and 4mm neck) and 9 mm length for the back (5 mm thread and neck of 4 mm)	1/4 activation twice a day to 10 days.
MARPE (Rapid palatal expansion assisted by mini-implants)	Lo Giudice et al. ³⁸ (2020)	BioMaterials (Korea Inc, Seoul, Korea).	25 years	1	Four mini-implants self-drilling (1.8 mm diameter, 11 mm length)	Two turns per day (0.13 mm widening per turn).
MARPE (Rapid palatal expansion assisted by mini-implants)	Kim et al. ⁸ (2021)	KBE; BioMaterials (Korea Inc., Seoul, Korea).	60 years	1	Four mini-implants (length, 9.0 mm; length, 7.0 mm and diameter, 2.0 mm diameter, 2.0 mm)	One turn per day (semi-rapid expansion protocol, 0.2mm/day).
MARPE (Rapid palatal expansion assisted by mini-implants)	Shin et al. ²⁰ (2019)	ORLUS; Ortholution, (Seoul, Korea)	Mean age, 22.52 ± 5.11 years	31	Four mini-implants (diameter: 1.8mm, length 7.0mm)	1 turn/day (0.2 mm/turn).

Method	Author the device	Origin of participants	Age of the participants	Amount of mini-implants	Description of protocol	Activation
(MARME) Rapid maxillary expansion assisted by mini-implants	Kim et al. ⁴² (2018)	ORLUS; Ortholution, (Seoul, Korea)	22.7 6 3.3 years; range, 18.3-26.5 years	14	Four Mini-implants with a collar of 1.8 mm in diameter and 7 mm in length	Once a day (0.2 mm/turn).
Skeletal anchor maxillary expander and aligners	Lombardo et al. ³³ (2018)	Spider Screw, Regular plus, HdC (Thiene, Italy).	23 years	1	Four mini-implants (two of 11 mm and two of 9 mm)	Two activations per day.
MARPE (Rapid palatal expansion assisted by mini-implants)	Naveda et al. ⁵⁴ (2022)	Peclab, (Belo Horizonte, Brazil)	29.1 ± 8.0 years; range, 20.1–45.1	21	Expander with four 1.8 × 7 mm paramedian mini-implants	2/4 turn post-installation, then 1/4 turn (0.2 mm) twice a day, consecutively. When having diastema 1/4 turn a day.

of fusion of the mid-palatal suture can create difficulties in prescribing the appropriate treatment to choose from: surgical or non-surgical expansion. For this reason, the mid-palatal suture density index has also been proposed as a predictive means to assess the skeletal response to RME.¹⁹ Age, palatal length, and stage of suture maturation may be other predictors of midpalate suture expansion in young adults.²⁰

2. METHODS USED TO PERFORM RAPID MAXILLARY EXPANSION IN ADULTS

Bone anchoring devices are indicated when a large amount of tooth movement is required or when tooth anchorage is insufficient, such as hypodontia or periodontal disease. These devices are also useful when asymmetric tooth movements are required, during intrusive mechanics, for intermaxillary fixation/traction, and during orthopedic traction. These appliances appear to be gaining acceptance in routine orthodontic practice.²¹ Table 2 describes the devices reported in the literature and their different activation protocols.

The devices reported in the literature (Table 2) come under different names, such as MARPE (Mini-implant Assisted Rapid Palatal Expansion), MSE (Maxillary Skeletal Expander), what is a type of MARPE, MARME (Rapid Maxillary Expansion Assisted by mini-implants), TAME (traditional tooth-anchored maxillary expander), BAME (bone-anchored maxillary expander), and I-SAMP (intraorally skeletally anchored maxillary extension and associated mini-implants). In all of them, they use 4 palatal mini-implants with diameters ranging from 1.5 to 2 mm and lengths from 7 to 13 mm, need activations from 0.13 to 0.2 mm per day, reaching up to around 40 days, achieving clinical evidence of over correction of transverse alteration.^{8,16,18,20,22-24}

3. COMPLICATIONS OF RME

A complication rate for non-surgical rapid expansion of 18.5% has been reported. A careful design and expansion protocol (polycyclic and slow) seems to be beneficial to avoid unreliable results in older patients.²⁵

Particularly, immediately after expansion, unde-

sirable effects include discomfort in the incisor or nasal suture regions and ulceration or necrosis of the palatal mucosa. There may be some swelling at the mid-palatal suture. Ischemia and mucosal necrosis may occur when the suture does not yield to the administered forces.¹¹ Rare transient complications of RME are dizziness, epistaxis, transient diplopia, or even oculomotor nerve compression.²⁶

Regarding the forces produced during the RME transmitted by the dental tissue, more resorption was observed in the vestibular surface than on the tongue-facing surface, and further reabsorption was observed in the apical and middle thirds than in the cervical third. Unlike skeletally transmitted RME, root resorption was observed despite the fact that support was not provided by teeth. Despite this, the reabsorption was not expressed in significant quantities.²⁷

Significantly more root resorption has been reported in the RME treatment transmitted by the dental support group compared to the RME with skeletal support group. When maxillary transverse deficiency was treated with the use of tooth-supported RME, more root resorption occurred in the cervical, middle, and apical thirds and on the buccal and lingual sides than with the use of skeletal-supported RME.²⁷

4. EFFECTS OF MAXILLARY EXPANSION

4.1 DENTOALVEOLAR EFFECTS

Regarding dental effects, the molar inclination relative to the maxillary bone, obtained from the basal bone angle of the molar, did not show significant changes with RME therapy and maxillary bone anchorage, when pre- and post-treatment cone-beam computed tomography images were superimposed, while the intermolar distance increased significantly.¹⁷ The effects of MARPE were of greater potentiation at the skeletal level with a reduced dental effect.^{17,23,28-30,30}

With the introduction and use of mini-implants, as temporary orthodontic anchorage devices,

the dentoalveolar effects decrease, considering that the dental arch can be relocated to a target position without surgery.³¹ Recordings after MARPE treatment showed increase in intermolar width of about 5 mm, contribution to the bilateral molar and canine relationships, coincidence of the dental midlines, and adequate intercuspation.¹⁶ It would also provide an increase in the length of the upper arch, to solve crowding.^{16,22}

Long-term dental changes in rapid maxillary expansion with anchorage tooth-supported versus skeletal anchorage, evidenced different long-term dental changes in the transverse, anteroposterior, and vertical planes of treatment. The greatest changes occurred in the transverse plane. Changes vertically and anteroposteriorly were negligible.³² Not wanted dental effects can be successfully reduced with bone anchorage and RME.³³

4.2 SKELETAL AND FACIALS EFFECTS

In late adolescent patients, treated with a bone-anchored maxillary expander, has been reported important lateral displacement of the zygomaticomaxillary complex, and therefore an increase in interzygomatic width.¹⁷ The amount of bone formed is less than the amount of bone lost after tooth translation, resulting in a net decrease in buccal bone thickness and crestal bone loss.^{3,4} When comparing the transverse dental and skeletal effects after use of self-ligating brackets versus MARPE plus conventional brackets, MARPE showed more skeletal effects compared to the use of self-ligating brackets, which presented more dental effects.²³

The use of MARPE with non-bicortical penetration in four palatal mini-implants produced fewer orthopedic effects and more unwanted dentoalveolar side effects, whereas with two posterior bicortical and four bicortical mini-implants it showed similar skeletal effects, meaning that the two posterior bicortical penetrations of the mini-implants were critical for skeletal expansion.³⁵

Expansion treatments with MARPE, TAME, BAME expanded the maxilla, dentition, and maxillary basal bone favorably, with minimal upper facial effects on

structures furthest from the palate. Particularly, the MARPE type MSE, showed much greater skeletal changes than TAME and BAME, especially in the floor of the nose, the base of the maxilla, and the palatal suture. It is suggested that MSE may be a great alternative method to correct maxillary skeletal transverse deficiency.³⁶

The evaluation of the effectiveness of the skeletal expansion procedure of the maxilla showed a correction of the posterior crossbite.^{8,33,37} and confirmed a skeletal opening of the mid-palatal suture.^{19,38} Non-surgical maxillary expansion in young adults may be a useful modality to improve breathing in patients with maxillary constriction, as it has shown a significant increase in the volume and transverse area of the nasal cavity.¹⁸

Skeletal and dentoalveolar variations achieved following RME assisted by mini-implants in young adults studied by means of cone beam computed tomography,³³ has shown that the mid-palatal suture separates and the maxilla shows statistically significant lateral movement of transverse maxillary deficiency without surgery in young adults.^{39,40}

At the TMJ level, it has been suggested that for adult patients with skeletal class III malocclusion with horizontal mandibular deviation, after MARPE, the condyle on the deviated side rotated towards the non-deviated side in a coronal direction and vertical condylar remodeling occurred mainly in the TMJ deviated side.⁴¹

After evaluating the changes in the volume and transverse area of the nasal airway before and one year after mini-implant-assisted rapid non-surgical maxillary expansion (MARME) in young adults, it was found that the volume of the nasal cavity showed a significant increase at the beginning (end of activation) and at the end of treatment, while of the nasopharynx increased only at the end. The anterior and median transverse areas increased significantly, while the posterior transverse area did not show significant changes. In this regard, it is considered that MARME may be useful for expanding the nasal airways.⁴²

After using MARPE at the soft tissue level, increase in sub-nasal soft tissues volume and decrease in the surface area of the soft palate have mainly been observed.⁴³

5. COMPLEMENTARY METHODS TO OPTIMIZE RME

It has been proposed that some non-surgical interventions reduce treatment time, include self-ligating brackets, conventional brackets and custom-made wires, drugs, injection of cellular mediators, low-level lasers, photodynamic therapy, low- and high-frequency electromagnetic fields, and vibrations.⁴⁴ Also It is suggested employ some of these complementary methods to support the treatment of maxillary constriction.³

Surgical interventions have been used to increase the rate of tooth movement followed by a decrease in the duration of treatment, surgical methods, such as osteotomies, corticotomies with or without bone grafting, and less invasive techniques, including piezocisions, piezopuncture, and microosteopuncture to stimulate the natural mechanisms of the bone which, in turn, increase the speed of tooth movement.⁴⁴

Laser has been studied as a mechanism that contributes to bone remodeling in the palatal suture by RME. Davoudi *et al.*,³ reported, through a systematic review, the use of laser as a complement that favors its use in RME. Based on the studies available in the review, it is better to use low-power laser therapy in the early phase of RME, because it has some benefits in increasing the rate of bone remodeling.^{4,5}

Despite limited evidence, low-level laser therapy appears to be a promising intervention to stimulate immediate bone regeneration and healing after mid-palate suture expansion. Long-term randomized clinical trials are needed to formulate safe results and establish a reliable clinical protocol, making the method clinically applicable.⁴⁶

Micro-osteoperforation is used to increase tooth movement, reduce difficult orthodontic movements, and also contribute to adjust anchorage.⁴⁵ However,

there are conflicting studies on the efficacy and adverse effects of this intervention.⁴⁴

The choice of one of these methods could support recent others, which have a preference for performing a supported breaker anchorage in the palatine bone through mini-implants,⁴⁷ that could favor specific movements and reduce the risk of root resorption.⁴⁸

6. SUCCESS AND STABILITY OF THE USE OF EXPANDERS IN ADULTS

A success rate of 84.4.²⁵ and 85%⁴⁹ of expansion into adults has been reported. However, clinicians should consider that the success rate of MARPE and the amount of suture separation may depend on chronological age and gender, as older MARPE-treated patients, particularly men, may have a reduced chance of successful suture separation and sufficient expansion of the basal bone.¹⁵

Although, to determine the validity of bone anchorage, it is necessary to evaluate the clinical efficacy and stability in adults after expansion, it has also been evidenced in various ways the success of maxillary expansion with mini-implants, such as its contribution to increasing the volume and transverse area of the nasal airway in young adults.¹⁸ However, it is also have documented possible limitations and side effects of conventional RME in adults, such as expansion failure or limited skeletal expansion, pain, tissue swelling, tilting of the buccal crown, gingival recession, root resorption, ulceration, even unstable results.⁵⁰

It has been reported that the clinical superiority of surgical expansion vs non-surgical has been controversial, possibly due to the lack of controlled studies, especially in adults.⁵¹ Clearly, non-surgical expansion can ensure basal bone expansion in most attempted cases. However, the amount of baseline bone expansion and non-surgical stability may be comparable to that of surgical expansion, as reported by Choi *et al.*,⁵² Where the measurements of the clinical heights of the left and right crown of

each tooth were not significantly different and were combined. In another investigation⁵³ changes in the clinical heights of the crowns of the canines, first premolars, and first molars were not significantly different at each time point. The amount of gingival recession was not significant, averaging 0.57 to 0.86 mm.

The mid-palatal suture repair pattern after MARPE-assisted rapid palatal expansion in adult patients shows decreased bone density after the retention period compared to the pre-expansion stage. Most adult patients demonstrated incomplete repair of the midpalate suture 16 months after MARPE. Bone repair was observed covering more than half of the extension of the hard palate in 80.95% of the patients. The middle third of the hard palate was the most frequently unrepaired region. In contrast, the anterior region of the hard palate showed bone formation in all patients after MARPE.⁵⁴

DISCUSSION.

The reported results show the possibility of performing RME in adults, whose effects are also manifested with expansion in the facial half, as reported by the study by Cantarella *et al.*,¹⁷ in which the zygomatic bone was displaced⁵⁵ significantly in a lateral direction during maxillary expansion assisted by mini-implants, similar to what was found in another study,⁵⁶ which showed that the maxilla and the entire zygomatic arch were significantly displaced in a lateral direction after expansion using MSE. Such results could be due to significant bone flexion in the zygomatic process of the temporal bone during maxillary expansion with mini-implants.⁵⁶

Other skeletal structures that showed other changes with MARPE were the nasal floor and maxillary base, as well as the palatal suture.³⁶ This technique improved airflow and decreased resistance in the upper airway; therefore, it is suggested that it may be an effective treatment modality for adult patients with moderate obstructive sleep apnea syndrome.^{49,58}

MARPE treatment showed a high predictability

of success in younger patients,³¹ with lower success rates in patients older than 30 years old,⁵⁸ promoted a greater increase in the intercanine and intermolar distances and nasal base, in addition to the maxillary skeletal width.^{19,23}

The design and activation protocol differed between studies. The length, diameter, position and number of mini-implants placed also showed a wide variation.⁹

Given that the techniques studied contribute to the correction of transverse skeletal discrepancies in adult patients, the studies agree on the control of dentoalveolar side effects.^{16,17} Therefore, it should be considered as an alternative to manage the length of the arch perimeter, especially in limited orthodontics for adults.¹⁶ Likewise, it has been reported that the dental tilt in the molars was insignificant during treatment.¹⁷

The focus of the present review was to consider non-surgical devices; however, it should be noted that a new minimally invasive surgical technique (MISMARPE) has recently been reported to treat maxillary hypoplasia in adult patients. The technique consists of the use of MARPE and a minimally invasive approach with maxillary osteotomies, with a latency period and an activation period until the desired expansion. A comparative analysis showed significant increases in maxillary width at the skeletal, alveolar, and dental levels. The technique could have potential for clinical use, but larger comparative studies are needed to confirm the clinical relevance of the approach.⁵⁹

A minimally invasive surgical procedure called the corticopuncture method, which consists of performing punctures along the mid-palatal suture, as a complement to the RME technique, it can be beneficial in adult patients who may present resistance of the mid-palatal suture and adjacent sutures due to the high interdigitation of these structures.²⁹ The laser has also been studied as a mechanism that helps with bone remodeling in palatal suture by RME.^{3,46} However, it is necessary

to continue with additional studies to further validate its incorporation into this therapy.

The efficacy of a combined protocol that includes a rapid palatal expander plus mini-implants and aligners has also been reported to resolve class III malocclusions, despite the widespread belief that non-surgical correction of such cases is impossible. In this case, it is also considered digital planning for the insertion of mini-implants as a good complementary therapeutic option for patients with advanced skeletal maturity.³³ This is one more indicator of the progressive acceptance that rapid maxillary expansion has been having in adults; however, it is necessary to emphasize the need to carry out more studies to confirm the preliminary results that have been reported.

CONCLUSION.

The reviewed scientific literature shows evidence that there are various devices supported by mini-implants as non-surgical treatment options to correct transverse deficiency and help expand the maxilla in adult patients. Starting with a diagnosis with tomographic support, with these methods, the effects at the dental level are minimal and at the skeletal level are satisfactory, especially thanks to the bicortical anchorage; likewise, they can contribute substantially to improving breathing in young adults with maxillary constriction. With a low complication rate, there are encouraging results on complementary mechanisms to support RME in adults with mini-implants, such as laser and osteoperforation. Finally, good stability of the treatment can be expected; however, more long-term studies are needed to strengthen the reported findings.

Conflict of interests:

There are no potential conflicts of interest relevant to this literature review.

Ethics approval:

Santo Toribio de Mogrovejo Catholic University.
Chiclayo, Peru.

Funding:

Self-funded.

Authors' contributions:

Both authors contributed to the search process and development of the review.

Acknowledgements:

We appreciate the valuable contributions of Drs. Miriam De Jesus Arellanos Tafur and Rosa Josefina Roncal Espinoza.

REFERENCES.

1. Asiri SN, Tadlock LP, Buschang PH. The prevalence of clinically meaningful malocclusion among US adults. *Orthod Craniofac Res.* 2019;22(4):321–8.
2. Proffit WR, Phillips C, Dann C. Who seeks surgical-orthodontic treatment? *Int J Adult Orthodon Orthognath Surg.* 1990;5(3):153–60.
3. Davoudi A, Amrolahi M, Khaki H. Effects of laser therapy on patients who underwent rapid maxillary expansion; a systematic review. *Lasers Med Sci.* 2018;33(6):1387–95.
4. De la Iglesia G, Walter A, De la Iglesia F, Winsauer H, Puigdollers A. Stability of the anterior arm of three different Hyrax hybrid expanders: an in vitro study. *Dental Press J Orthod.* 2018;23(1):37–45.
5. Ghoneima A, Abdel-Fattah E, Hartsfield J, El-Bedwehi A, Kamel A, Kula K. Effects of rapid maxillary expansion on the cranial and circummaxillary sutures. *Am J Orthod Dentofacial Orthop.* 2011;140(4):510-9. doi: 10.1016/j.ajodo.2010.10.024. PMID: 21967938; PMCID: PMC5161454.
6. Cannavale R, Chiodini P, Perillo L, Piancino MG. Rapid palatal expansion (RPE): Meta-analysis of long-term effects. *Orthod Craniofac Res.* 2018;21(4):225–35.
7. Rojas V, Macherone C, Zursiedel MI, Valenzuela JG. Rapid maxillary expansion in young adults: comparison of tooth-borne and bone-borne appliances, a cohort study. *Journal of Oral Research.* 2019;8(3):201–9.
8. Kim H, Park S-H, Park JH, Lee K-J. Nonsurgical maxillary expansion in a 60-year-old patient with gingival recession and crowding. *Korean J Orthod.* 2021;51(3):217–27.
9. Lyu CX, Yang L, Chen LL, Yu FY, Lu HP. Advance and review: miniscrew-assisted rapid palatal expansion. *Zhonghua Kou Qiang Yi Xue Za Zhi* 2019;54(11):778–82.
10. Kasrovi PM, Meyer M, Nelson GD. Occlusion: an orthodontic perspective. *J Calif Dent Assoc.* 2000; 28(10):780–90.
11. Suzuki H, Moon W, Previdente LH, Previdente L, Syuri S, Silva A, et al. Miniscrew-assisted rapid palatal expander (MARPE): the quest for pure orthopedic movement. *Dental Press J Orthod.* 2016;21(4):17–23.
12. Quinzi V, Rossi O, Paglia L, Marzo G, Caprioglio A. Paediatric Orthodontics Part 2: Periodontal effects of maxillary expansion. *Eur J Paediatr Dent.* 2019;20(2):164–6.
13. Abdullatif J, Certal V, Zaghi S, Song SA, Chang ET, Gillespie MB, Camacho M. Maxillary expansion and maxillomandibular expansion for adult OSA: A systematic review and meta-analysis. *J Craniomaxillofac Surg.* 2016;44(5):574-8. doi: 10.1016/j.jcms.2016.02.001. Epub 2016 Feb 6. PMID: 26948172.
14. Angeleri F, Cevidanes LH, Franchi L, Gonçalves JR, Benavides E, McNamara JA Jr. Midpalatal suture maturation: classification method for individual assessment before rapid maxillary expansion. *Am J Orthod Dentofacial Orthop.* 2013 Nov;144(5):759-69. doi: 10.1016/j.ajodo.2013.04.022. PMID: 24182592; PMCID: PMC4185298.
15. Isfeld D, Flores-Mir C, Salazar L, Lagravère M. Evaluation of a novel palatal suture maturation classification as assessed by cone-beam computed tomography imaging of a pre- and postexpansion treatment cohort. *Angle Orthod.* 2019;89(2):252–61.
16. Cunha AC, Lee H, Nojima LI, Nojima M, Lee K-J. Miniscrew-assisted rapid palatal expansion for managing arch perimeter in an adult patient. *Dental Press J Orthod.* 2017;22(3):97–108.
17. Cantarella D, Dominguez-Mompell R, Moschik C, Mallya SM, Pan HC, Alkahtani MR, Elkenawy I, Moon W. Midfacial changes in the coronal plane induced by microimplant-supported skeletal expander, studied with cone-beam computed tomography images. *Am J Orthod Dentofacial Orthop.* 2018 Sep;154(3):337-345. doi: 10.1016/j.ajodo.2017.11.033. PMID: 30173836.
18. Kim SY, Park YC, Lee KJ, Lintermann A, Han SS, Yu HS, Choi YJ. Assessment of changes in the nasal airway after nonsurgical miniscrew-assisted rapid maxillary expansion in young adults. *Angle Orthod.* 2018 Jul;88(4):435-441. doi: 10.2319/092917-656.1. Epub 2018 Mar 21. PMID: 29561652; PMCID: PMC8191933.
19. Annarumma F, Posadino M, De Mari A, Drago S, Aghazada H, Gravina GM, Qorri E, Silvestrini-Biavati A, Migliorati M. Skeletal and dental changes after maxillary expansion with a bone-borne appliance in young and late adolescent patients. *Am J Orthod Dentofacial Orthop.* 2021;159(4):e363-e375. doi: 10.1016/j.ajodo.2020.11.031. Epub 2021 Feb 8. PMID: 33573898.
20. Shin H, Hwang CJ, Lee KJ, Choi YJ, Han SS, Yu HS. Predictors of midpalatal suture expansion by miniscrew-assisted rapid palatal expansion in young adults: A preliminary study. *Korean J Orthod.* 2019 Nov;49(6):360-371. doi: 10.4041/kjod.2019.49.6.360. Epub 2019 Nov 26. PMID: 31815104; PMCID: PMC6883215.
21. Alkadhimi A, Al-Awadhi EA. Miniscrews for orthodontic anchorage: a review of available systems. *J Orthod.* 2018;45(2):102–14.
22. Lee K-J, Choi S-H, Choi T-H, Shi K-K, Keum B-T. Maxillary transverse expansion in adults: Rationale, appliance design, and treatment outcomes. *Semin Orthod.* 2018;24(1):52–65.
23. Calil RC, Marin Ramirez CM, Otazu A, Torres DM, Gurgel JA, Oliveira RC, de Oliveira RCG, Valarelli FP, Freitas KMS. Maxillary dental and skeletal effects after treatment with self-ligating appliance and miniscrew-assisted rapid maxillary expansion. *Am J Orthod Dentofacial Orthop.* 2021 Feb;159(2):e93-e101. doi: 10.1016/j.ajodo.2020.09.011. Epub 2020 Dec 4. PMID: 33288357.
24. Ganesh G, Tripathi T, Rai P. Orthopaedic and orthodontic treatment with hyrax, Class III elastics on mandibular miniplates, maxillary mini-implants in a Class III adolescent: A case report. *Int Orthod.* 2020;18(4):827–38.

25. Winsauer H, Walter A, Katsaros C, Ploder O. Success and complication rate of miniscrew assisted non-surgical palatal expansion in adults - a consecutive study using a novel force-controlled polycyclic activation protocol. *Head Face Med.* 2021;17(1):50
26. Lanigan DT, Mintz SM. Complications of surgically assisted rapid palatal expansion: review of the literature and report of a case. *J Oral Maxillofac Surg.* 2002;60(1):104–10.
27. Yildirim M, Akin M. Comparison of root resorption after bone-borne and tooth-borne rapid maxillary expansion evaluated with the use of microtomography. *Am J Orthod Dentofacial Orthop.* 2019;155(2):182–90.
28. Seong E-H, Choi S-H, Kim H-J, Yu H-S, Park Y-C, Lee K-J. Evaluation of the effects of miniscrew incorporation in palatal expanders for young adults using finite element analysis. *Korean J Orthod.* 2018;48(2):81–9.
29. Suzuki SS, Braga LFS, Fujii DN, Moon W, Suzuki H, et al. Corticopuncture Facilitated Microimplant-Assisted Rapid Palatal Expansion. *Case Rep Dent.* 2018;2018:1392895.
30. Paik C-H, Park K-H, Park JH. New orthopedic and orthodontic treatment modality for adult patients with skeletal Class III malocclusion with insufficient maxillary incisor exposure. *AJO-DO CC.* 2021;1(1):22–30.
31. Choi S-H, Jeon JY, Lee K-J, Hwang C-J. Clinical applications of miniscrews that broaden the scope of non-surgical orthodontic treatment. *Orthod Craniofac Res.* 2021;24 Suppl 1:48–58.
32. Davami K, Talma E, Harzer W, Lagravère MO. Long term skeletal and dental changes between tooth-anchored versus Dresden bone-anchored rapid maxillary expansion using CBCT images in adolescents: Randomized clinical trial. *Int Orthod.* 2020;18(2):317–29.
33. Lombardo L, Carlucci A, Maino BG, Colonna A, Paoletto E, Siciliani G. Class III malocclusion and bilateral cross-bite in an adult patient treated with miniscrew-assisted rapid palatal expander and aligners. *Angle Orthod.* 2018 Sep;88(5):649–664. doi: 10.2319/111617-790.1. Epub 2018 May 1. PMID: 29714067; PMCID: PMC8183134.
34. Christoph KM, Campbell PM, Feng JQ, Taylor RW, Jacob HB, Buschang PH. Effects of transverse bodily movements of maxillary premolars on the surrounding hard tissue. *Am J Orthod Dentofacial Orthop.* 2020 Apr;157(4):490–502. doi: 10.1016/j.ajodo.2018.11.022. PMID: 32241356.
35. Li N, Sun W, Li Q, Dong W, Martin D, Guo J. Skeletal effects of monocortical and bicortical mini-implant anchorage on maxillary expansion using cone-beam computed tomography in young adults. *Am J Orthod Dentofacial Orthop.* 2020;157(5):651–61.
36. Oh H, Park J, Lagravere-Vich MO. Comparison of traditional RPE with two types of micro-implant assisted RPE: CBCT study. *Semin Orthod.* 2019;25(1):60–8.
37. Bucci R, D'Antò V, Rongo R, Valletta R, Martina R, Michelotti A. Dental and skeletal effects of palatal expansion techniques: a systematic review of the current evidence from systematic reviews and meta-analyses. *J Oral Rehabil.* 2016;43(7):543–64. doi: 10.1111/joor.12393. Epub 2016 Mar 23. PMID: 27004835.
38. Lo Giudice A, Quinzi V, Ronsivalle V, Martina S, Bennici O, Isola G. Description of a Digital Work-Flow for CBCT-Guided Construction of Micro-Implant Supported Maxillary Skeletal Expander. *Materials (Basel).* 2020;13(8):1815. doi: 10.3390/ma13081815. PMID: 32290597; PMCID: PMC7215674.
39. Nucera R, Lo Giudice A, Bellocchio AM, Spinuzza P, Caprioglio A, Perillo L, Matarese G, Cordasco G. Bone and cortical bone thickness of mandibular buccal shelf for mini-screw insertion in adults. *Angle Orthod.* 2017;87(5):745–751. doi: 10.2319/011117-34.1. Epub 2017 Jun 9. PMID: 28598220; PMCID: PMC8357207.
40. Park JJ, Park YC, Lee KJ, Cha JY, Tahk JH, Choi YJ. Skeletal and dentoalveolar changes after miniscrew-assisted rapid palatal expansion in young adults: A cone-beam computed tomography study. *Korean J Orthod.* 2017;47(2):77–86. doi: 10.4041/kjod.2017.47.2.77. Epub 2017 Jan 25. PMID: 28337417; PMCID: PMC5359634.
41. Chen S, Zhang C, Zhang K, Tan X, Xi X, Zhao Y, Liu D. Condylar morphology and position changes after miniscrew-assisted rapid palatal expansion in skeletal Class III malocclusion adult patients with mandibular deviation and unilateral posterior crossbite. *Prog Orthod.* 2022;23(1):30. doi: 10.1186/s40510-022-00425-4. PMID: 36045260; PMCID: PMC9433628.
42. Kim SY, Park YC, Lee KJ, Lintermann A, Han SS, Yu HS, Choi YJ. Assessment of changes in the nasal airway after nonsurgical miniscrew-assisted rapid maxillary expansion in young adults. *Angle Orthod.* 2018 Jul;88(4):435–441. doi: 10.2319/092917-656.1. Epub 2018. PMID: 29561652; PMCID: PMC8191933.
43. Shetty A, Ratti S, Nakra P, Shetty S, Mohammed A, Saidath K. Evaluation of Soft Tissue and Airway Changes in Individuals Treated with Mini-Implant Assisted Rapid Palatal Expansion (MARPE). *J Long Term Eff Med Implants.* 2022;32(1):7-18. doi: 10.1615/JLongTermEffMedImplants.2021038874. PMID: 35377989.
44. Shahabee M, Shafae H, Abtahi M, Rangrazi A, Bardideh E. Effect of micro-osteoperforation on the rate of orthodontic tooth movement-a systematic review and a meta-analysis. *Eur J Orthod.* 2020;42(2):211–21.
45. Manni A, Lupini D, Cozzani M. Bone-anchored inter-maxillary elastics in an asymmetric Class III malocclusion: A case report. *Int Orthod.* 2017;15(2):263–77.
46. Skondra FG, Koletsi D, Eliades T, Farmakis ETR. The Effect of Low-Level Laser Therapy on Bone Healing After Rapid Maxillary Expansion: A Systematic Review. *Photomed Laser Surg.* 2018;36(2):61–71.
47. Cano JA, Ortega D, Peña JF, Fernández E, Gao E, López J, Girón J. Sarpe. Bone anchoring technique. Case report and review. *Cient Dent.* 2017:69–75.
48. Greco M, Rossini G, Rombolà A. Simplifying the approach of open bite treatment with aligners and selective micro-osteoperforations: An adult case report. *Int Orthod.* 2021;19(1):159–69.
49. Brunetto DP, Moschik CE, Dominguez-Mompell R, Jaria E, Sant'Anna EF, Moon W. Mini-implant assisted rapid palatal expansion (MARPE) effects on adult obstructive sleep apnea (OSA) and quality of life: a multi-center prospective controlled trial. *Prog Orthod.* 2022;23(1):3. doi: 10.1186/s40510-021-00397-x. PMID: 35102477; PMCID: PMC8804045.
50. Jeon JY, Choi S-H, Chung CJ, Lee K-J. The success and effectiveness of miniscrew-assisted rapid palatal expansion are age- and sex-dependent. *Clin Oral Investig.* 2022;26(3):2993–3003.

51. Cao Y, Zhou Y, Song Y, Vanarsdall RL. Cephalometric study of slow maxillary expansion in adults. *Am J Orthod Dentofacial Orthop.* 2009;136(3):348–54.
52. Chung C-H, Goldman AM. Dental tipping and rotation immediately after surgically assisted rapid palatal expansion. *Eur J Orthod.* 2003;25(4):353–8.
53. Choi S-H, Shi K-K, Cha J-Y, Park Y-C, Lee K-J. Nonsurgical miniscrew-assisted rapid maxillary expansion results in acceptable stability in young adults. *Angle Orthod.* 2016;86(5):713–20.
54. Lim H-M, Park Y-C, Lee K-J, Kim K-H, Choi YJ. Stability of dental, alveolar, and skeletal changes after miniscrew-assisted rapid palatal expansion. *Korean J Orthod.* 2017;47(5):313–22.
55. Naveda R, Dos Santos AM, Seminario MP, Miranda F, Janson G, Garib D. Midpalatal suture bone repair after miniscrew-assisted rapid palatal expansion in adults. *Prog Orthod.* 2022;23(1):35. doi: 10.1186/s40510-022-00431-6. PMID: 36244995; PMCID: PMC9573844.
56. Carvalho L, González A, Moreira C, Barbosa E. Stresses and Strains Analysis Using Different Palatal Expander Appliances in Upper Jaw and Midpalatal Suture. *Artif Organs.* 2017;41(6):E41–51.
57. Cantarella D, Dominguez-Mompell R, Moschik C, Sfogliano L, Elkenawy I, Pan HC, Mallya SM, Moon W. Zygomaticomaxillary modifications in the horizontal plane induced by micro-implant-supported skeletal expander, analyzed with CBCT images. *Prog Orthod.* 2018;19(1):41. doi: 10.1186/s40510-018-0240-2. PMID: 30345476; PMCID: PMC6196147.
58. Hur J-S, Kim H-H, Choi J-Y, Suh S-H, Baek S-H. Investigation of the effects of miniscrew-assisted rapid palatal expansion on airflow in the upper airway of an adult patient with obstructive sleep apnea syndrome using computational fluid-structure interaction analysis. *Korean J Orthod.* 2017;47(6):353–64.
59. Oliveira CB, Ayub P, Angelieri F, Murata WH, Suzuki SS, Ravelli DB, Santos-Pinto A. Evaluation of factors related to the success of miniscrew-assisted rapid palatal expansion. *Angle Orthod.* 2021;91(2):187-194. doi: 10.2319/051420-436.1. PMID: 33351888; PMCID: PMC8028491.
60. Haas Junior OL, Matje PRB, Rosa BM, Rojo-Sanchis C, Guijarro-Martínez R, Valls-Ontañón A, Menezes LM, Hernández-Alfaro F, de Oliveira RB. Minimally invasive surgical and miniscrew-assisted rapid palatal expansion (MISMARPE) in adult patients. *J Craniomaxillofac Surg.* 2022;50(3):211-217. doi: 10.1016/j.jcms.2021.12.011. Epub 2021 Dec 27. PMID: 34973887.