



PLASMA RICH IN GROWTH FACTORS IN FOREFOOT RECONSTRUCTION SURGERY

Abo Zaalán Wessam¹, Levon Gagikovich Makinyan², Nikolai Vasilivich Zagorodniy³, Arsen Yusufovich Khubiev⁴, Abdul Basith Shahul Hameed⁵

1. MS (Ortho), PhD fellow in the Department of Traumatology and Orthopedics, Peoples' Friendship University of Russia, Moscow; ORCID ID: 0000-0003-3922-3052.
2. PhD, Associate professor of the Department of Traumatology and Orthopedics, Peoples' Friendship University of Russia, Moscow; Head of Orthopedic Department № 2 in City Clinical hospital № 13, Moscow; Member of AOFAS; ORCID ID: 0000-0002-8813-143X.
3. Head of the Department of Traumatology and Orthopedics, Doctor of Medical.Science.Laureate of the Russian Government Award, Honored Scientist of the Russian Federation, Corresponding Member of the Russian Academy of Sciences, Professor.
4. MS (Ortho), Orthopedician at North Caucasian Federal Scientific Clinical Center of the Federal Medical and Biological Agency of Russia, 101 Clinical Hospital in Lermontov, Russia.
5. MS (Ortho), PhD fellow in the Department of Traumatology and Orthopedics, Peoples' Friendship University of Russia, Moscow; ORCID ID: 0000-0001-9948-2596.

ABSTRACT

Plasma rich in growth factors (PRGF) is a successful therapy in various sectors of medicines in the present decade. Its effectiveness in forefoot surgery is still unknown. The aim of our study is to analyze the outcomes of forefoot surgeries with the infiltration of PRGF. One hundred and eighty patients were divided into 2 groups. The first group included 90 patients where only forefoot



reconstruction was performed, whereas, in the second group PRGF was added. Scarf and Wilson osteotomies were performed for hallux valgus and tailor's bunion respectively. Clinical and radiological outcomes were monitored in both groups pre and postoperatively. The mean postoperative AOFAS scores were 67.82 (range: 32 – 82) and the mean postoperative Foot Function Index (FFI) was 0.51 (range: 0.23 to 0.63) in the PRGF group. Ninety percent (162/180 feet) reported early pain relief, improved cosmetic appearance and improved footwear comfort. The mean hallux valgus angles improved from 30° to 15°, 1st IMA from 15° to 8° and 4-5 IMA from a mean of 11° to 7° in both groups. Four feet had non-union of the Scarf osteotomy and three of them were re-operated. PRGF stimulates cell viability and proliferation and enhances the surgical treatment of forefoot deformities by reducing postoperative pain, edema, and rehabilitation period and improves cosmesis and comfort.

KEYWORDS: PRGF, Hallux valgus, Tailor Bunion, Scarf osteotomy, Wilson osteotomy, AOFAS, Foot Function Index

PLASMA RICO EN FACTORES DE CRECIMIENTO EN LA CIRUGÍA DE RECONSTRUCCIÓN DEL ANTEPIÉ

ABSTRACT

El plasma rico en factores de crecimiento (PRGF) es una terapia de éxito en varios sectores de la medicina en la presente década. Su eficacia en la cirugía del antepié es aún desconocida. El objetivo de nuestro estudio es analizar los resultados de las cirugías del antepié con la infiltración de PRGF. Ciento ochenta pacientes fueron divididos en 2 grupos. El primer grupo incluía 90 pacientes en los que sólo se realizó la reconstrucción del antepié, mientras que en el segundo grupo se añadió PRGF. Se realizaron osteotomías de Scarf y Wilson para el hallux valgus y el juanete de sastre, respectivamente. Los resultados clínicos y radiológicos se controlaron en ambos grupos antes y después de la operación. La media de las puntuaciones AOFAS postoperatorias fue de 67,82 (rango: 32 - 82) y la media del Índice de Función del Pie (FFI) postoperatorio fue de 0,51 (rango: 0,23 a 0,63) en el grupo PRGF. El noventa por ciento (162/180 pies) informaron de un



alivio temprano del dolor, una mejora del aspecto estético y una mayor comodidad del calzado. Los ángulos medios del hallux valgus mejoraron de 30° a 15°, la 1ª AMI de 15° a 8° y la 4-5 AMI de una media de 11° a 7° en ambos grupos. Cuatro pies tuvieron no-uni6n de la osteotomía de Scarf y tres de ellos fueron reoperados. El PRGF estimula la viabilidad y la proliferaci6n celular y mejora el tratamiento quirúrgico de las deformidades del antepié al reducir el dolor postoperatorio, el edema y el periodo de rehabilitaci6n, además de mejorar la cosmética y el confort.

PALABRAS CLAVE: PRGF, Hallux valgus, juanete de sastre, osteotomía de bufanda, osteotomía de Wilson, AOFAS, índice de funci6n del pie

INTRODUCTION

Forefoot reconstruction is an ultimate treatment option in cases of painful forefoot deformities especially when the medications and therapy fails (4). Scarf osteotomy is a common surgical method to correct moderate to severe hallux valgus deformities (1). After initial descriptions by Barouk and Weil (3, 4), several publications presenting powerful corrections and good outcomes with these techniques have been published (5, 6). However, the probability of recurrence is a common complication (7). There are several surgical choices for various forefoot deformities but the postoperative rehabilitation period remains longer (4).

Complex forefoot structure also adds to the reason. During postoperative periods patients are put in special shoes (Barouk) right from the next day of surgery until 6 weeks to avoid weight bearing on the forefoot. Patients also go under RICE (Rest, Ice, Compression and Elevation) regimens. Postoperative pain and edema are unpleasant and more sensitive patients undergo a tough time. And to restore completely back to normal healthy life, it takes around 3-4 months of time after several restrictions. This urges a need for an alternative to reduce the rehabilitation time, speedy recovery with better cosmesis by reducing edema and better wound healing.



Wound healing is a complex biological process that consists of hemostasis, inflammation, proliferation and remodeling (20). Growth factors play a vital role in regulating cellular processes such as mitogenesis, chemotaxis, cell differentiation and metabolism. Platelets enhance growth factors distribution in early stages of wound healing (21). In 1999, for the first time Anitua proposed Plasma rich in growth factors (PRGF) technology, an innovation in medical therapy (29). PRGF is a subtype of P-PRP (pure platelet-rich plasma). It is a supernatant enriched in plasma and platelet-derived morphogens, proteins and growth factors. PRGF represents a complex pool of active mediators that may stimulate and accelerate tissue regeneration, which is generally safe to use and inexpensive to obtain. “PRGF” relates 100% autologous and biocompatible formulations formed by a single-step process of centrifugation with calcium chloride and sodium citrate as activator and anticoagulant respectively. PRGF includes moderated platelet concentration but no leukocytes to avoid the proinflammatory effects of proteases and acid hydrolases in white blood cells (22, 23).

The use of PRGF is reported as a good treatment to improve pain, stiffness and functional capacity in articular surfaces, as well as improving soft tissue healing (16, 17). A recent randomized controlled trial showed that PRGF is safe and significantly superior to hyaluronic acid in patients with symptomatic knee osteoarthritis [8]. In 2010, Saegusa AW, et al. reported improvement in function and quality of life after intra-articular infiltration of PRGF in patients with OA of the knee (35). In 2015, Seijas R et al. documented improvement in pain, stiffness and functional capacity in patients after arthroscopic debridement of the acetabular rim and femoral neck for femoroacetabular impingement and injection of PRGF in OA hips (9).

Currently, PRGF administration is quite common. However, clear guidelines defining indication criteria are missing. The purpose of this study is to analyze the clinical and radiological outcomes in forefoot reconstruction with the PRGF administration.



METHODS

Between October 2018 and October 2021, 180 forefoot surgeries were performed on 180 patients who suffered from Hallux Valgus (HV) and Tailor's bunion. They were equally divided into 2 groups based on the administration of PRGF. The 1st group included 90 patients (90 feet) who underwent Scarf and Wilson osteotomies in the forefoot. The 2nd group had 90 patients (90 feet) whose Scarf and Wilson osteotomies were performed and intraoperative administration of PRGF was carried out. Operations were unilateral at a time. Average age of patients was 40 (28 to 48) years. The study included 176 female patients and 4 male patients, indicating higher frequency of incidence in females. Patients were admitted to the hospital only after all the medical

conclusions stating no signs of contraindications for surgery. The HV angle, the first and second intermetatarsal angles (IMA), the fourth and fifth IMA, the fifth toe metatarsophalangeal angle, the fifth metatarsal head width, and the fifth metatarsal lateral angulation angle were measured on the radiograph (Fig. 1). Grading of the tailor's bunion was made using Fallat's classification (Fig. 2). Only patients with Hallux valgus angle (HVA) between 20 and 30 degrees and type III deformity according to Fallat's classification were included into the study. All patients were given written informed consent. Patients underwent clinical and radiological examinations before and after the surgery followed by 3 years of follow up.

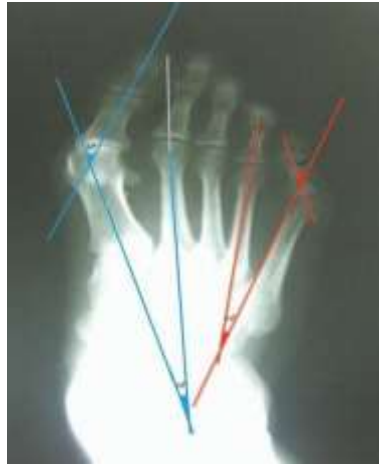

Figure 1: Preoperative weightbearing AP radiograph demonstrating forefoot deformities calculations.

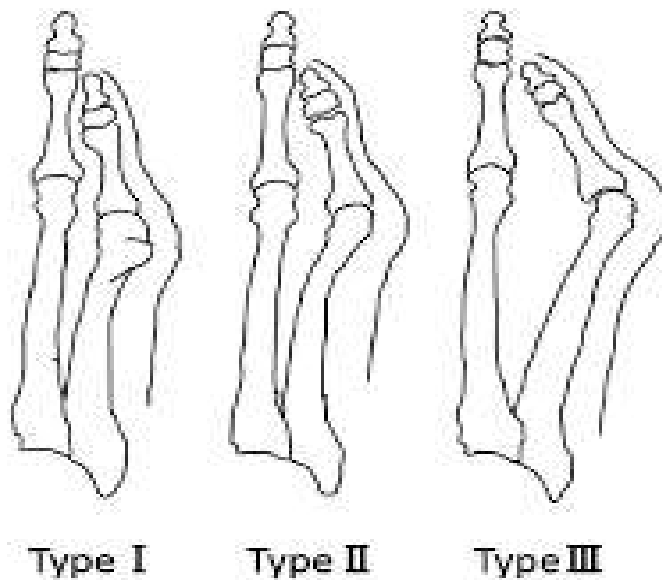


Figure 2: Fallat's classification. Type 1. Increased width of the MT head. Type 2. Deviation of the 5th MT. Type 3. Increased 4th & 5th IMA.

Plasma Rich in Growth Factors (PRGF)

Recibido: 3/7/2022
Aceptado: 3/8/2022

Thirty six milliliters of blood were collected from the veins of all patients. Collected blood was shifted to four vacutainer tubes, each containing blood anticoagulant of 5 milliliters in quantity. Followed by eight minutes of centrifugation at 460g allowing it to separate various blood phases (PRGF[®] System III, BTI Biotechnology Institute[®], Spain). The 2 milliliters rich plasma fragments present directly on top of the buffy

coat were extracted from each tube and shifted to a sterile vacutainer tube. PRGF activator (10% calcium chloride) was added to the liquid PRGF (50 microliters per milliliter of PRGF) to begin clotting and stimulate platelets to release growth factors. Activated PRGF allowed for four minutes at room temperature to form a consistent gelatinous layer and was used before the wound closure.




Figure 3: Preparation of PRGF and PRGF activator

Surgical procedure

Scarf osteotomy of 1st MT bone

Under the spinal anesthesia, patient in supine

position in the operating table. Tourniquet applied in the lower third of the leg. A dorsomedial incision with a length of 5 cm

performed, soft tissues are dissected along the medial side of the foot. Capsule of the first metatarsophalangeal joint (MTPJ) opened linearly. Bone-cartilaginous exostosis was resected with the help of an oscillator saw, followed by Scarf osteotomy of the first metatarsal (MT) bone. The osteotomy was Z-shaped with the distal lever on the dorsal aspect and the proximal lever on the plantar aspect with an angle of 45°. The distal fragment was shifted laterally with a slight varus rotation to realign the joint line. Fixation was achieved with 2 screws (2.5 or

3.0 mm—FRS-Screw [Fusion and Reconstruction System], at least one of them was positioned bicortically. The prominent medial aspect of the metatarsal shaft was resected with the saw. This piece of bone was grafted to the medial side of the metatarsal between distal and proximal lever. The tendon sheet of the extensor hallucis was kept intact. The transverse intermetatarsal ligament was released and capsulorrhaphy was performed to obtain normal position of the Hallux.

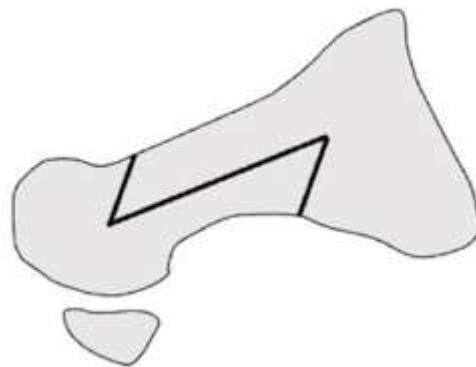


Figure 4: Scarf osteotomy

Wilson osteotomy of 5th MT bone

A 2 cm longitudinal incision along the outer surface of the 5th MTPJ of the foot performed. Soft tissues are dissected and capsule of the

5th MTPJ opened linearly. Wilson (oblique) osteotomy of the 5th MT bone performed followed by a medial shift in the distal fragment with a slight varus rotation to



realign the joint line. Bone-cartilaginous exostosis was resected using an oscillator saw. Fixation was achieved with 1 screw (2.5 or 3.0 mm—FRS-Screw).

PRGF - was administered intra- and extra-articular and over the soft tissues before the wound closure in the 2nd group but not used in the first group.

The wounds were repeatedly washed with antiseptic solutions. Capsules were sutured with №1 self-absorbable polyglactin 910 suture (Vicryl). The skin was closed by intradermal non-absorbable nylon №2 sutures. A dry aseptic dressing was applied. The tourniquet was removed. For the first forty-eight hours all patients had foot elevation and ice pack application to reduce postoperative edema. Postoperative radiographs were taken on the 2nd day. All patients were mobilized on 2nd day subsequently using specific non-weightbearing orthopedic (Barouk) shoes. They were discharged from the hospital once

swelling subsided, good results in dressing were noticed and good local and body temperature were evaluated. All the recommendations to be followed carefully were explained and given in written form. Patients were evaluated regularly in the outpatient clinic at 6 weeks, 3 months, 6 months, 1 year, 2 years and 3 years postoperatively. American Orthopaedic Foot and Ankle Society (AOFAS), Foot Funct 35 Index (FFI) and radiological findings were evaluated.

Statistical Analysis

With the help of statistics package SPSS version 23.0 (IBM Corp., Armonk, NY) statistical analysis was performed. Descriptive statistics values are indicated by standard deviation (SD), frequencies and percentages for nominal data. The Kendall rank correlation coefficient (r_ϕ) was utilized to evaluate the relation between pain, recurrence and satisfaction. Based on accepted standards, statistical significance was accepted to a 2-tailed P value of 0.05.

RESULTS

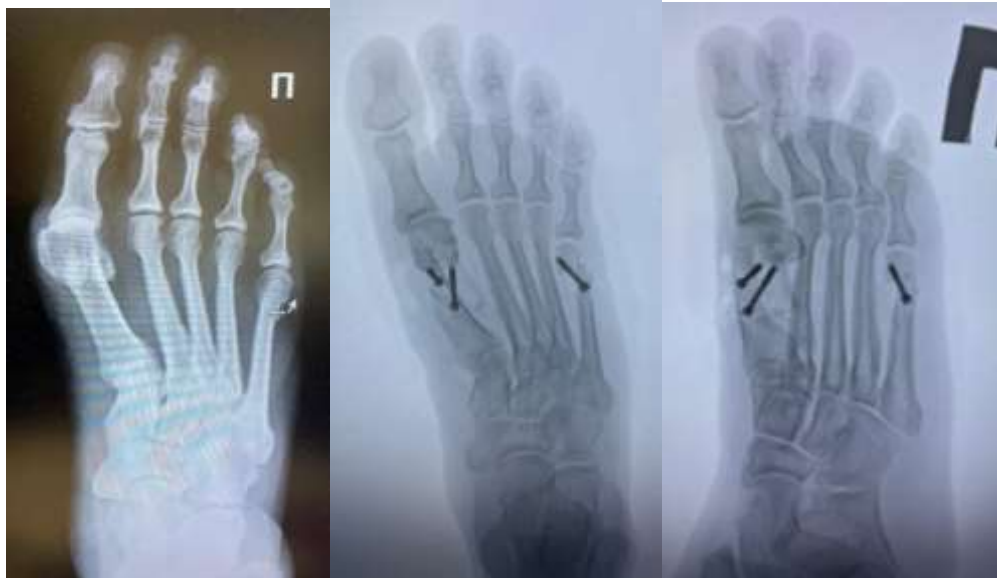

Figure 5: Pre and postoperative radiograph of Patient A with PRGF The above figure describes pre and post-op radiographs demonstrating hallux valgus and Tailor’s bunion and its correction by Scarf and Wilson osteotomy. Here, intraoperative infiltration of PRGF has taken place.

Table 1: Follow-up AOFAS scores of 180 patients

Pain	40 points	Function	35 points	Alignment	15 points
No. of feet	Score	No. of feet	Score	No. of feet	Score
128	40	103	27	130	15
26	30	38	22	40	8
13	20	20	19	10	0
13	0	19	14	-	-
Total = 180	Mean = 33	Total =180	Mean = 19.9	Total = 180	Mean = 12.1



Table 2: Foot Function Index

Category	Pre-op Mean score (1 to 10) (1 st group)	Post-op Mean score (1 to 10) (1 st group)	Pre-op Mean score (1 to 10) (2 nd group)	Post-op Mean score (1 to 10) (2 nd group)
Pain (VAS score)	8.7 (6 to 9)	2.6 (1 to 3)	8.8 (6 to 9)	2.1 (1 to 3)
Mobility	3.4 (3 to 5)	5.6 (5 to 7)	3.4 (3 to 5)	6.0 (5 to 7)
Footwear tolerance	3.4 (2 to 5)	7.2 (6 to 8)	3.4 (2 to 5)	7.6 (6 to 8)
Cosmetic appearance	1.8 (1 to 2)	8.3 (7 to 9)	1.8 (1 to 2)	8.9 (7 to 9)

Table 3: Anterior-posterior and lateral radiographs pre & postoperatively

Time period	1 st group	2 nd group (PRGF)
Before Sx	Hallux valgus, Tailor Deformity	Hallux valgus, Tailor Deformity
Next day of Sx	Corrected to normal anatomy	Corrected to normal anatomy
After 6 weeks	Signs of endosteal callus	Periosteal corn
After 3 months	Muff-like periosteal callus	Much larger periosteal callus
After 6 months	Periosteal clutch and signs of bone consolidation	Bone consolidation

After 12 months (fig. 6)	Bone fusion	Bone fusion with disappearance of the fracture line
After 24 months	Delayed complete reconstruction of the callus	Complete reconstruction of the callus

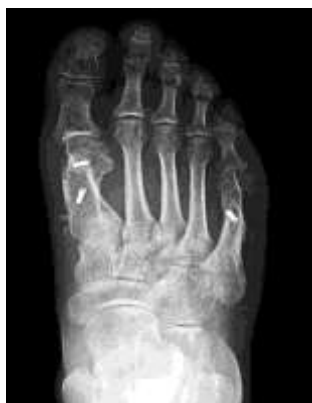

Figure 6: Postop radiograph after 12 months with bone fusion

Postoperative period:

1st group

Patients reported presence of pain until postoperative swelling began to subside. NSAIDs were taken on indications. After a week, patients noticed decrease of edema. All patients had intradermal sutures and thus prolonged edema lead to wound discharge, longer time to heal the suture. Dressings were done on every second or third day. Patients

were allowed walk on the 2nd day with Barouk shoes but they reported significant difficulties in walking due to pain. They could walk for a distance of 5 meters for 5 minutes 3 times per day at the 1st week. There was progressive increase in walking slowly with the time. Sutures were removed on 3rd week. Ambulant with Barouk shoes until 6 weeks. Customized insoles were made on the 7th week.



2nd group

Patients in the PRGF group had the earlier relief from pain, edema and increased walking ability compared to the 1st group. The sutures were removed on 15-17 days. Patients used Barouk shoes until 4 weeks and customized insoles were made on 5th week.

There were no local or superficial infections, allergic reactions, or any other complications related to intra and extra-articular PRGF infiltration during the procedure.

DISCUSSION

Platelet-derived Growth Factors obtained from autologous blood are proteins with the capacity to stimulate chondrocytes to regenerate cartilage. PRGF-treated chondrocytes showed markedly increased synthesis of proteoglycans and collagen. PRGFs is an excellent mode for growth factors (GFs), especially PDGF and TGF β . GFs released from activated platelets initiate and modulate wound healing in both soft and hard tissue [15]. A recent strategy to promote the healing cascade is to apply a concentrate

of autologous platelets obtained from plasma and containing GFs (PRGF) to the injury [12]. Its autologous nature gives it a significant advantage in tissue engineering applications which can be improved with the addition of adjuncts that increase the proliferation and differentiation of progenitor or stem cells [27]. The effectiveness of autologous bone marrow stromal cell therapy was shown in articular cartilage defect repair [10, 31], restoring knee stability and function in acute incomplete anterior cruciate ligament lesions in athletes [19]. The results obtained in a cell culture experiment devised in mesenchymal stem cells (MSCs) confirm that PRP (platelet-rich plasma) enhances MSC proliferation and suggest that PRP causes chondrogenic differentiation of MSC in vitro [27] providing a promising alternative to surgery by promoting safe and natural healing [28]. The therapeutic use of platelets in a fibrin clot has a positive influence in clinical situations requiring rapid healing [24]. It has been safely used and documented in the last 20 years in many fields, including [28]: orthopedics, sports medicine, odontology, periodontal, cosmetic medicine, plastic and cosmetic surgery and



maxillofacial surgery, amongst others. The efficacy of this treatment resides in the continuous, local release of a wide range of GFs and proteins necessary for healing in a process that imitates physiological tissue repair [11, 24].

In an experimental study in an animal model, Soler [33] reported that administration of intra-articular PRGF is effective for repair of full-thickness cartilage injuries in rabbit and reduces healing time of these injuries when compared with conventional treatments, such as chondroitin sulphate and HA.

Based on our study, at a mean follow up of 3 years, 73.3% patients had no pain or only mild pain. Seven percent patients responded as having moderate pain, and 7% patients had severe pain. Two patients had a wound breakdown, which healed with local wound care in 4 weeks. The VAS results for pain after PRGF show a higher percentage of improved patients (73.4%) than without PRGF (56%).

The AOFAS and FFI results in the PRGF group were more significant ($P < 0.0001$)

than the results in the group without PRGF ($P < 0.041$). The average post-operative AOFAS score was 67.82 (range: 32 to 82), and the mean post-operative Foot Function Index (FFI) was 0.51 (range: 0.23 to 0.63) in PRGF group.

In the radiological assessment, ninety percent of feet (162/180) had evidence of good outcome. At the time of most recent follow-up the Hallux valgus angle (HVA) was corrected from a mean of 30° (pre-operative) to 15° (post-operative), 1st inter-metatarsal angle (IMA) was corrected from a mean of 15° (pre-operative) to 8° (post-operative) and 4-5 IMA was corrected from a mean of 11° (pre-operative) to 7° (post-operative) in both groups. Four feet had non-union of the Scarf osteotomy and three among them were re-operated.

On X-ray examination there was a significant difference in the PRGF group. A regular follow-up radiographs in our study depicts that periosteal corn appeared after 6 weeks. After 3 months, the formation of a much larger periosteal callus of a cloud-like structure was observed. After 6 months, the



consolidation of fragments was determined on radiographs. After 1 year, bone fusion occurred on radiographs of both groups. But in cases of PRGF, a decrease in the size of the muff-like bone callus occurred along with the disappearance of the osteotomy line. After 2 years, the complete reverse development of the callus is completed.

Intra-articular infiltration of autologous PRGF was well tolerated over the entire study period. The only secondary effects were local and infrequent at the injection site. A systematic review of 20 clinical trials investigating the efficacy and safety of PRGF in healing and regenerating hard and soft tissue in medical and surgical procedures concluded that there were no complications related to the use of PRGF [26]. Safety is provided by the anti-bactericidal secretion of proteins by platelets which participate directly in the elimination of bacteria during sepsis. Platelets ability to reduce pain is due to a suppression of the inflammatory phase and a relatively low level of interleukins [14, 24]. It has been reported that the cells remain phenotypically stable in the presence of PRGF [2]. The safety of PRGF and the low incidence of

adverse effects [28] make it an appropriate treatment for patients with forefoot deformities, particularly the elderly, those intolerant to NSAIDs and those in whom NSAIDs are contraindicated. It could also be used to treat other joints, although the effect and outcome of this approach on the evolution of forefoot should be investigated.

The search for safe and effective therapeutic and co-adjuvant treatment for such a common condition generates considerable interest; PRGF application has been showing promising results [25]. This study shows that intra-operative infiltration of PRGF in forefoot according to the established protocol is safe, tolerable and effective, resulting in a reduction in pain at short term. The mean interval between the two questionnaires was 191 days (range 160–200). It is not surprising that the reduction in pain was associated with a functional improvement, as documented with the AOFAS and FFI.

PRGF could balance angiogenesis and restore HA concentration in the joint [13]. The PRGF technique uses platelets as



bearers of GFs and other proteins that are important for bone biology. The release of these proteins from the platelet alpha granules, and the concentration and deposit at the site of injury can be controlled. Thus, the lesion is exposed to a physiologic concentration of proteins that accelerates and favors the process of repair and regeneration [11].

Thus, we can say that intraoperative infiltration of autologous PRGF seems to be a safe, effective treatment for forefoot deformity, with no associated systemic complications.

CONCLUSIONS

A 3 year follow-up illustrates compelling prolonged outcomes after the surgery. The results obtained indicate that infiltration of autologous PRGF during forefoot reconstruction surgery has local, effective and temporal effects reducing pain and restoring function, without provoking local or systemic adverse events. Better radiological outcomes are reported in the PRGF group. The simplicity of PRGF use

makes it an attractive option for surgeons and researchers. PRGF had a solid stimulatory effect on cell viability and proliferation. Overall, more than 80% of the patients remained satisfied with the outcome. Thus, PRGF favors the surgical treatment by minimizing the rehabilitation period, postoperative pain, and edema and enhances better cosmesis. Nonetheless, further study and clinical trials are needed to confirm the results observed.

ETHICAL CLEARANCE: All patients were given written informed consent. No animal experiments were done.

ACKNOWLEDGEMENTS

All authors have contributed in manuscript writing and hold full responsibility for the content mentioned.

CONFLICTS OF INTEREST AND SOURCE OF FUNDING: No conflicts were declared. **DISCLOSURE OF FUNDING:** No funding received for this work from any organizations.



REFERENCES

1. Glazebrook M, et al. Proximal opening wedge osteotomy with wedge-plate fixation compared with proximal chevron osteotomy for the treatment of hallux valgus: a prospective, randomized study. *J Bone Joint Surg Am.* 2014;96(19):1585–1592. doi: 10.2106/JBJS.M.00231.
2. Akeda K, An H, Okuma M, Attawia M, Miyamoto K, Thonar EJ- MA, Lenz M, Sah R, Masuda K (2006) Platelet-rich plasma stimulates porcine articular chondrocyte proliferation and matrix biosynthesis. *Osteoarthritis Cartilage* 14(12):1272–1280
3. Barouk LS. Scarf osteotomy for hallux valgus correction. Local anatomy, surgical technique, and combination with other forefoot procedures. *Foot Ankle Clin.* 2000;5(3):525–558.
4. Weil LS. Scarf osteotomy for correction of hallux valgus. Historical perspective, surgical technique, and results. *Foot Ankle Clin.* 2000;5(3):559–580.
5. Hrubina M, et al. The modified scarf osteotomy in the treatment of tailor's bunion: midterm follow-up. *Acta Orthop Belg.* 2015;81(1):57–64.
6. Murawski CD, Egan CJ, Kennedy JG. A rotational scarf osteotomy decreases troughing when treating hallux valgus. *Clin Orthop Relat Res.* 2011;469(3):847–853. doi: 10.1007/s11999-010-1647-3.
7. Bock P, et al. The scarf osteotomy with minimally invasive lateral release for treatment of hallux Valgus deformity: intermediate and long-term results. *J Bone Joint Surg Am.* 2015;97(15):1238–1245. doi: 10.2106/JBJS.N.00971.
8. Saegusa AW, et al. Infiltration of plasma rich in growth factors for osteoarthritis of the knee short-term effects on function and quality of life. *Archives of Orthopaedic and Trauma Sur;* 43 2010;131:311–317. doi.org/10.1007/s00402-010-1167-3
9. Seijas R et al. Arthroscopic Treatment and Injection of Plasma Rich in Growth Factors in the Treatment Femoroacetabular Impingement of the Hip: Results with Two Years of Follow-up. *Int Journal of Orthopaedics* 2015;2(1): 182-187. doi:10.6051/j.issn.2311-5106.2015.02.45-1
10. Agung M, Ochi M, Yanada S, Adachi N, Izuta Y, Yamasaki T, Toda K (2006) Mobilization of bone marrow-derived



mesenchymal stem cells into the injured tissues after intraarticular injection and their contribution to tissue regeneration. *Knee Surg Sports Traumatol Arthrosc* 14(12):1307–1314

11. Anitua E (2000) Un nuevo enfoque en la regeneración ósea. Plasma rico en factores de crecimiento (PRGF). SL, Vitoria, Ed. Puesta al día publicaciones

12. Eppley BL, Woodell JE, Higgins J (2004) Platelet quantification and growth factor analysis from platelet-rich plasma: implications for wound healing. *Plast Reconstr Surg* 114:1502–1508

13. Anitua E, Sanchez M, Nurden AT, Zalduendo MM, de la Fuente M, Azofra J, Andia I (2007) Platelet-released growth factors enhance the secretion of hyaluronic acid and induce hepatocyte growth factor production by synovial fibroblasts from arthritic patients. *Rheumatology (Oxford)*. doi:10.1093/rheumatology/kem234

14. Frei R, Biosca FE, Handl M, Trc T (2008) Conservative treatment using plasma rich in growth factors (PRGF) for injury to the ligamentous complex of the ankle. *Acta Chir Orthop Traumatol Cech* 75(1):28–33

15. Cugat R, Carrillo JM, Serra I, Soler C

(2006) Articular cartilage defects reconstruction by plasma rich growth factors. In: Anonymous. Basic science, clinical repair and reconstruction of articular cartilage defects: current status and prospects. *Timeo*, pp 801–807

16. Kon E, Filardo G, Di Martino A, Marcacci M. Platelet-rich plasma (PRP) to treat sports injuries: evidence to support its use. *Knee Surg Sports Traumatol Arthrosc* 2011 Apr; 19(4): 516-527

17. Wang-Saegusa A, Cugat R, Ares O, Seijas R, Cuscó X, GarciaBalletbó M. Infiltration of plasma rich in growth factors for osteoarthritis of the knee short-term effects on function and quality of life. *Arch Orthop Trauma Surg* 2011 Mar; 131(3): 311-317

18. Vaquerizo V, Plasencia MA, Arribas I, Seijas R, Padilla S, Orive G, Anitua E. Comparison of intra-articular injections of plasma rich in growth factor (PRGF-Endoret) versus Dolorane hyaluronic acid in the treatment of patients with symptomatic osteoarthritis: a randomized controlled trial. *Arthroscopy* 2013; 29(10): 1635-1643

19. Gobbi A, Bathan L, Boldrini L (2009) Primary repair combined with bone marrow



stimulation in acute anterior cruciate ligament lesions: results in a group of athletes. *Am J Sports Med* 37:571–578

20. Diegelmann RF, Evans MC. Wound healing: an overview of acute, fibrotic and delayed healing. *Front Biosci.* 2004 Jan 1;9:283-9.

21. Garg AK. The use of platelet-rich plasma to enhance the success of bone grafts around dental implants. *Dent Implantol Update.* 2000 Mar;11(3):17-21.

22. Anitua E, Sánchez M, Orive G, Andia I. Delivering growth factors for therapeutics. *Trends Pharmacol Sci.* 2008 Jan;29(1):37-41.

23. Anitua E, Sánchez M, Orive G, Andía I. The potential impact of the plasma rich in growth factors (PRGF) in different medical fields. *Biomaterials.* 2007 Nov;28(31):4551-60.

24. Nurden AT, Nurden P, Sanchez M, Andia I, Anitua E (2008) Platelets and wound healing. *Front Biosci* 13:3532–3548

25. Lopez-Vidriero E, Goulding KA, Simon DA, Sanchez M, Johnson DH (2010) The use of platelet-rich plasma in arthroscopy and sports medicine: optimizing the healing environment. *Arthroscopy* 26(2):269–278

26. Martinez-Zapata MJ, Marti-Carvajal A, Sola I, Bolibar I, Angel Exposito J, Rodriguez L, Garcia J (2009) Efficacy and safety of the use of autologous plasma rich in platelets for tissue regeneration: a systematic review. *Transfusion* 49:44–56

27. Mishra A, Tummala P, King A, Lee B, Kraus M, Tse V, Jacobs CR (2009) BuVered platelet-rich plasma enhances mesenchymal stem cell proliferation and chondrogenic differentiation. *Tissue Eng Part C Methods* 15(3):431–435

28. Sampson S, Gerhardt M, Mandelbaum B (2008) Platelet rich plasma injection grafts for musculoskeletal injuries: a review. *Curr Rev Musculoskelet Med* 1:165–174

29. Anitua E. Plasma rich in growth factors: preliminary results of use in the preparation of sites for implants. *Int J Oral Maxillofac Implants.* 1999 Jul-Aug;14(4):529-35.

30. Soler MC (2006) Macroscópico, histológico e inmunohistoquímico del efecto del plasma rico en plaquetas autólogo en la reparación de defectos condrales en conejo. Estudio experimental. Thesis Doctoral

31. Wakitani S, Mitsuoka T, Nakamura N,



Toritsuka Y, Nakamura Y, Horibe S (2004)
Autologous bone marrow stromal cell
transplan- tation for repair of full-thickness
articular cartilage defects in hu- man patellae:
two case reports. Cell Transplant 13:595–600