

IMPORTANCE OF THE USE OF PRE- AND INTRA-OPERATIVE IMAGING AS A TOOL FOR PLANNING FOREIGN BODY REMOVAL IN THE FLOOR OF THE MOUTH: A CASE REPORT.

Importancia del uso de la imagenología pre e intraoperatoria como herramienta para la planificación de remoción de cuerpo extraño en piso de boca. Presentación de un Caso.

Veronica Viloría.¹
Carlos Millán-Golindano.¹
Josmar García.¹
Laura Molina.¹
Jose Gregorio Melillo.^{2,3}
Ramses Palma.⁴

AFFILIATIONS:

¹Hospital General del Oeste. Caracas, Venezuela.

²Universidad de Buenos Aires, Argentina.

³School Hospital Militar Dr Carlos Arvelo. Caracas, Venezuela.

⁴Universidad de Chile. Santiago, Chile.

CORRESPONDING AUTHOR:

Carlos Millán-Golindano. Hospital Militar "Dr. Carlos Arvelo". Avenida José Ángel Lamas, Urbanización San Martín, Municipio Libertador Caracas, Venezuela. **Phone:** (56-9) 47591573. **E-mail:** millanmaxilofacial@gmail.com

CITE AS:

Viloría V, Millán-Golindano, García J, Molina L, Melillo JG & Palma R.

Importance of the use of pre- and intra-operative imaging as a tool for planning foreign body removal in the floor of the mouth: A Case Report.

J Oral Res.2022;11(2):1-7.

doi:10.17126/joralres.2022.015

ABSTRACT:

Introduction: Body piercings consist of small holes made with a needle in different parts of the skin or body to introduce a jewel or decorative element. In the oral cavity, most piercings are placed in the tongue. However, some complications may occur, and surgical techniques must be used for their removal. These complications present a certain degree of difficulty due to their position and may challenge the ability of the clinician to access the specific anatomical location. The different imaging techniques, from simple radiography to intraoperative techniques such as image intensifiers, have become an extremely useful tool for locating an object in the three dimensions of space, allowing safe location and extraction.

Objective: The aim of this study is to report the case of a complication of a body piercing in the oral cavity and how the use of imaging was decisive for surgical planning and for the quick and effective resolution of the case.

Material and Methods: A 14-year-old female patient came looking for treatment. Her mother reported the onset of the condition after the insertion of a needle-like metallic object while performing an artistic perforation in the lingual region. Since the girl was unable to extract the object, she sought medical advice at the Carlos Arvelo Military Hospital in Caracas, Venezuela. Subsequently, an imaging study was performed by means of a Computed Tomography to locate the metallic object. It was observed that the foreign body had migrated to the floor of the mouth/sublingual region, requiring the area to be surgically approached. It was also decided to use an intraoperative image intensifier. The removal of the object was performed satisfactorily.

Conclusion: The extraction of foreign bodies placed in the lingual and sublingual region represents a challenge for the clinician due to the number of important anatomical structures that pass through that area. This makes clinicians plan their surgical removal using pre- and intraoperative imaging, to find a less traumatic location, reduce surgical time as well as the risk of damaging adjacent anatomical structures.

KEYWORDS:

Tongue; mouth floor; foreign bodies; tomography; radiographic magnification; body piercing.

RESUMEN:

Introducción: Los body piercings consisten en producir perforaciones con una aguja en diferentes localizaciones de la piel con el fin de introducir una joya o elemento decorativo a través del agujero producido previamente. En la cavidad oral, la lengua es el sitio de mayor elección; sin embargo, en ciertas ocasiones suelen presentarse ciertas complicaciones, por lo cual se debe recurrir a técnicas quirúrgicas para su remoción presentando cierto grado de dificultad para su localización y la capacidad del clínico para acceder al espacio anatómico. Las diferentes técnicas imagenológicas desde una radiografía simple hasta técnicas intraoperatorias como los intensificadores de imágenes se han convertido en una herramienta sumamente útil para la ubicación de un objeto en las tres dimensiones del espacio, permitiendo una localización y extracción segura para el clínico y el paciente.

Objetivo: El propósito de este trabajo es reportar un caso de una complicación de esta práctica en la región bucal y cómo el uso de la imagenología fue determinante para la planificación quirúrgica y la resolución del caso de manera rápida y efectiva.

Material y Métodos: Se presenta a consulta una paciente femenina de 14 años de edad, quien madre refiere inicio de

enfermedad actual posterior a introducirse objeto metálico tipo aguja de compás con la finalidad de realizar perforación artística en región lingual, al no poder extraer dicho objeto, acude a evaluación en el Hospital Militar Carlos arvelo de Caracas; posterior se realiza estudio imagenológico tipo Tomografía Computarizada para la ubicación del objeto metálico donde se observa que el cuerpo extraño habría migrado hacia el piso de boca/región sublingual, teniendo la necesidad de abordar quirúrgicamente la zona y elegir el uso de intensificador de imagen transoperatorio para retiro del mismo el cual se dio de manera satisfactoria.

Conclusion: Los cuerpos extraños desplazados a la región lingual y sublingual representan un desafío para el clínico al momento de extraerlos, esto se debe a la cantidad de estructuras anatómicas importantes que pasan por dicha zona, lo que hace que el clínico opte en su planificación quirúrgica por el uso de imagenología pre y transoperatoria obteniendo así una localización menos traumática, menor tiempo operatorio y menor riesgo de lesión de estructuras anatómicas adyacentes.

PALABRAS CLAVE:

Lengua; suelo de la boca; cuerpos extraños; tomografía; magnificación radiográfica; perforación del cuerpo.

INTRODUCTION.

Body piercings consist of small holes made with a needle in different parts of the body to introduce a jewel or decorative element.^{1,2}

It has been estimated that the frequency of complications related to this practice ranges between 10 and 30%. Most of them are mild and temporary, while serious complications occur in less than 1% of cases.¹⁻³ The main complications in the oral cavity include: infections (due to colonization by multiple bacterial species); hemorrhages, due to the vascularity of the area, and migrations to neighboring anatomical spaces. The latter require surgical techniques, which may present a certain degree of difficulty and challenge the ability of the clinician to

access the anatomical place of interest.¹⁻⁴

Clinicians try not to remove objects found in the tissues without visual support, as knowing their exact location is essential. The different imaging techniques, from simple radiographies to intraoperative techniques such as image intensifiers, have become an extremely useful tool for locating and observing an object in the three dimensions of space.⁴⁻⁶

Intraoperative images can be of great help in the location of foreign bodies in the maxillofacial region, so that surgical intervention can be minimized, allowing safe and successful removal of foreign bodies.^{4,6,7} The following is a case in which different imaging techniques were used to locate a metallic object in the lingual floor and their importance for its removal.

Figure 1. Computerized tomography with window for hard tissues in coronal, sagittal and axial sections showing a radiopaque image compatible with a foreign body in the floor of the mouth.

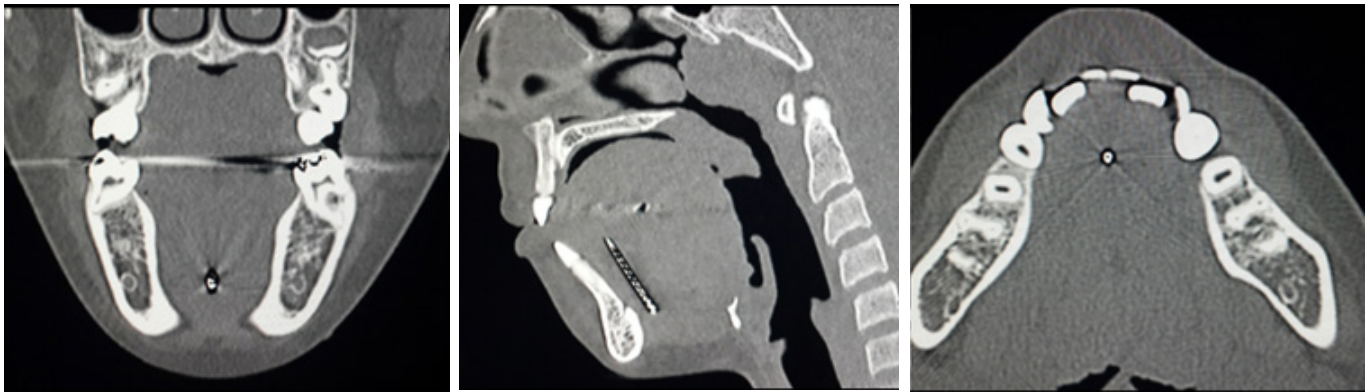


Figure 2. Intraoperative imaging with image intensifier; three plates were taken.

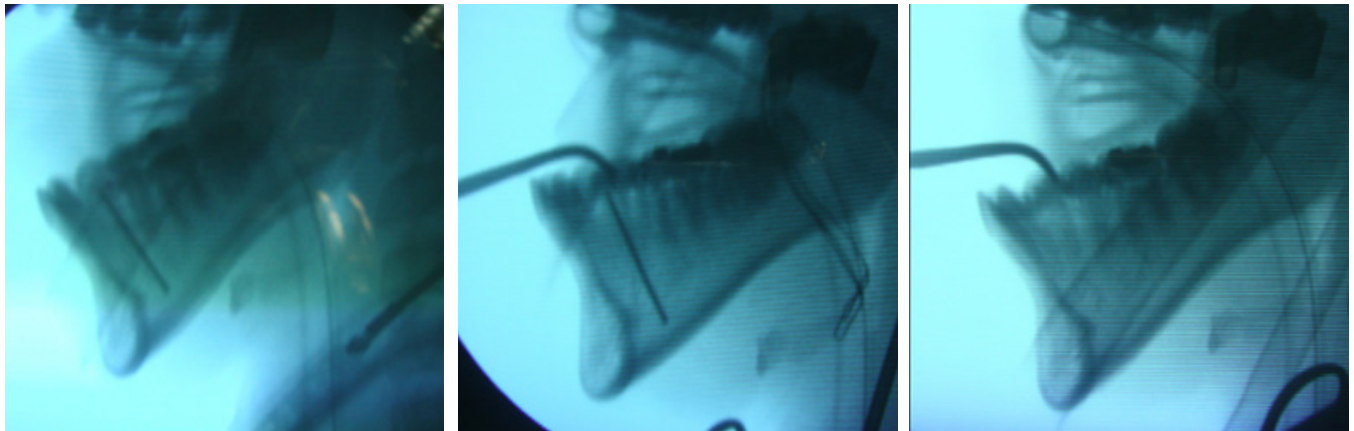
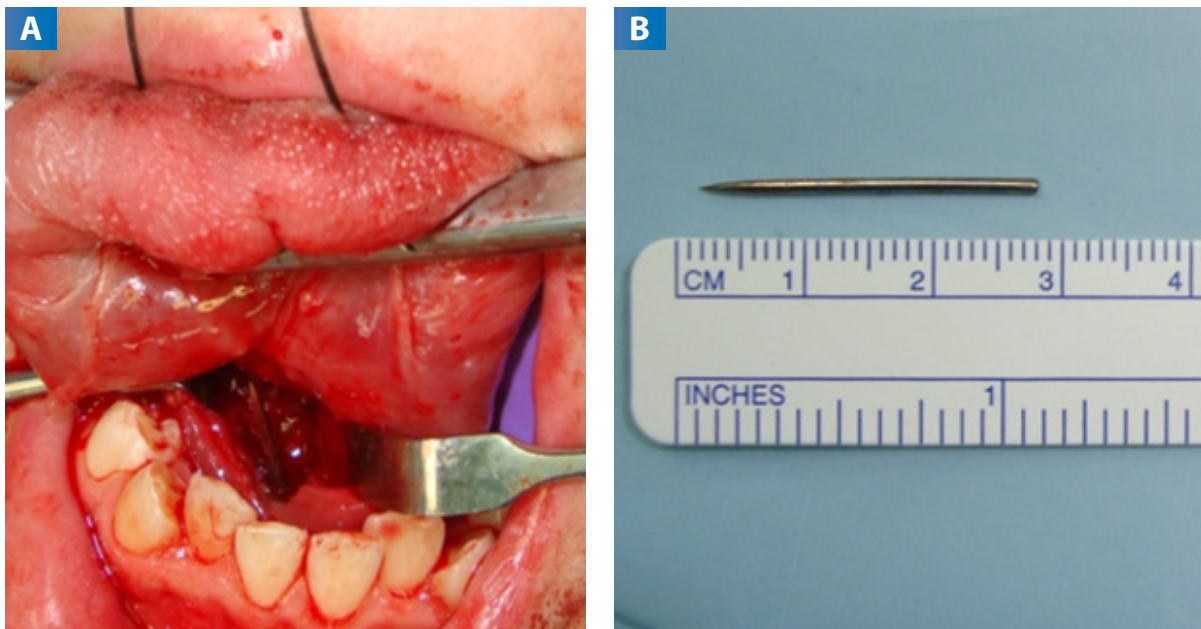


Figure 3. Surgical procedure for foreign body removal.



A: Intraoperative view of the foreign body in the floor of the mouth. **B:** Foreign body after it was removed.

CASE REPORT.

A 14-year-old female patient, with no known medical history, whose mother reported the onset of the condition 48 hours prior to going to the Maxillofacial Surgery service at the Dr. Carlos Arvelo Military Hospital. The patient reported the presence of a metallic object (compass needle) inside her lingual musculature, after trying to perform an artistic piercing at home.

Clinical examination showed a slight volume increase in the floor of the mouth without signs of phlogosis. Upon palpation, there was no evidence of the presence of the described object. Consequently, a computed tomography using axial, coronal, and sagittal slices was performed, which showed a hyperdense image compatible with a foreign body located in the floor of the mouth in a cephalocaudal position (Figure 1).

Due to its location and adjacent anatomical structures, the decision to perform surgery on the patient under general anesthesia was made, and to complement the surgical procedure with the use of an image intensifier to assess the location of the foreign body and thus reduce surgical time. A first image was taken with the image intensifier in a latero-lateral position and a linear incision was made on the floor of the mouth.

A blunt dissection was performed in a caudal position and a second image was taken to observe the position of the surgical instrument with respect to the object; the direction of the instrument was confirmed (Figure 2).

The blunt dissection continued until the object was reached and removed. Tissue integrity was performed by planes, and the surgical procedure was completed satisfactorily (Figure 3).

DISCUSSION.

The removal of many foreign bodies may seem easy at first, but clinicians and surgeons must always evaluate many factors such as location, adjacent anatomical structures, size, and shape of the object. Locating foreign bodies in the oral region is difficult when complementary studies such as imaging from

simple radiographs, computed tomography, or other intraoperative methods such as image intensifiers, are not performed.

Such imaging studies help to clarify the type of treatment that the patient should receive and offer the clinician advantages such as reduction of surgical time and decrease in the risk of infection.^{4,8-10}

The electronic image intensifier systems used in radiology are an essential tool. They are also widely used in other specialties. Likewise, although they offer many benefits, radiation must be used sensibly as it may have harmful effects when used at high doses or repeatedly. Precautions must be taken prior to performing the intraoperative procedure, such as the type of protection for the medical staff, the use of trained personnel to operate the device, as well as the additional costs involved.

In the case of a radiopaque object, it is essential to have an image intensifier to locate the foreign body during surgery.

If it is a radiolucent foreign body, it is more advisable to locate it through clinical examination since these tend to form granulomas.⁹

In the presented case, the patient reported having the sharp object placed in the dorsal portion of the tongue. At the time of palpation, the presence of the object was not evidenced neither in the tongue nor in the adjacent areas. Hence it was decided to perform a computed tomography of the involved region, through which it was possible to observe that the foreign body was in the floor of the mouth.

This finding changed the type of treatment that would be performed on the patient. The use of an image intensifier intraoperatively was required to locate the foreign body more accurately, to reduce surgical time and avoid excessive manipulation of adjacent tissues.¹¹⁻¹⁴

CONCLUSION.

A foreign body is any external object that enters the body, either through the skin or through any natural orifice such as the eyes, nose, and throat, preventing its normal functioning. In some cases, foreign bodies are not easy to detect if a deep

exploration of the wound and a radiographic study are not performed.

The extraction of foreign bodies located in the lingual and sublingual regions poses a challenge for the clinician. This is due to the number of important anatomical structures that pass through those areas as well as the possible complications that could arise such as edema of the floor of the mouth, hemorrhage, related nerve injuries, which prompt the clinician to opt for the use of imaging tools to carry out better surgical planning, to find a less traumatic location, to reduce surgical time and the risk of damaging adjacent anatomical structures.

Conflict of interests:

There are no financial links or conflicts of interest on the part of all authors.

Ethics approval:

Informed consent from the patient's legal guardian was obtained.

Funding:

self financed.

Authors' contributions:

Viloria V: Investigation: Writing - Review / Editing, Methodology

Millan C: Investigation: Writing - Review / Editing

Garcia J: Investigation: Writing - Review / Editing

Molina L: Investigation: Writing - Review / Editing

Melillo JG: Investigation: Writing - original draft

Palma R: Methodology, Writing: Review / Editing.

Acknowledgements:

None.

REFERENCES.

1. Takaoka K, Hashitani S, Toyohara Y, Noguchi K, Urade M. Migration of a foreign body (staple) from the oral floor to the submandibular space: case report. *Br J Oral Maxillofac Surg.* 2010;48(2):145-146. doi: 10.1016/j.bjoms.2009.04.022. PMID: 19467745.
2. Shehata E, Moussa K, Al-Gorashi A. A foreign body in the floor of the mouth. *Saudi Dent J.* 2010; 22(3):141–143. doi.org/10.1016/j.sdentj.2010.04.008
3. Pérez-Cotapos S María Luisa, Cossio T María Laura. Tatuajes y perforaciones en adolescentes. *Rev Méd Chile.* 2006; 134: 1322-9.
4. Ferrer AL, Sanz LP. Piercings y tatuajes: implicaciones para la salud dermatológica. *Farmacia profesional.* 2009;23(3):46-9.
5. Pujalte BF, Fornes PDF, Talamante CS. Complicaciones y cuidados de los piercings y los tatuajes (1ª parte). *Enfermería Dermatológica.* 2011; 13-14 (2011): 22-28.
6. Pujalte, Begoña Fornes, Paula Díez Fornes, and Concepción Sierra Talamantes. Complicaciones y cuidados de los piercings y los tatuajes (2ª parte). *Enfermería Dermatológica* 6.15 (2012): 8-14.
7. Paltas Miranda ME, Taipicaña Guano PV, Andrade Peñafiel AL, Haye Biazevic MG. Cuerpo extraño en región de tercer molar inferior: reporte de caso. *Rev. Odontol.* 22.2 (2020): 108-118. doi: 10.29166/odontologia.vol22.n2.2020-108-118
8. Moore UJ, Fanibunda K, Gross MJ. The use of a metal detector for localisation of a metallic foreign body in the floor of the mouth. *Br J Oral Maxillofac Surg.* 1993;31(3):191-2. doi: 10.1016/0266-4356(93)90125-g. PMID: 8512917.
9. Moreno Daza GA, Dávila Solórzano LB, Moreno Ortega JJ, Moreno Moreno FE. Uso de intensificador de imágenes en extracción de cuerpos extraños radiopacos en traumatología. *RECIMUNDO.* 2022;2(3):500-9.
10. Geary PM. Removal of foreign bodies using hydrostatic pressure. *Br J Plast Surg.* 2005;58(7):1033-5. doi: 10.1016/j.bjps.2005.05.004. PMID: 16055102.
11. Holmes PJ, Miller JR, Gutta R, Louis PJ. Intraoperative imaging techniques: a guide to retrieval of foreign bodies. *Oral Surg Oral Med Oral Pathol Oral Radiol Endod.* 2005;100(5):614-8. doi: 10.1016/j.tripleo.2005.02.072. PMID: 16243249.
12. Gans BJ, Kallal RH, Helgerson AC, Verona SR. The image intensifier in oral and maxillofacial surgery. *J Oral Maxillofac Surg.* 1982;40(11):726-9. doi: 10.1016/0278-2391(82)90146-x. PMID: 6957560.
13. Shehata E, Moussa K, Al-Gorashi A. A foreign body in the floor of the mouth. *Saudi Dent J.* 2010 Jul;22(3):141-3. doi: 10.1016/j.sdentj.2010.04.008. PMID: 23960490; PMCID: PMC3723269.