

IMPACT OF DENTAL CONE-BEAM COMPUTED TOMOGRAPHY ON DIAGNOSTIC EVALUATION AND TREATMENT PLAN FOR THE MAXILLARY SINUS IN DENTAL IMPLANT PLANNING.

Impacto de la tomografía computarizada de haz cónico en el diagnóstico y plan de tratamiento preimplantológico de senos maxilares.

Lucia Barba.^{1,2}
Vilma Ruiz.³
Alejandro Hidalgo.⁴

AFFILIATIONS:

¹Postgraduate Academic Department of Stomatology, Universidad Peruana Cayetano Heredia, Lima, Perú.

²Department of Oral and Maxillofacial Radiology, Faculty of Dentistry, Universidad de Costa Rica, Costa Rica.

³Department of Stomatology, Faculty of Dentistry, Universidad Peruana Cayetano Heredia, Lima, Perú.

⁴Department of Stomatology, Faculty of Health Sciences, School of Dentistry, Universidad de Talca, Talca, Chile.

CORRESPONDING AUTHOR:

Alejandro Hidalgo. Universidad de Talca. Avenida Lircay s/n, Talca, Chile. **Phone:** (56-71) 2200476. **E-mail:** ahidalgo@utalca.cl

CITE AS:

Barba L, Ruiz V & Hidalgo A.
Impact of dental Cone-Beam computed tomography on diagnostic evaluation and treatment plan for the maxillary sinus in dental implant planning.
J Oral Res.2022;11(1):1-13.
[doi:10.17126/joralres.2022.003](https://doi.org/10.17126/joralres.2022.003)

ABSTRACT:

Objective: To determine the impact of CBCT on diagnostic evaluation and treatment plan for the maxillary sinus in dental implant planning.

Material and Methods: Diagnostic evaluation and treatment plan for the maxillary sinus were evaluated by eight specialists experienced in dental implant placement. Eight panoramic radiographs (PAN) and CBCT examinations were obtained from five adult patients with a specific clinical need for dental implants. Evaluation was performed first on PAN then, at least 2 weeks later, on CBCT. Residual alveolar ridge height, mucosal thickening, radiographic findings and treatment plan were recorded. The confidence level was evaluated for both diagnostic evaluation and treatment plan. The kappa statistic for intra-observer reproducibility and McNemar test were performed.

Results: In the diagnostic evaluation, CBCT showed significant impact on the diagnosis of radiographic findings. Availability of CBCT significantly changed the treatment plan, for less invasive treatment, or no treatment need. Observers had significantly greater confidence when using CBCT than PAN, when indicating presence of mucosal thickening and radiographic findings in the maxillary sinus. In addition, CBCT increased confidence in the treatment plan.

Conclusion: The present study suggests that CBCT has an impact on the diagnostic evaluation of radiographic findings in the maxillary sinus and on the decision to place implants, owing to misdiagnosis of pathology and planning of more invasive treatments when using PAN. Availability of CBCT also improves clinician confidence. Further studies at higher levels of diagnostic efficacy should be performed, to justify the use of CBCT, by evaluating the actual treatment performed and its outcome.

KEYWORDS:

Radiography, Panoramic; Cone-Beam Computed Tomography; Maxillary sinus; Dental implants; Alveolar Process; Diagnostic imaging.

Received: 06 May 2021 | Accepted: 07 November 2021 | Published online: 28 January 2022

RESUMEN:

Objetivo: Determinar el impacto de la tomografía computarizada de haz cónico (CBCT) en la evaluación diagnóstica y el plan de tratamiento del seno maxilar en la planificación de implantes dentales.

Material y Métodos: La evaluación diagnóstica y el plan de tratamiento del seno maxilar fueron evaluados por ocho especialistas con experiencia en la colocación de implantes dentales. Se obtuvieron ocho radiografías panorámicas (PAN) y exámenes CBCT de cinco pacientes adultos con una necesidad clínica específica de implantes dentales. La evaluación se realizó primero en PAN y luego, al menos dos semanas después, en CBCT. Se registraron la altura del reborde alveolar residual, el engrosamiento de la mucosa, los hallazgos radiográficos y el plan de tratamiento. Se evaluó el nivel de confianza tanto para la evaluación diagnóstica como para el plan de tratamiento. Se realizó el estadístico kappa para la reproducibilidad intraobservador y la prueba de McNemar.

Resultados: En la evaluación diagnóstica, CBCT mostró un impacto significativo en el diagnóstico de los hallazgos

radiográficos. La disponibilidad de CBCT cambió significativamente el plan de tratamiento, para un tratamiento menos invasivo o sin necesidad de tratamiento. Los observadores tuvieron una confianza significativamente mayor al usar CBCT que PAN, al indicar la presencia de engrosamiento de la mucosa y hallazgos radiográficos en el seno maxilar. Además, CBCT aumentó la confianza en el plan de tratamiento.

Conclusión: El presente estudio sugiere que la CBCT tiene un impacto en la evaluación diagnóstica de los hallazgos radiográficos en el seno maxilar y en la decisión de colocar implantes, debido al diagnóstico erróneo de la patología y la planificación de tratamientos más invasivos al usar PAN. La disponibilidad de CBCT también mejora la confianza del clínico. Se deben realizar más estudios a niveles más altos de eficacia diagnóstica para justificar el uso de CBCT, evaluando el tratamiento real realizado y su resultado.

PALABRAS CLAVE:

Radiografía panorámica; Tomografía Computarizada de haz cónico; Seno maxilar; Implantes dentales; Proceso alveolar; Diagnóstico por imagen.

INTRODUCTION.

Radiographic evaluation for dental implant planning requires images for diagnostic evaluation and treatment planning, to achieve successful dental implant treatment.¹ Within radiographic evaluation, establishing morphologic characteristics and orientation of the residual alveolar ridge is needed. This information is valuable for matching the amount of bone volume available with the dimensions of the implant, and to detect deviations that could jeopardize the prosthetic plan.² Also, evaluation of the maxillary sinus (MS) allows the identification of anatomical conditions and possible pathologies.³ It is important to determine a correct diagnosis and treatment of MS conditions,⁴ since these conditions may influence implant planning,⁵ prevent or allow the placement of implants, or cause postoperative complications.⁴

Traditionally, information for dental implant planning

has been obtained from conventional radiographs, including Panoramic Radiographs (PAN).

PAN is the most used conventional two-dimensional (2D) image for evaluation of the maxillofacial complex,⁶ being used in evaluation of the MS.^{7,8} PAN allows visualization of both dental arches, is easy to access and has a low economical cost.⁹

However, PAN has limitations, such as magnification and geometric distortion, which produce inaccurate images of anatomical structures, as well as inaccurate and unreliable measurement accuracy.^{6,9}

Another limitation of PAN is the superimposition of structures, which complicates evaluation of the MS and identification of pathologies, which can lead to erroneous diagnoses.^{6,9}

Cone-beam computed tomography (CBCT) is a technology that allows the acquisition of images in three dimensions (3D),¹ which overcomes the limitations of

PAN, providing information for a reliable diagnosis of the MS.^{6,7,10} However, radiation dose is usually higher in CBCT than in PAN.¹ Although CBCT is a relatively recent technology in dentistry, it has achieved acceptance because of the benefits of its use.¹¹ Due to the limitations of PAN in the diagnostic evaluation of the MS for dental implant planning, it is tempting to change from a conventional 2D study to the 3D study. However, this change should be performed only if the new 3D technology proves to be more effective than the conventional one.¹²

Fryback *et al.*,¹² proposed that diagnostic imaging should be evaluated at six levels of diagnostic efficacy:

- 1) Technical efficacy;
- 2) Diagnostic accuracy efficacy;
- 3) Diagnostic thinking efficacy;
- 4) Therapeutic efficacy;
- 5) Patient outcome efficacy and
- 6) Societal efficacy.

This model of diagnostic efficacy indicates that imaging technologies/techniques should be evaluated according to the impact on the decision-making process and patient management, rather than only evaluating the image, due to image quality and diagnostic accuracy, which has been the traditional approach.

Several investigations at the lower diagnostic efficacy levels have demonstrated a greater technical efficacy and greater diagnostic accuracy efficacy for CBCT compared with PAN when evaluating MS pathology and detecting MS septa.^{6,10} However, research at these lower levels may not have a direct impact on clinical decisions, such as diagnosis and treatment, which can be obtained from research at level 3 and level 4 of the model.¹² Few studies have evaluated the efficacy of CBCT in diagnosis of the MS in dental implant planning, at levels 3 and 4, and none of them have yet evaluated the treatment of MS conditions.^{13,14}

Despite lack of scientific evidence, different organizations have published recommendations and position papers not evidence-based. Therefore, there is no consensus on the use of CBCT in the preimplantological evaluation of MS.¹⁵

Since dental implant planning is one of the most

common indications of CBCT,^{16,17} evidence-based recommendations on its use for this purpose are needed. However, to our knowledge, there have been no previous studies evaluating CBCT at higher levels of diagnostic efficacy, that is, evaluating impact on clinical decisions. Therefore, the aim of this study was to determine the impact of CBCT on diagnostic evaluation and treatment plan for the MS in dental implant planning.

MATERIALS AND METHODS.

Ethical approval was obtained from the Committee of the Universidad Peruana Cayetano Heredia (#001-02-19). This was a “before–after” study, with ten observers recruited, all dentists and professors from the Postgraduate School of the Faculty of Dentistry at the Universidad Peruana Cayetano Heredia. All observers were specialists in oral and maxillofacial surgery, oral implantology or periodontology, with more than five years of experience using CBCT in dental implant planning.

Consecutive patients with the specific clinical need for dental implants were used, referred from the Oral Implantology Area for PAN and CBCT examination, from May 2017 to October 2018.

The MS had to be completely observable in both radiographic examinations, and there had to be presence of edentulous spaces in premolar and/or molar area, unilaterally or bilaterally. PAN and CBCT examinations were obtained from five adult patients (two male, three female) (mean age 49.4 years, standard deviation 8.4 years). The maximum interval between both examinations was 5 weeks, during which the patient did not receive any surgical procedure in the maxilla and/or MS. Each MS was considered as an independent case; eight cases were included, with a total of 16 images, eight PAN and eight CBCT scans.

PAN had been taken using an Ortophos XG5 device (Sirona Dental Systems GmbH, Bensheim, Hessen, Germany), operated with 64–85 kV, 7 mA and 14 s exposure time. CBCT examinations had been taken using a GALILEOS Comfort scanner (Sirona Dental Systems GmbH, Bensheim, Hessen, Germany) ope-

rated at 85 kV, 7 mA and 14 s, using a 15 cm diameter field of view and 0.3 mm voxel size. All PAN and CBCT examinations were extracted from the original software and recorded in an anonymized form, on an encrypted external hard drive. All PAN images were recorded as .jpeg files.

Implementation of the “before–after” study

Each observer was assigned a code number, so that the answers could not be related to the observer. Each observer evaluated each case on two separate sessions, one for each technology, at least two weeks apart, to minimize memory bias. PAN were evaluated first and CBCT later (Figure 1).

No further histological or clinical information was given to the observers. Identification data for the patients was not available at either evaluation.

All cases were randomly ordered for each session, using <https://www.random.org/> The observers were blinded to the fact that they were evaluating the same cases in both PAN and CBCT examinations.

To determine intra-observer reproducibility, two randomly selected cases (25% of the cases), were duplicated. Therefore, observers evaluated two cases twice, in each session, included randomly among the rest of the cases. The observers were blinded about the presence of these duplicated cases.

Each observer evaluated a total of 10 cases. An eight-question online questionnaire was designed for the observers, (Table 1) (Microsoft Forms 2019, Microsoft Corporation, Redmond, WA, USA) to evaluate both PAN and CBCT.

The questionnaire included three questions related to diagnostic evaluation and one related to treatment plan for the MS. The other four questions were on confidence level, both for diagnostic evaluation and treatment plan. Observers were asked to review each case and answer each question by checking the boxes. Two questions had an “other” answer option, where the observer could select multiple options or write his/her own answer. Questions on confidence level were recorded on a five-point Likert scale.

All answers were recorded in separate PDF files (Adobe Acrobat Reader DC, Adobe Systems Incorporated, San Jose, California) for both PAN and

CBCT, for each observer.

All images were evaluated on a 21.5-inch high-resolution monitor (ThinkVision, Lenovo, Beijing, China) in a room with standardized conditions of low environmental noise and dimmed light.

PAN images were evaluated with Microsoft Office Picture Manager 2010 (Microsoft Corporation, Redmond, WA, USA) and CBCT volumes were evaluated in GALILEOS Viewer (Sirona, Bensheim, Germany).

The observers were allowed to use the image viewer and the volume viewer as they preferred, without time limits, for the evaluation of PAN and CBCT respectively.

The first author (LB) gave a verbal introduction to the observers, individually, about the study and on how to complete the questionnaire. The first author remained with each observer during the evaluation time, to resolve any question regarding the questionnaire.

Statistical analysis

STATA software (version 15.0, StataCorp, College Station, Texas, USA) was used. McNemar test was used to test the null hypothesis that there was no difference between diagnostic evaluation and treatment plan for the MS in dental implant planning before and after the evaluation using CBCT. The significance level was set at $p < 0.05$. All questionnaire answers were dichotomized to perform the statistical analyses, (Table 1).

For Question 5, regarding radiographic findings, two analyses were performed. First, the presence of the findings was recorded as a whole, including within this category the presence of any of the findings defined in the answer options. Then, the presence of each finding was recorded individually.

For Question 7, regarding MS treatment plan, two analyses were also performed. First, the need for treatment was recorded as a whole, including in this category the selection of any of the treatment options included in the answer options. Then, the selection of each treatment option was recorded individually.

Intra-observer reproducibility was assessed with the kappa statistic. The Altman scale for strength

agreement was used; only observers assessed as having good reproducibility or better (>0.61) were included in further analyses.

RESULTS.

Eight of the ten observers were finally included, since two observers had a kappa value < 0.61 . Kappa values of the observers included ranged from 0.615 to 0.908. Since answers from duplicate cases were used only to assess intra-observer reproducibility, 64 answers were included for the analyses.

Diagnostic evaluation of MS in dental implant planning before and after CBCT (Table 2).

Changes in diagnostic evaluation of MS in dental implant planning after CBCT (Table 3).

MS treatment plan in dental implant planning before and after CBCT (Table 4).

Changes in MS treatment plan in dental implant planning after CBCT (Table 5).

Confidence level for diagnostic evaluation and treatment plan for MS in dental implant planning before and after CBCT, (Table 6).

Figure 1. Sample images of panoramic radiography and cone-beam computed tomography examination from the same patient, used for evaluation.

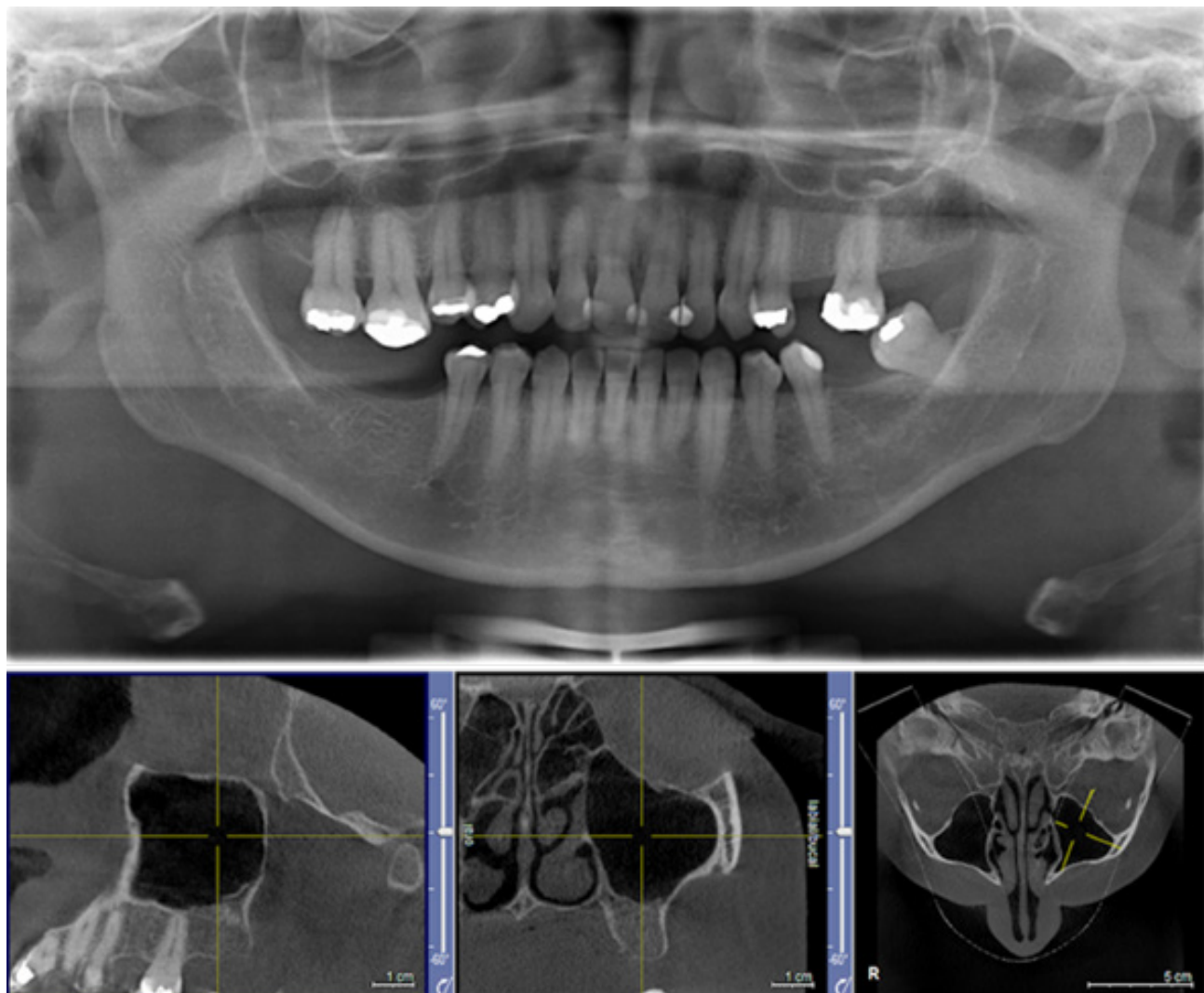


Table 1. Questionnaire with original and dichotomised options.

QUESTION	ANSWERS IN ORIGINAL QUESTIONNAIRE STATISTICAL ANALYSIS	DICHOTOMISED ANSWERS FOR
1. Height of the residual alveolar ridge is:	More than 4 mm/2-4 mm/Less than 2 mm	0. Unfavorable (4mm or less). 1. Favorable (more than 4mm).
2. Mucosal thickening is:	Less than 2 mm/2-5 mm/6-9 mm/ More than 9 mm.	0. Unfavorable (more than 5 mm). 1. Favorable (5 mm or less).
3. In relation to radiographic findings, for the maxillary sinus in the presented case: (if presence, you can select more than one option).	Absence/Presence of radiographic findings If presence: Sinus septa/Polypoid lesion/Air-fluid level/Other.	0. Absence. 1. Presence (includes all options).
4. In relation to the maxillary sinus in the presented case, you can consider for the treatment plan: (if treatment needed, you can select more than one option).	0. No treatment needed. 1. Treatment needed: If treatment needed: Sinus lifting with and without grafting procedure/Implant placement/Time of implant placement (immediately or after sinus lifting)/Refer patient to an ear, nose, throat specialist/Treatment of sinus pathology (surgical or pharmacological)/Other.	0. No treatment needed. 1. Treatment needed (includes all options).
5. Your confidence level in the previous answer is:	1. Very doubtful/unsure 2. Doubtful/unsure 3. No opinion 4. Confident 5. Very confident.	0. Not confident (includes option 1,2,3). 1. Confident (includes options 4 and 5).

Table 2. Results of diagnostic evaluation of the maxillary sinus in dental implant planning before and after the use of cone-beam computed tomography.

PARAMETERS	CATEGORIES	PANORAMIC RADIOGRAPHY		CBCT		p-value
		n	%	n	%	
Residual alveolar ridge height	Unfavorable ^a	4	6.3	0	0	0.125
	Favorable ^a	60	93.8	64	100	
Mucosal thickening in the maxillary sinus	Unfavorable ^b	10	16.7	9	14.1	1.000
	Favorable ^b	54	83.3	55	85.9	
Radiographic findings	Absence	24	37.5	37	57.8	<0.001*
	Presence	40	62.5	27	42.2	
Sinus septa	Absence	43	67.2	48	75.0	0.383
	Presence	21	32.8	16	25.0	
Polypoid lesion	Absence	60	93.8	64	100	0.125
	Presence	4	6.3	0	0	
Air-fluid level	Absence	58	90.6	60	93.8	0.754
	Presence	6	9.4	4	6.3	
Other findings	Absence	55	85.9	57	89.1	0.754
	Presence	9	14.1	7	10.9	

*: statistically significant p-value. **a:** Unfavorable for simultaneous implant placement. Favorable for simultaneous implant placement. **b:** Unfavorable for sinus lift. Favorable for sinus lift.

Table 3. Results of changes in diagnostic evaluation of the maxillary sinus in dental implant planning after the use of cone-beam computed tomography.

NUMBER OF CASES	TOTAL NUMBER OF CHANGES	NUMBER OF TIMES "ABSENCE OF RADIOGRAPHIC FINDINGS" WAS SELECTED	NUMBER OF TIMES "PRESENCE OF RADIOGRAPHIC FINDINGS" WAS SELECTED
64	25	19	6

Table 4. Results of treatment plan for the maxillary sinus in dental implant planning before and after the use of cone-beam computed tomography (CBCT).

PARAMETERS	TREATMENT PLAN	PANORAMIC RADIOGRAPHY		CBCT		p-value
		n	%	n	%	
Treatment needed	No	2	3.1	13	20.3	<0.001*
	Yes	62	96.9	51	79.7	
Sinus lift (with and without grafting procedure)	No	55	85.9	61	95.3	0.065
	Yes	9	14.1	3	4.7	
Implant placement (with or without sinus lifting)	No	4	6.3	26	40.6	<0.001*
	Yes	60	93.8	38	59.4	
Refer patient to ear, nose, throat specialist	No	49	76.6	48	75	1.000
	Yes	15	23.4	16	25	
Treatment of maxillary sinus pathology (surgical and pharmacological)	No	57	89.1	55	85.9	0.774
	Yes	7	10.9	9	14.1	
Other	No	43	67.2	52	81.3	0.064
	Yes	21	32.8	12	18.8	

*: Statistically significant p-value.

Table 5. Results of changes in maxillary sinus treatment plan in dental implant planning after the use of cone-beam computed tomography.

PARAMETERS	TOTAL NUMBER OF CHANGES	NUMBER OF TIMES	NUMBER OF TIMES
Treatment needed	15	"No treatment needed" was selected	"Treatment needed" was selected
		13	2
Implant placement	26	"No implant placement" was selected	"Implant placement" was selected
		24	2

Table 6. Results on confidence level for diagnostic evaluation and treatment plan for maxillary sinus in dental implant planning before and after the use of cone-beam computed tomography (CBCT).

PARAMETERS		PANORAMIC RADIOGRAPHY		CBCT		p-value	
		n	%	n	%		
DIAGNOSTIC EVALUATION	Residual alveolar ridge height	Not confident	4	6.3	0	0	0.125
	Confident	60	93.8	64	100		
	Mucosal thickening	Not confident	30	45.8	3	4.7	<0.001*
	Confident	34	54.2	61	95.3		
Radiographic Findings	Not confident	25	39.1	4	6.3		<0.001*
	Confident	39	60.9	60	93.8		
TREATMENT PLAN	Not confident	15	23.4	1	1.6		<0.001*
	Confident	49	76.6	64	98.4		

*: Statistically significant p-value.

DISCUSSION.

The present study aimed to determine whether CBCT has an impact on diagnostic evaluation and treatment plan for MS in dental implant planning. Few articles have studied the bone volume of the residual alveolar ridge^{14,18} and the need for sinus augmentation procedures^{8,13,14} before and after CBCT. Only one¹³ evaluated the presence of septa and mucosal thickening. However, none evaluated diagnosis and treatment of MS. This is the first study, to our best knowledge, that evaluates the impact of CBCT on treatment of MS in dental implant planning.

In a before-after study design, when the observers' assessment is the phenomenon under study, to evaluate what the test under evaluation adds to current practice, the observers are the units of analysis.¹⁹

Although there is currently no consensus on the number of observers required for this radiological study design,²⁰ an accepted criterion is that one or two independent observers are required.²¹ Therefore, the number of experienced observers used in the present study exceeds the minimum accepted and coincides with the maximum number of observers reported in similar studies.²²

The present study tried to recreate a real clinical situation in which observers evaluate the examination images. Since the aim of recreating the clinical situation is to determine the evaluation of each observer according to their own knowledge, a preliminary calibration of the observers was not performed, since this may have biased the results.²³

Diagnostic evaluation of MS in dental implant planning

The present study found a significant difference in the diagnosis of radiographic findings as a whole, with fewer radiographic findings after the availability of CBCT. PAN failed to adequately demonstrate the presence/absence of anatomic or pathologic conditions that can prevent implant placement (Table 3).

Also, when using PAN, clinicians tended to over diagnose radiographic findings (Table 2).

Previous studies have reported similar results, showing that PAN has lower efficacy in the diagnosis of MS pathology than CBCT,^{24,25} making this examination unreliable as an imaging method for treatment planning. This can be explained by inherent limitations of 2D technology,²⁴ which CBCT overcomes, allowing a detailed visualization of the

MS, anatomical structures and pathologies.⁶ Even though CBCT is not used as the gold standard for MS pathology, due to inherent characteristics of this 3D technology, better visualization of the MS in all its dimensions is expected. This may be the explanation for our results, which showed that CBCT had an impact on diagnostic evaluation of radiographic findings in MS.

Maxillary sinus treatment plan in dental implant planning

Statistically significant differences were found between technologies when analyzing “treatment need” (Table 4).

After the availability of CBCT, clinicians selected fewer cases with a “treatment need” than they did with PAN (Table 5).

This may indicate that CBCT allows clinicians to perform a more detailed evaluation that lets them change the treatment plan they had previously determined based only on PAN.

Therefore, the change in treatment plan could be from implant placement with PAN to no treatment at all with CBCT. This selection includes no previous treatment before implant placement, or implant placement itself, after the availability of CBCT. Since none of the treatment plan options was selected by the clinicians, it can be assumed that treatment need decision may be related to prosthetic planning or implant planning and not to the MS treatment plan in implant planning. In this regard, a treatment plan performed only with PAN may over-indicate the need for implant placement.

In these cases, implant placement procedures could fail, having repercussions and affecting patients, with an increase in treatment time, cost and outcome. However, these results should be analyzed cautiously. Since no clinical information was given to the observers, a lack of clinical information may have influenced their evaluation. In daily practice, clinicians have patient information available, such as clinical history and models, to analyze together with PAN. Nonetheless, CBCT, due to its 3D characteristics, is not affected as much as PAN by the lack of clinical information.

Even without clinical information, CBCT may allow to indirectly obtain some clinical information from the images, such as alveolar bone width and orientation, outweighing PAN. Hence, new investigations should evaluate dental implant planning and prosthetic planning altogether,²⁶ recreating daily practice by giving observers all the clinical information available. Also, investigations should compare results with the actual treatment performed, to evaluate the clinical outcome.

Regarding the “implant placement” option, the availability of CBCT significantly changed the treatment plan. In nearly half of cases, this change was for a less invasive treatment, such as “refer to Ear, Nose and Throat specialist” and “sinus lift”. This may be interpreted as the information obtained with CBCT allowing the clinician to take a more detailed and careful approach, taking into consideration other conditions of the MS not previously found with PAN.

This information may influence the clinician not to proceed with implant placement, thus avoiding the surgical procedure for the patient until the MS conditions found are properly treated. Therefore, clinicians who found MS pathology with the use of CBCT preferred to manage the pathology first, in order to reduce possible complications. In the other half of cases, the change of treatment was from “implant placement” with PAN, to “no treatment need” with CBCT, with the implications explained above.

Confidence level for diagnostic evaluation and treatment plan in dental implant planning

Clinicians were found to have significantly greater confidence using CBCT than with PAN, when indicating the presence of mucosal thickening and radiographic findings in the MS. Regarding mucosal thickening, although the diagnosis did not change after CBCT, this result could be interpreted as clinicians perhaps being more confident in referring patients to an Ear, Nose and Throat (ENT) specialist, as they are more confident in their diagnosis (Table 6).

It is indicated to refer those patients with mucosal thickening between 6-9mm to the ENT, because this thickening indicates inflammation or infection, due to a variety of odontogenic and non-odontogenic

pathologies. Entering the maxillary sinus in the presence of this type of active disease would lead to complications. Therefore, referral to ENT ensures that the condition is diagnosed, managed and addressed, thus reducing potential complications.

A previous study 6 also found that clinicians were more confident regarding the presence of pathology with CBCT than PAN.

This can be interpreted as the clinicians who found pathologies that could complicate their plan, are more confident with their diagnoses, being more likely to refer to ENT previous to implant treatment. On the contrary, clinicians with less confidence in their diagnosis, probably will not refer patients, since they are not sure of the presence of pathology. This greater confidence in diagnosis may lead to a more careful dental implant placement and a better outcome.

Regarding confidence in the treatment plan (Table 6), our results are in line with previous studies, 13,14 which have shown that CBCT increases confidence, while treatment planning with PAN results in a doubtful confidence level. The present study is the first to provide information that overcomes the results from previous studies by evaluating higher levels of Fryback and Thornbury's model of diagnostic efficacy.

Since evidence of efficacy at lower levels does not guarantee efficacy at higher levels, the present study gives additional evidence for the decision making process for diagnosis and treatment of the MS.

CONCLUSION.

Notwithstanding the limitations, this study suggests that CBCT has an impact on the diagnostic evaluation of radiographic findings in MS and on the decision to place implants as a treatment plan in dental implant planning.

This, owing to the misdiagnosis of pathology and the planning of more invasive treatments with the use of PAN only.

Availability of CBCT was also shown to improve clinician confidence. Further studies at higher levels of diagnostic efficacy should be performed to justify the use of CBCT, including clinical information and evaluating the actual treatment performed and its outcome.

Conflict of interests:

All authors declare that they have no conflict of interest.

Ethics approval:

Ethical approval was obtained from the Committee of the Universidad Peruana Cayetano Heredia. Authorization number #001-02-19.

Funding:

The study was self-funded by the authors.

Authors' contributions:

Barba L: Acquisition, analysis and interpretation of data for the work.

Drafting of the work, final approval of the version to be published.

Ruiz V: Revising it critically for important intellectual content and final approval of the version to be published.

Hidalgo A: Conception of the work, revising the work critically for important intellectual content. Final approval of the version to be published.

Acknowledgements:

The first author acknowledges the University of Costa Rica for funding her postgraduate studies.

REFERENCES.

1. Jacobs R, Salmon B, Codari M, Hassan B, Bornstein MM. Cone beam computed tomography in implant dentistry: recommendations for clinical use. *BMC Oral Health*. 2018 May 15;18(1):88. doi: 10.1186/s12903-018-0523-5. PMID: 29764458; PMCID: PMC5952365.
2. Sahota J, Bhatia A, Gupta M, Singh V, Soni J, Soni R. Reliability of Orthopantomography and Cone-beam Computed Tomography in Presurgical Implant Planning: A Clinical Study. *J Contemp Dent Pract*. 2017 Aug 1;18(8):665-669. doi: 10.5005/jp-journals-10024-2103. PMID: 28816186.
3. Tavelli L, Borgonovo AE, Re D, Maiorana C. Sinus presurgical evaluation: a literature review and a new classification proposal. *Minerva Stomatol*. 2017 Jun;66(3):115-131. doi: 10.23736/S0026-4970.17.04027-4. PMID: 28206730.
4. Chen YW, Lee FY, Chang PH, Huang CC, Fu CH, Huang CC, Lee TJ. A paradigm for evaluation and management of the maxillary sinus before dental implantation. *Laryngoscope*. 2018 Jun;128(6):1261-1267. doi: 10.1002/lary.26856. PMID: 28921521.
5. Ata-Ali J, Diago-Vilalta JV, Melo M, Bagán L, Soldini MC, Di-Nardo C, Ata-Ali F, Mañes-Ferrer JF. What is the frequency of anatomical variations and pathological findings in maxillary sinuses among patients subjected to maxillofacial cone beam computed tomography? A systematic review. *Med Oral Patol Oral Cir Bucal*. 2017 Jul 1;22(4):e400-e409. doi: 10.4317/medoral.21456. PMID: 28578369; PMCID: PMC5549512.
6. Tadinada A, Fung K, Thacker S, Mahdian M, Jadhav A, Schincaglia GP. Radiographic evaluation of the maxillary sinus prior to dental implant therapy: A comparison between two-dimensional and three-dimensional radiographic imaging. *Imaging Sci Dent*. 2015 Sep;45(3):169-74. doi: 10.5624/isd.2015.45.3.169. PMID: 26389059; PMCID: PMC4574054.
7. Dau M, Marciak P, Al-Nawas B, Staedt H, Alshiri A, Frerich B, Kämmerer PW. Evaluation of symptomatic maxillary sinus pathologies using panoramic radiography and cone beam computed tomography-influence of professional training. *Int J Implant Dent*. 2017 Dec;3(1):13. doi: 10.1186/s40729-017-0075-5. PMID: 28382560; PMCID: PMC5382121.
8. Fortes JH, de Oliveira-Santos C, Matsumoto W, da Motta RJG, Tirapelli C. Influence of 2D vs 3D imaging and professional experience on dental implant treatment planning. *Clin Oral Investig*. 2019 Feb;23(2):929-936. doi: 10.1007/s00784-018-2511-1. PMID: 29907931.
9. Sun W, Xia K, Tang L, Liu C, Zou L, Liu J. Accuracy of panoramic radiography in diagnosing maxillary sinus-root relationship: A systematic review and meta-analysis. *Angle Orthod*. 2018;88(6):819-29.
10. Toraman Alkurt M, Peker I, Degerli S, Cebeci ARİ, Sadik E. Comparison of cone-beam computed tomography and panoramic radiographs in detecting maxillary sinus septa. *J Istanbul Univ Fac Dent*. 2016 Oct 1;50(3):8-14. doi: 10.17096/jiufd.84476. PMID: 28955570; PMCID: PMC5573509.
11. Gaëta-Araujo H, Alzoubi T, Vasconcelos KF, Orhan K, Pauwels R, Casselman JW, Jacobs R. Cone beam computed tomography in dentomaxillofacial radiology: a two-decade overview. *Dentomaxillofac Radiol*. 2020 Dec;49(8):20200145. doi: 10.1259/dmfr.20200145. PMID: 32501720; PMCID: PMC7719864.
12. Fryback DG, Thornbury JR. The efficacy of diagnostic imaging. *Med Decis Making*. 1991 Apr-Jun;11(2):88-94. doi: 10.1177/0272989X9101100203. PMID: 1907710.
13. Baciut M, Hedesiu M, Bran S, Jacobs R, Nackaerts O, Baciut G. Pre- and postoperative assessment of sinus grafting procedures using cone-beam computed tomography compared with panoramic radiographs. *Clin Oral Implants Res*. 2013 May;24(5):512-6. doi: 10.1111/j.1600-0501.2011.02408.x. PMID: 22220751.
14. Dagassan-Berndt DC, Zitzmann NU, Walter C, Schulze RK. Implant treatment planning regarding augmentation procedures: panoramic radiographs vs. cone beam computed tomography images. *Clin Oral Implants Res*. 2016 Aug;27(8):1010-6. doi: 10.1111/clr.12666. PMID: 26227397.
15. Carrasco Meza A, Quintanilla Sfeir M, Hidalgo Rivas A. Guías sobre el uso de tomografía computarizada de haz cónico en la evaluación pre-quirúrgica en implantología. *Av Odontoestomatol*. 2018;34(4):183-92.
16. Barba L, Berrocal AL, Hidalgo A. Uses of cone-beam computed tomography in San José, Costa Rica. *Imaging Sci Dent*. 2018 Jun;48(2):103-109. doi: 10.5624/isd.2018.48.2.103. PMID: 29963481; PMCID: PMC6015925.
17. Arancibia B, Schilling J, Schilling A, Correa-Beltrán G, Hidalgo A. Usos de tomografía computarizada de haz cónico en menores de 25 años en Talca, Chile. *Rev Cubana Estomatol*. 2017;54(3).
18. Deeb G, Antonos L, Tack S, Carrico C, Laskin D, Deeb JG. Is Cone-Beam Computed Tomography Always Necessary for Dental Implant Placement? *J Oral Maxillofac Surg*. 2017 Feb;75(2):285-289. doi: 10.1016/j.joms.2016.11.005. PMID: 27912075.
19. Knottnerus JA. The evidence base of clinical diagnosis. 2nd Ed. London: BMJ Books; 2002.
20. Al-Salehi SK, Horner K. Impact of cone beam computed tomography (CBCT) on diagnostic thinking in endodontics of posterior teeth: A before- after study. *J Dent*. 2016 Oct;53:57-63. doi: 10.1016/j.jdent.2016.07.012. PMID: 27461179.
21. ACR Appropriateness Criteria® [Internet]. Available from: <https://www.acr.org/Clinical-Resources/ACR-Appropriateness-Criteria>
22. Shelley AM, Ferrero A, Brunton P, Goodwin M, Horner K. The impact of CBCT imaging when placing dental implants in the anterior edentulous mandible: a before-after study. *Dentomaxillofac Radiol*. 2015;44(4):20140316. doi: 10.1259/dmfr.20140316. PMID: 25472617; PMCID: PMC4628432.

23. Pachêco-Pereira C, Alsufyani NA, Major MP, Flores-Mir C. Accuracy and reliability of oral maxillofacial radiologists when evaluating cone-beam computed tomography imaging for adenoid hypertrophy screening: a comparison with nasopharyngoscopy. *Oral Surg Oral Med Oral Pathol Oral Radiol.* 2016 Jun;121(6):e168-74. doi: [10.1016/j.oooo.2016.03.010](https://doi.org/10.1016/j.oooo.2016.03.010). PMID: [27181449](https://pubmed.ncbi.nlm.nih.gov/27181449/).
24. Constantine S, Clark B, Kiermeier A, Anderson PP. Panoramic radiography is of limited value in the evaluation of maxillary sinus disease. *Oral Surg Oral Med Oral Pathol Oral Radiol.* 2019 Mar;127(3):237-246. doi: [10.1016/j.oooo.2018.10.005](https://doi.org/10.1016/j.oooo.2018.10.005). PMID: [30477956](https://pubmed.ncbi.nlm.nih.gov/30477956/).
25. Lang AC, Schulze RK. Detection accuracy of maxillary sinus floor septa in panoramic radiographs using CBCT as gold standard: a multi-observer receiver operating characteristic (ROC) study. *Clin Oral Investig.* 2019 Jan;23(1):99-105. doi: [10.1007/s00784-018-2414-1](https://doi.org/10.1007/s00784-018-2414-1). PMID: [29525926](https://pubmed.ncbi.nlm.nih.gov/29525926/).
26. Morton D, Gallucci G, Lin WS, Pjetursson B, Polido W, Roehling S, Sailer I, Aghaloo T, Albera H, Bohner L, Braut V, Buser D, Chen S, Dawson A, Eckert S, Gahlert M, Hamilton A, Jaffin R, Jarry C, Karayazgan B, Laine J, Martin W, Rahman L, Schlegel A, Shiota M, Stilwell C, Vorster C, Zembic A, Zhou W. Group 2 ITI Consensus Report: Prosthodontics and implant dentistry. *Clin Oral Implants Res.* 2018 Oct;29 Suppl 16:215-223. doi: [10.1111/clr.13298](https://doi.org/10.1111/clr.13298). PMID: [30328196](https://pubmed.ncbi.nlm.nih.gov/30328196/).