



## SHORT COMMUNICATION

# Presence of *Helicobacter* spp. in dental tartar and gastric mucosa, and its relationship with EGUS in horses from a public slaughterhouse

*Presencia de Helicobacter spp. en sarro dental y mucosa gástrica y su relación con SUGE en equinos de una planta de beneficio pública*

*Presença de Helicobacter spp. em tártaro dentário e mucosa gástrica e sua relação com SUGE em equinos de um abatedouro público*

Angélica M Zuluaga-Cabrera<sup>1\*</sup> ; Camilo Jaramillo-Morales<sup>2</sup> ; José R Martínez-Aranzaes<sup>1</sup> .

<sup>1</sup>Grupo de investigación en ciencias veterinarias –CENTAURO–, Línea de Investigación en Medicina y Cirugía Equina (LIMCE), Escuela de Medicina Veterinaria, Facultad de Ciencias Agrarias, Universidad de Antioquia, Medellín – Antioquia (Colombia).

<sup>2</sup>Programa de Medicina Veterinaria, Facultad de Ciencias Administrativas y Agropecuarias, Corporación Universitaria Lasallista, Caldas – Antioquia (Colombia). Current address: Veterinary Medicine Teaching Hospital, School of Veterinary Medicine, University of California – Davis, CA, USA.

### To cite this article:

Zuluaga-Cabrera AM, Jaramillo-Morales C, Martínez-Aranzaes JR. Presence of *Helicobacter* spp. in dental tartar and gastric mucosa, and its relationship with EGUS in horses from a public slaughterhouse. Rev Colomb Cienc Pecu 2022; 35(2): 109–117. DOI: <https://doi.org/10.17533/udea.rccp.v35n1a06>

### Abstract

**Background:** Despite the fact that *Helicobacter* spp. has been detected in equine gastric mucosa, no evidence exists about this infection in Colombian horses affected by equine ulcerative gastric syndrome (EGUS), nor in dental tartar. **Objective:** To detect *Helicobacter* spp. DNA in equine gastric mucosa and dental tartar and determine the relationship between the presence of *Helicobacter* spp. and gastric lesions. **Methods:** Samples of glandular gastric mucosa and dental tartar were collected from 30 equine slaughterhouses. Macroscopic lesions of the stomachs were classified and the total DNA in all samples was extracted using a commercial extraction kit. A final-point PCR was performed using primers for amplification of a segment of 251 bp of the gene encoding the 16s rRNA region; the amplified fragments were subjected to a second PCR to determine the presence of *H. pylori*, the VacA gene was typified.

Received: January 19, 2021; accepted: April 14, 2021

\*Corresponding author. Calle 70 No. 52-21, Medellín (Antioquia, Colombia). E-mail: [angelica.zuluaga@udea.edu.co](mailto:angelica.zuluaga@udea.edu.co)



This work is licensed under a Creative Commons Attribution-NonCommercial-ShareAlike 4.0 International License.

© 2022 Universidad de Antioquia. Publicado por Universidad de Antioquia, Colombia.

The resulting amplicons were sequenced. **Results:** It was possible to amplify 16s rRNA in several samples but there was no amplification of VacA. Fragments of the sequences were compatible with *H. heilmannii*. The 23.3 and 10% of gastric and tartar samples were positive for 16s rRNA of *Helicobacter* spp., respectively. **Conclusion:** Although genetic material of *Helicobacter* spp. was found in some animals, there was no relationship with gastric lesions. It is possible that helicobacteriosis has no bearing in EGUS etiology.

**Keywords:** equines; gastritis; *Helicobacter* spp; horse; mucosa; PCR; post-mortem; stomach; tartar; ulcer.

### Resumen

**Antecedentes:** A pesar de que se ha detectado *Helicobacter* spp. en mucosa gástrica equina, no existe evidencia de esta infección en caballos criollos colombianos afectados por síndrome ulcerativo gástrico (SUGE), ni tampoco reportes en sarro dental. **Objetivo:** Detectar ADN de *Helicobacter* spp. en sarro dental y mucosa gástrica de equinos, y determinar la relación entre la presencia de la bacteria y lesiones gástricas. **Métodos:** Las muestras de mucosa glandular gástrica y sarro dental fueron colectadas de 30 equinos que se encontraban en planta de beneficio. Las lesiones macroscópicas fueron clasificadas y el ADN total de las muestras fue extraído utilizando un kit comercial. Se desarrolló PCR convencional usando cebadores específicos para la amplificación de un segmento de 251 pb de un gen que codifica la región 16S del ARNr; los fragmentos amplificados fueron sometidos a una segunda PCR para determinar la presencia de *H. pylori* mediante la amplificación del gen VacA. Los amplificados resultantes fueron secuenciados. **Resultados:** Fue posible amplificar 16s ARNr en varias muestras, pero no hubo amplificación de VacA. Los fragmentos de las secuencias fueron compatibles con *H. heilmannii*. El 23,3 y 10% de las muestras gástricas y sarro fueron positivas para 16s ARNr de *Helicobacter* spp., respectivamente. **Conclusión:** Aunque el material genético de *Helicobacter* spp. se encontró en algunos animales, no hubo relación con las lesiones gástricas. Es posible que la helicobacteriosis no tenga incidencia en la etiología del EGUS.

**Palabras clave:** caballo; equinos; estómago; gastritis; *Helicobacter* spp; mucosa; PCR; post-mortem; sarro; úlcera.

### Resumo

**Antecedentes:** Apesar do *Helicobacter* spp. ter sido detectado na mucosa gástrica de equinos, não há evidências dessa infecção em cavalos crioulos colombianos afetados pela síndrome ulcerativa gástrica (SUGE), ou no sarro. **Objetivo:** Detectar ADN de *Helicobacter* spp. na mucosa gástrica e do sarro dental de equinos, e determinar a relação entre a presença de *Helicobacter* spp. e lesões gástricas. **Métodos:** Amostras de mucosa gástrica glandular e sarro dental foram coletadas de 30 equinos de abatedouro, as lesões macroscópicas dos estômagos foram classificadas. Se realizou extração de ADN total em todas as amostras através de kit comercial. Realizou-se PCR ponto final, amplificando o segmento de 251 pb do gene que codifica para a região 16s ARNr; os fragmentos amplificados foram submetidos novamente a PCR para determinar a presença de *H. pylori*, ao tipificar o gene VacA, e seguidamente foram sequenciados. **Resultados:** O houve amplificação do 16s ARNr em várias amostras, mas não amplificação de VacA. Fragmentos das sequências foram compatíveis com *H. heilmannii*. O 23,3 e 10% das amostras gástricas e do sarro foram positivas para 16s ARNr de *Helicobacter*, respectivamente. **Conclusão:** Embora material genético de *Helicobacter* spp. encontrou-se em alguns animais não houve relação com lesões gástricas. Possivelmente a helicobacterioses não tem papel relevante na etiologia da SUGE.

**Palavras-chave:** cavalo; equinos; estômago; gastrite; *Helicobacter* spp; mucosa; PCR; post mortem; tártaro; úlcera.

## Introduction

*Helicobacter pylori* infection has importance in pathogenesis of ulceration and gastric cancer, among other extra-digestive diseases in humans (Figura *et al.*, 2010). This bacteria is gram-negative, microaerophilic, flagellated, pleomorphic (although its usual shape is spiral; Hermanns *et al.*, 1995), oxidase, catalase, and urease positive (Montgomery *et al.*, 1988). Studies on *Helicobacter* spp. conducted in ferrets, leopards, primates, calves (Hermanns *et al.*, 1995), sheep, pigs (Barbosa *et al.*, 1995), cats and dogs (Jalava *et al.*, 1998; Neiger and Simpson, 2000) showed high gastric presentation. Inoculation of *H. pylori* in animal models has developed the same pattern of chronic active gastritis as in humans (Lee, 1998). Cardona *et al.* (2009) described chronic inflammatory patterns in gastric mucosa of equines with presence of *Helicobacter* spp. determined by rapid urease test and histological evaluation. Although several species, such as *H. felis*, *H. heilmannii*, *H. bizzozeronii*, *H. bitis*, *H. salomonis*, *H. rappini*, have been isolated besides *H. pylori* in animals, there is little information on equines regarding the relationship between this infection and gastric disease. There is little information on ways of infection, transmission and/or zoonotic potential of *Helicobacter* spp. in equines.

*H. pylori* diagnosis can be performed with invasive (direct) or noninvasive (indirect) methods. Invasive methods require trans-endoscopic collection of biopsies for identification of the bacterium, such as rapid urease testing, cytology, histopathology, cultures and PCR. Non-invasive methods depart from the indirect demonstration of the presence of the bacteria, such as the labeled urea breath test and serological tests.

The presence of this bacteria in the gastric surface of equines -with other microorganisms and bacterial metabolites- has been proposed as a cause for equine gastric ulcer syndrome (EGUS). *Helicobacter pylori* and *Helicobacter equorum* have been isolated in ulcerated and

healthy equines with controversial participation in EGUS physiopathology in Europe and North America, where there is high incidence and prevalence of this syndrome (Scott *et al.*, 2001; Bezdekova and Futas, 2009; Moyaert *et al.*, 2009).

Due to its high transmissibility, possible zoonotic potential, association between *Helicobacter* spp. and gastric pathologies in humans, and the presence of EGUS (specially equine gastric glandular disease-EGGD), it is relevant to understand the participation of this bacterium in gastric mucosa alterations in the Colombian Creole horse and the homology between the species infecting both humans and equines.

Therefore, the aim of this study was to assess the presence of *Helicobacter* spp. DNA in equine gastric mucosa and dental tartar and evaluate the relationship between presence of these bacteria and gastric lesions. We hypothesized no relationship exists between *Helicobacter* spp. colonization and EGGD. We also assumed that *Helicobacter* spp. is present in the dental tartar.

## Materials and Methods

### *Ethical considerations*

This study was approved by the Ethics Committee in Animal Experimentation of the University of Antioquia, Colombia (endorsement: June 2014).

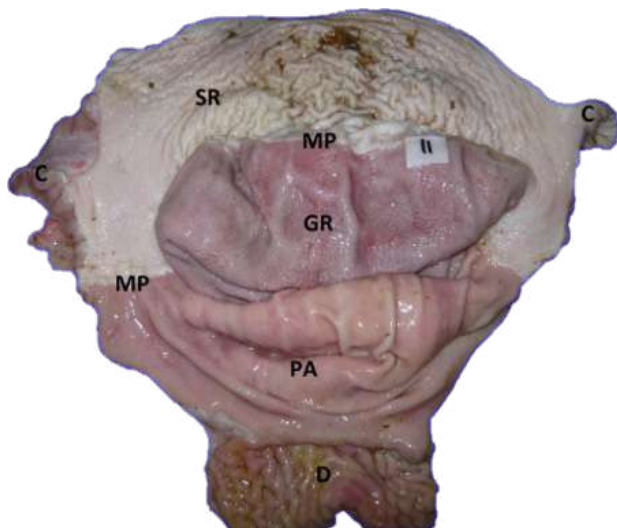
### *Animals*

A convenience sample from 30 equines taken at a slaughterhouse in Rionegro municipality, province of Antioquia (Colombia) was used. The facilities are located at coordinates 6°09'12"N 75°22'27"W, with 2,080 m.a.s.l. and the average temperature is 18.5 °C.

### *Evaluation of the gastric surface*

The stomachs obtained post-mortem were opened and washed with distilled water, identified

numerically and later photographed. The lesions found in the glandular regions, pyloric antrum, squamous area (*Margo plicatus*) and cardial area were classified according to the system recommended by Sykes *et al.* (2015; Figure 1).



**Figure 1.** Stomach prepared for lesion classification. C = Cardias, SR = Squamous region, MP: *Margo plicatus*, GR = Glandular region, PA = *Pyloric antrum*, D = Duodenum.

#### *Sample collection*

Stomach and head of each individual, previously prepared and numbered, were sampled. Fragments of glandular gastric mucosa (fundus) of approximately 1 cm<sup>2</sup> were obtained using a sterile scalpel blade for each animal. Tartar samples were obtained by friction with a curette (sanitized with 2% glutaraldehyde between individuals) on the enamel surface of the upper incisors. Subsequently, both were submerged in a 2.5 ml cryovial with sterile PBS 1X for freezing (-20 °C). These samples were directly taken at the slaughterhouse, from horses starved for at least eight hours.

#### *Total DNA extraction*

Total DNA extraction was performed with a commercial extraction kit (Wizard<sup>®</sup> Genomic DNA Purification Kit; Madison, WI, USA) added with proteinase K (60 µl per sample) for the processing of the stomach samples. Dental

tartar samples were subjected to extraction with columns (Qiagen<sup>®</sup> DNeasy Blood & Tissue Kit; Hilden, Germany). Once total DNA was extracted, electrophoresis was performed by adding 1 µl of loading buffer to 1 µl of each sample on a 2% agarose gel in order to evidence the extracted product. The extracted DNA was stored in a cryovial for freezing (-20 °C).

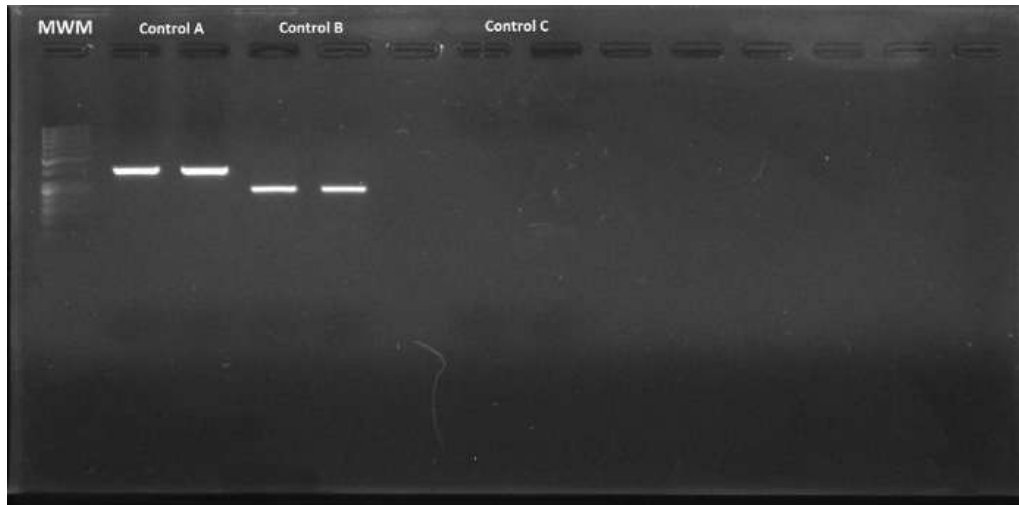
#### *Amplification of the encoding gene of the Helicobacter spp. 16s rRNA region*

A final-point PCR was carried out using primers for amplification of a 251 bp segment of the gene encoding the 16s rRNA, whose sequence was: HelF (forward) 5'-CGTGGAGGATGAAGGTTTAA-3' and HelR2 (reverse) 5'-AATTCCACCTACCTCTCCC-3' (Recordati *et al.*, 2007).

A commercial mix was used for PCR (GoTaq Green Master Mix<sup>®</sup>; Madison, WI, USA) (10.5 µl per reaction), added with 0.5 µl of each primer (initiator and reverse), 10 µM, 4.5 µl of deionized sterile water and 2 µl of DNA (final volume per reaction: 18 µl). The PCR conditions were as follows: 5 minutes at 94 °C, followed by 40 cycles of denaturalization at 94 °C for 30 seconds; alignment of primers at 45 °C for 30 seconds, and extension to 72 °C for 30 seconds, with a final extension step at 72 °C for 7 minutes. *Helicobacter pylori* DNA, donated by the Gastrohepatology laboratory of the Medicine School at Universidad de Antioquia (Figure 2), was used as positive control.

#### *Amplification of the encoding gene of the Helicobacter pylori VacA region*

Primers for the *H. pylori* VacA region were used since it is considered to be a species' own virulence factor. The detection of a gene sensitive for detecting the microorganism was also considered. The PCR results that were identical to the positive control (encoding gene of the 16s rRNA region) were subjected to a new PCR to determine the presence of *H. pylori*.



**Figure 2.** Electrophoresis in agarose gel at 2% of the amplified fragments of the coding gene for the *Helicobacter pylori* 16s rRNA region (positive control). MWM = Molecular weight marker; Control A = Amplified fragments of primers C98 and C97 (16s rRNA) of the duplicate positive control; Control B = Amplified fragments of primers HelF and HelR (16s rRNA) of the duplicate positive control; Control C = Duplicate negative control.

To this end, the *VacA* gene was typed in the samples by using *VacA* primers (s) (initiator) 5'-ATG GAA ATA CAA CAA ACA CAC 3' (reverse) 5' CTG CTT GAATGC GCCAAAC 3'; and *VacA* (m) (initiator) 5' CAA TCT GTC CAA TCA AGC GAG 3' (reverse) 5' GCG TCT AAA TAA TTC CAA GG 3'. The PCR conditions for *VacA* "s" and "m" were as follows: 2 minutes at 92 °C, followed by 35 cycles of denaturalization at 94 °C for 1 minute, alignment of primers at 55 °C for 1 minute, and extension to 72 °C for 1 minute.

### Sequencing

Sequencing was performed in Macrogen™ laboratories (Korea). Sequences were analyzed using BLAST (Basic Local Alignment Search Tool; <http://blast.ncbi.nlm.nih.gov>) to compare the nucleotide sequences from the PCR products of the amplified region with similar sequences reported in the GenBank.

### Results

Gastric tissues and dental tartar samples required maceration prior to the extraction protocol. All the stomach samples evidenced DNA extracted by electrophoresis in 2% agarose

gel. In contrast, only some of the tartar samples evidenced DNA through electrophoresis. It was possible to amplify the encoding fragment for the 16s rRNA region. However, for the *VacA* gene (s and m) no amplification was found, even though the positive control worked properly. The samples (stomach and tartar) from which fragments were amplified were considered *Helicobacter*-positive. These fragments have gel diffusion compatible with the sequence of the coding gene of the *Helicobacter* spp. 16s rRNA region. 23.3% (7/30) of the stomach samples were positive, while 10% (3/30) of tartar samples were positive.

The 3 or 4-degree lesions were evidenced in the *Margo plicatus*, or cardial region, and some of those injured stomachs were *Helicobacter*-positive (4/7). The remaining positive results corresponded to stomachs classified with lesions 0 – 2 (Table 1).

The sequences obtained were not clear and confirmation of *Helicobacter* spp. DNA was difficult in the amplified fragment. Fragments of the clearer sequences were compatible with *H. heilmannii* in 25 nucleotides. The positive control sequence was 100% compatible with *H. pylori* in both gastric mucosa and tartar.

**Table 1.** Classification of gastric lesions (according to Sykes *et al.*, 2015) and result of the PCR for each region, per individual.

Sample/ Horse	Glandular region	Pyloric antrum	Squamous region ( <i>Margo plicatus</i> )	Cardial region	PCR (Stomach)	PCR (Tartar)
1	1	1	0	0		+
2	2	0	0	4		
3	1	0	0	0	+	
4	0	0	0	0		
5	2	0	0	0		+
6	1	0	0	0		
7	1	0	4	0	+	
8	0	0	0	0		
9	2	0	0	0		
10	1	0	3	0	+	
11	0	0	0	0		
12	0	2	0	0		
13	1	0	0	0		
14	0	0	0	0		
15	1	1	0	0		
16	2	0	0	0		
17	0	1	0	0	+	
18	1	0	0	0	+	
19	1	0	0	4	+	
20	1	0	4	4		
21	1	0	4	4		
22	0	0	0	3		+
23	1	0	0	4		
24	1	3	0	0		
25	1	0	0	0	+	
26	0	1	0	0		
27	1	0	0	0		
28	2	0	3	0		
29	0	0	0	0		
30	1	0	0	3		

+ = Amplification of the encoding gene for the *Helicobacter* spp. 16s rRNA region.

## Discussion

According to our results, it was not possible to establish a relationship between lesions in the squamous mucosa (equine squamous gastric disease-ESGD) or glandular mucosa (EGGD) and the presence of *Helicobacter* spp. This confirms that, as has been described in other horse breeds, infection by *Helicobacter* spp. and ESGD or EGGD are not related.

In addition, sequencing and verification of the species in GenBank detected a homology of 25 nucleotides as *H. heilmannii*. This specie has been reported as a commensal in horses (Perkins *et al.*, 2012; Dong *et al.*, 2016). Other researchers (Husted *et al.*, 2010) reported that *Helicobacter* does not appear in the gastric microbiome of slaughtered horses; not even in lesioned gastric tissue. To the best of our knowledge, this is

the first report evidencing the presence of *Helicobacter* spp. in dental tartar in horses. On the other hand, UREI gene of *Helicobacter* has been used to detect gastric infection in horses and, in contrast with our results, could found developing infections (Hepburn, 2004).

Some researchers reported sample preservation in absolute ethanol to ensure integrity of the bacterium (Contreras *et al.*, 2007). In contrast, the present study preserved the samples in sterile PBS 1X; this difference could have affected the quality of the extracted DNA, since loss of tissue integrity in some samples was evidenced after cryopreservation, which was reflected in DNA damage evidenced in electrophoresis by the appearance of a great number of artifacts. Because glutaraldehyde 2% was used to sanitize the curette, it might have caused the inconsistent sequencing results (Churro *et al.*, 2015). This could imply loss of positive results.

The total DNA extraction protocol was modified by adding proteinase K to achieve complete tissue dehiscence. The PCR protocol used was taken from a study on gastric mucosa and dental tartar in dogs; however, even though the described conditions were replicated, numerous bands by sample of DNA subjected to electrophoresis were obtained, so such protocol also suffered a temperature adjustment of primer alignment.

Due to the method used to obtain stomach samples post-mortem it was possible to process the totality of them (including all stomach layers from the mucosa to the serosa), ensuring detection of the bacterium in any of the layers. This differs from studies conducted from biopsy samples by endoscopy, where the fragments obtained only sometimes include mucus and epithelial cells of the mucous layer.

As described by Contreras *et al.* (2007), the appearance of DNA compatible with *Helicobacter* spp. was more frequent in stomachs with mild or non-existing lesions, whereas the majority of those characterized as deep lesions did not correspond to positive

samples for *Helicobacter* spp. This can happen because the loss of tissue integrity does not offer favorable conditions for the microorganism to remain viable, and therefore it is presumed that this microorganism moves to healthy tissue, facilitating its detection there. Consequently, establishing the relationship between presence of *Helicobacter* spp. and gastric lesions is a complex issue.

Our results contrast with those conducted in humans since they have shown 100% association in both samples, in bacterial plaque or tartar and in gastric mucosa (Scarano *et al.*, 2005), while the present study did not find any relationship between dental tartar and gastric mucosa results in equines.

In conclusion, 23.3% of stomach and 10% of tartar samples amplified for the gene encoding for the 16s rRNA region of *Helicobacter* spp. A relationship with gastric lesions was not found. The present study suggests that there is no direct relationship between *helicobacteriosis* and EGUS or EGGD, and that the infecting species of *Helicobacter* spp. in the horse stomach do not correspond to those with zoonotic potential. *Helicobacter* spp. DNA detection in equine tartar sets the foundations for conducting new epidemiologic studies about this condition, since this is the first report on the issue.

## Declarations

### *Acknowledgements*

The authors thank the Gastrohepatology Research Group of Facultad de Medicina, Universidad de Antioquia (Colombia) and the Laboratory of Clinical and Veterinary Studies of Corporación Universitaria Lasallista (Colombia).

### *Funding*

The study was funded by the Sustainability Strategy from CODI 2015-2016, Universidad de Antioquia (Colombia).

*Conflicts of interest*

The authors declare they have no conflicts of interest with regard to the work presented in this report.

*Author contributions*

Angélica M. Zuluaga-Cabrera wrote the manuscript with support from the co-authors, conceived the original idea and supervised the project. Camilo Jaramillo-Morales contributed to the design and implementation of the study, analysis of the results, and writing of the manuscript. José R. Martínez-Aranzales contributed to the design and implementation of the study, analysis of the results, and writing of the manuscript.

**References**

- Barbosa A, Silva JC, Nogueira AM, Paulino-Júnior E, Miranda CR. Higher incidence of *Gastrospirillum* sp. in swine with gastric ulcer of the pars oesophagea. *Vet Pathol* 1995; 32(2):134–139. <https://doi.org/10.1177/030098589503200206>
- Bezdekova B, Futas J. *Helicobacter* species and gastric ulceration in horses: a clinical study. *Vet Med-Czech*. 2009; 54(12):577–582. <https://doi.org/10.17221/161/2009-VETMED>
- Cardona J, Paredes E, Fernández H. Characterization histopathological of gastritis associated to *Helicobacter* spp. presence in stomachs of horses. *Rev MVZ Córdoba* 2009; 14(2):1750–1755. [access December 15th, 2020] URL: <http://www.scielo.org.co/pdf/mvz/v14n2/v14n2a12.pdf>
- Churro C, Valério E, Pereira P, Vasconcelos V. Applicability of the real-time PCR assay in the amplification of cyanobacterial DNA from preserved samples. *Limnetica* 2015; 34(1):173–186. <https://doi.org/10.23818/limn.34.14>
- Contreras M, Morales A, García-Amado M, De-Vera M, Bermúdez V, Gueneau P. Detection of *Helicobacter*-like DNA in the gastric mucosa of thoroughbred horses. *Lett Appl Microbiol* 2007; 45:553–557. <https://doi.org/10.1111/j.1472-765X.2007.02227.x>
- Dong H, Ho H, Hwang H, Kim Y, Han J, Lee I, Cho S. Diversity of the gastric microbiota in thoroughbred racehorses having gastric ulcer. *Microbiol Biotechnol* 2016; 26(4):763–774. <https://doi.org/10.4014/jmb.1507.07054>
- Figura N, Franceschi F, Santucci A, Bernardini G, Gasbarrini G, Gasbarrini A. Extragastric manifestations of *Helicobacter pylori* infection. *Helicobacter* 2010; 15(1):60–68. <https://doi.org/10.1111/j.1523-5378.2010.00778.x>
- Hepburn RJ. Investigation into the presence of *Helicobacter* in the equine stomach by urease testing and polymerase chain reaction and further investigation into the application of the 13C-urea blood test to the horse. Virginia Polytechnic Institute, doctoral thesis, 2004. [access December 1<sup>st</sup>, 2020] URL: <https://vtechworks.lib.vt.edu/handle/10919/33587>
- Hermanns W, Kregel K, Breuer W, Lechner J. *Helicobacter*-like organisms: histopathological examination of gastric biopsies from dogs and cats. *J Comp Pathol* 1995; 112(3):307–318. [https://doi.org/10.1016/s0021-9975\(05\)80083-0](https://doi.org/10.1016/s0021-9975(05)80083-0)
- Husted L, Jensen T, Olsen S, Mølbak L. Examination of equine glandular stomach lesions for bacteria, including *Helicobacter* spp. by fluorescence in situ hybridisation. *BMC Microbiol* 2010; 10:84. <https://doi.org/10.1186/1471-2180-10-84>
- Jalava K, On S, Vandamme P, Happonen I, Sukura A, Hänninen M. Isolation and identification of *Helicobacter* spp. from canine and feline gastric mucosa. *Appl Environ Microbiol* 1998; 64(10):3998–4006. <https://doi.org/10.1128/AEM.64.10.3998-4006.1998>
- Lee A. Animal models for host pathogen interaction studies. *Br Med Bull* 1998; 54(1): 163–173. <https://doi.org/10.1093/oxfordjournals.bmb.a011666>



- Montgomery E, Martin D, Peura D. Rapid diagnosis of *Campylobacter pylori* by Gram's stain. *Am J Clin Pathol* 1988; 90(5):606–609. <https://doi.org/10.1093/ajcp/90.5.606>
- Moyaert H, Haesebrouck F, Dewulf J, Ducatelle R, Pasmans F. *Helicobacter equorum* is highly prevalent in foals. *Vet Microbiol* 2009; 133(1-2):190–192. <https://doi.org/10.1016/j.vetmic.2008.06.004>
- Neiger R, Simpson K. *Helicobacter* infection in dogs and cats: facts and fiction. *J Vet Intern Med* 2000; 14(2):125–133. [https://doi.org/10.1892/0891-6640\(2000\)014<0125:ii dacf>2.3.co;2](https://doi.org/10.1892/0891-6640(2000)014<0125:ii dacf>2.3.co;2)
- Perkins G, den-Bakker H, Burton A, Erb H, McDonough S, McDonough P, *et al.* Equine stomachs harbor an abundant and diverse mucosal microbiota. *Appl Environ Microbiol* 2012; 78(8):2522–1532. <https://doi.org/10.1128/AEM.06252-11>
- Recordati C, Gualdi V, Tosi S, Facchini RV, Pengo G, Luini M, Simpson KW, Scanziani E. Detection of *Helicobacter* spp. DNA in the oral cavity of dogs. *Vet Microbiol* 2007; 119(2-4):346–351. <https://doi.org/10.1016/j.vetmic.2006.08.029>
- Scarano GA, Correia-de-Medeiros A, Marques MS, Chimenos E, de Castro R, Perdomo M. Detección de *Helicobacter pylori* en placa dental y en mucosa gástrica de pacientes sometidos a endoscopia digestiva. *Acta Odontol Venez* 2005; 43(2):13–118. [access December 1<sup>st</sup>, 2020] URL: [http://ve.scielo.org/scielo.php?script=sci\\_arttext&pid=S0001-63652005000200003&lng=es&nrm=iso&tlng=es](http://ve.scielo.org/scielo.php?script=sci_arttext&pid=S0001-63652005000200003&lng=es&nrm=iso&tlng=es)
- Scott DR, Marcus EA, Shirazi-Beechey SSP, Murray MJ. Evidence of *Helicobacter* infection in the horse. *Proceedings of the American Society of Microbiologists*; 2001 20–24; Orlando, FL, USA. [access November 15<sup>th</sup>, 2020] URL: <https://pubmed.ncbi.nlm.nih.gov/15973586/>
- Sykes BW, Hewetson M, Hepburn RJ, Luthersson N, Tamzali Y. European college of equine internal medicine consensus statement—equine gastric ulcer syndrome in adult horses. *J Vet Intern Med* 2015; 29(5):1288–1299. <https://doi.org/10.1111/jvim.13578>