

PREVENTION OF ORAL CANCER THROUGH THE IMPLEMENTATION OF A TELEDENTISTRY PLATFORM FOR THE ELDERLY.

Prevención del cáncer oral mediante la implementación de una plataforma de teleodontología para adultos mayores.

Bernardo Venegas.¹
Sandra Rueda.²
Marco Flores.^{3,4}
Angeline Cerda.⁵
Víctor Beltrán.¹

Affiliations:

¹Department of Stomatology, Faculty of Health Sciences, Universidad de Talca, Talca, Chile.

²Department of Oral Pathology, Faculty of Dentistry, Universidad Santo Tomás, Bucaramanga, Colombia.

³Clinical Investigation and Dental Innovation Center (CIDIC), Dental School and Center for Translational Medicine (CEMT-BIOREN), Universidad de La Frontera, Temuco, Chile.

⁴Postgraduate Program in Oral Rehabilitation, Department of Integral Adults Dentistry, Dental School, Universidad de La Frontera, Temuco, Chile.

⁵Dental School, Faculty of Dentistry, Universidad de La Frontera, Temuco, Chile.

Corresponding author: Bernardo Venegas. 1 Poniente 635 Departamento # B101, Talca, Chile. **Phone:** (56-9) 98898084. **E-mail:** bvenegas@utalca.cl

Receipt : 09/28/2021
Acceptance : 04/27/2022

Cite as: Venegas B, Rueda S, Flores M, Cerda A & Beltrán V.

Prevention of oral cancer through the implementation of a teledentistry platform for the elderly.

J Oral Res 2022; S-1 (Seminario Científico):1-8.

Doi:10.17126/joralres.2022.027

ABSTRACT:

Objective: To contribute to early diagnosis of lesions in older patients, including potentially malignant lesions or those suspected of oral cancer by support of a web-based teledentistry platform. **Material and Methods:** This report contains information from 27 patients with oral lesions out of a total of 135 who received mobile dental care. Specialists who participated in the study involved professionals from the disciplines of periodontics, temporomandibular disorders, oral implantology, oral radiology, oral pathology and geriatrics. Referral consultations were carried out synchronously or asynchronously. Clinical information sent to oral pathology specialists involved a medical history and a traditional description of the lesion which considered size, color, limits, symptomatology, type of surface, consistency, location, and evolution. This information was complemented with a three-dimensional representation of the lesion, simulating an extra/intra oral clinical examination including a marker tool that allows to perform the anatomical-referencing of oral lesions. **Results:** 27 consultations from 26 patients were evaluated for oral pathology lesions. 12 lesions were diagnosed as reactive, 5 were infectious lesions, 4 of vascular etiology, 3 pigmented lesions (amalgam tattoo and smoking-related melanosis) and 3 potentially malignant lesions. The most frequent location was the tongue with 8 cases, followed by the gingiva and jugal mucosa, each with 5 cases. Four lesions required biopsy and histopathological report. **Conclusion:** A teledentistry platform including digital representations of oral lesions using different digital markers, also associated with a mobile system to provide dental care, constitutes an excellent tool to treat patients that present oral lesions with potential cancer risk.

KEYWORDS:

Dental care; three-dimensional; geriatrics; periodontics; teledentistry; biopsy.

RESUMEN:

Objetivo: Contribuir al diagnóstico precoz de lesiones en pacientes mayores, incluyendo lesiones potencialmente malignas o con sospecha de cáncer oral mediante el apoyo de una plataforma de teleodontología basada en la web. **Material y Métodos:** Este informe contiene información de 27 pacientes con lesiones orales de un total de 135 que recibieron atención odontológica móvil. Los especialistas que participaron en el estudio incluyeron profesionales de las disciplinas de periodoncia, trastornos temporomandibulares, implantología oral, radiología oral, patología oral y geriatría. Las interconsultas se realizaron de forma sincrónica o asincrónica. La información clínica enviada a los especialistas en patología oral involucró una historia clínica y una descripción tradicional de la lesión que consideró tamaño, color, límites, sintomatología, tipo de superficie, consistencia, localización y evolución. Esta información se complementó con una representación tridimensional de la lesión, simulando un examen clínico extra/intraoral incluyendo una

herramienta marcadora que permite realizar la referenciación anatómica de las lesiones orales. **Resultados:** Se evaluaron 27 consultas de 26 pacientes por lesiones de patología bucal. Se diagnosticaron 12 lesiones como reactivas, 5 lesiones infecciosas, 4 de etiología vascular, 3 lesiones pigmentadas (tatuaje de amalgama y melanosís por tabaquismo) y 3 lesiones potencialmente malignas. La localización más frecuente fue lengua con 8 casos, seguida de encía y mucosa yugal con 5 casos cada una. Cuatro lesiones requirieron biopsia e informe histopatológico. **Conclusión:** Una plataforma de teleodontología que incluye representaciones digitales de lesiones orales utilizando diferentes marcadores digitales, también asociada a un sistema móvil para brindar atención odontológica, constituye una excelente herramienta para tratar pacientes que presentan lesiones orales con riesgo potencial de cáncer.

PALABRAS CLAVE:

Atención odontológica, tridimensional, geriatría, periodoncia, teleodontología, biopsia.

INTRODUCTION.

Oral cavity cancer is a public health problem. In Latin America it is considered the fifth most frequent cancer in men, with 60% of late detection and a 5-year survival of 50%.¹

This disease is considered preventable since the risk factors (*i.e.* consumption of tobacco, alcohol, virus and sun exposure) are already well known, and the fact that the dentist has an easy access to the oral cavity, so he can identify any disorder and make the referral for diagnosis and treatment in early stages.²

This requires rapid communication with specialists, which can be achieved through teledentistry. This system allows for the exchange of information on the patient's medical history, images, videos and every aspect related to their health status, using a computer or a mobile device. It facilitates screening, diagnosis and treatment, and is considered a useful tool to reach especially the most underserved populations.³

The global crisis generated by the coronavirus pandemic (SARS-CoV-2), offers an opportunity to

rethink the traditional in-person approach to dentistry and allows older adults who are confined or institutionalized and cannot receive proper care in a conventional dental clinic to do so through strategies such as teledentistry.

According to evidence, teledental care has a high sensitivity and specificity for the diagnosis of oral diseases in the elderly,⁴ allowing for the early diagnosis of oral lesions, potentially malignant disorders and oral cancer, so that proper care is not delayed.

A technological semi in-person platform was designed and implemented to support dental emergencies and priority consultations for the elderly in the context of the COVID-19 pandemic in the Chilean and Colombian population.

This platform allowed for oral health assistance provided by a general dentist to confined patients in a mobile dental clinic, accompanied by specialists synchronously or asynchronously, which contributes to the early diagnosis of cancer risk pathologies such as leukoplakia, eritroplakia and oral lichen planus.

This article reports the results of the referral consultations carried out onboard a mobile dental clinic in five regions of Chile (Metropolitana, Bio-Bio, Araucanía, Antofagasta and Maule) from February to May 2021, which were then sent to oral pathologists, managing to establish a network of specialists in a timely way, which permits the diagnosis and management of the lesions found in the oral cavity of older adults without the need for physically referring them to health centers.

MATERIALS AND METHODS.

Platform designing was performed by engineers and information technology (IT) specialists between June and December 2020. Details of the construction of the platform are reported elsewhere.

The implementation and use of the platform began in January 2021. It consisted of a computational system designed to register clinical information from patients and the transmission of data to different specialists, aiming to provide accurate diagnosis and management recommendations, so that the patient could receive proper treatment in a short period of time. The present report contains information from 27 patients with oral lesions out of a total of 135 who received mobile dental assistance.

A weekly schedule was used to organize the connection between the specialist and the general dentist. Specialists who participated in the study involved professionals from the disciplines of periodontics, temporomandibular disorders, oral implantology, oral radiology, oral pathology and geriatric medicine. Referral consultations were carried out synchronously or asynchronously.

When an oral lesion was detected during dental examination, clinical information was registered in the platform and sent immediately to the specialist via an auto-generated mail from the platform to a previously registered mail address. The specialist received the information and answered the interconsultation directly through the platform. Three oral pathologists participated answering referral consultations from the general dentist located in the mobile dental clinic.

Clinical information sent to oral pathology specialists involved a medical history and a traditional description of the lesion which considered size, color,

limits, symptomatology, type of surface, consistency, localization and evolution.

This information was complemented with a 3D digital representation of the lesion, which consists in an innovative 3D phantom that permits loading different layers of diagnostic information, simulating an extra/intra oral clinical examination including the tool of a marker that allows to perform the anatomical-referencing of oral lesions.

Additionally, clinical images of the lesion and comments from the general dentist can be included embedded in the marker (Figure 1A and Figure 1B).

RESULTS.

Twenty-seven consultations from 26 patients were evaluated for oral pathology lesions. The mean age was 72 years with a SD of 6.5 years; 58% of the patients were female.

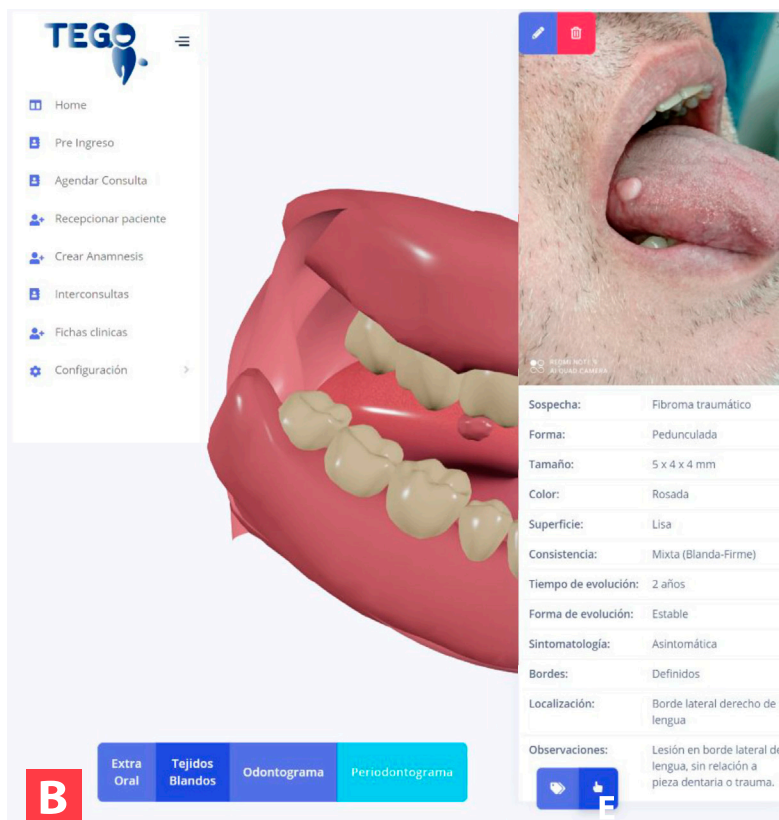
Twelve lesions were diagnosed as reactive (fibroma, frictional keratosis, mucocele), five were infectious lesions (subprosthetic stomatitis, middle rhomboid glossitis, chronic periodontitis), four of vascular etiology (vascular malformation), three pigmented lesions (amalgam tattoo and smoking-related melanosis) and three potentially malignant lesions (leukoplakia, solar cheilitis, and lichen planus).

The most frequent location was the tongue with eight cases, followed by the gingiva and jugal mucosa, each with five cases. Four lesions were located on the labial mucosa, two in the palate and the same number was observed in the vermilion border, (Table 1).

Most of the cases were solved only with conventional dental treatment or through pharmacological management. A biopsy was taken in four cases which needed histopathological examination. Due to the complexity of the required surgical procedure, biopsies were taken in the Reference Centre assigned for the different cities that were considered in the execution of this study.

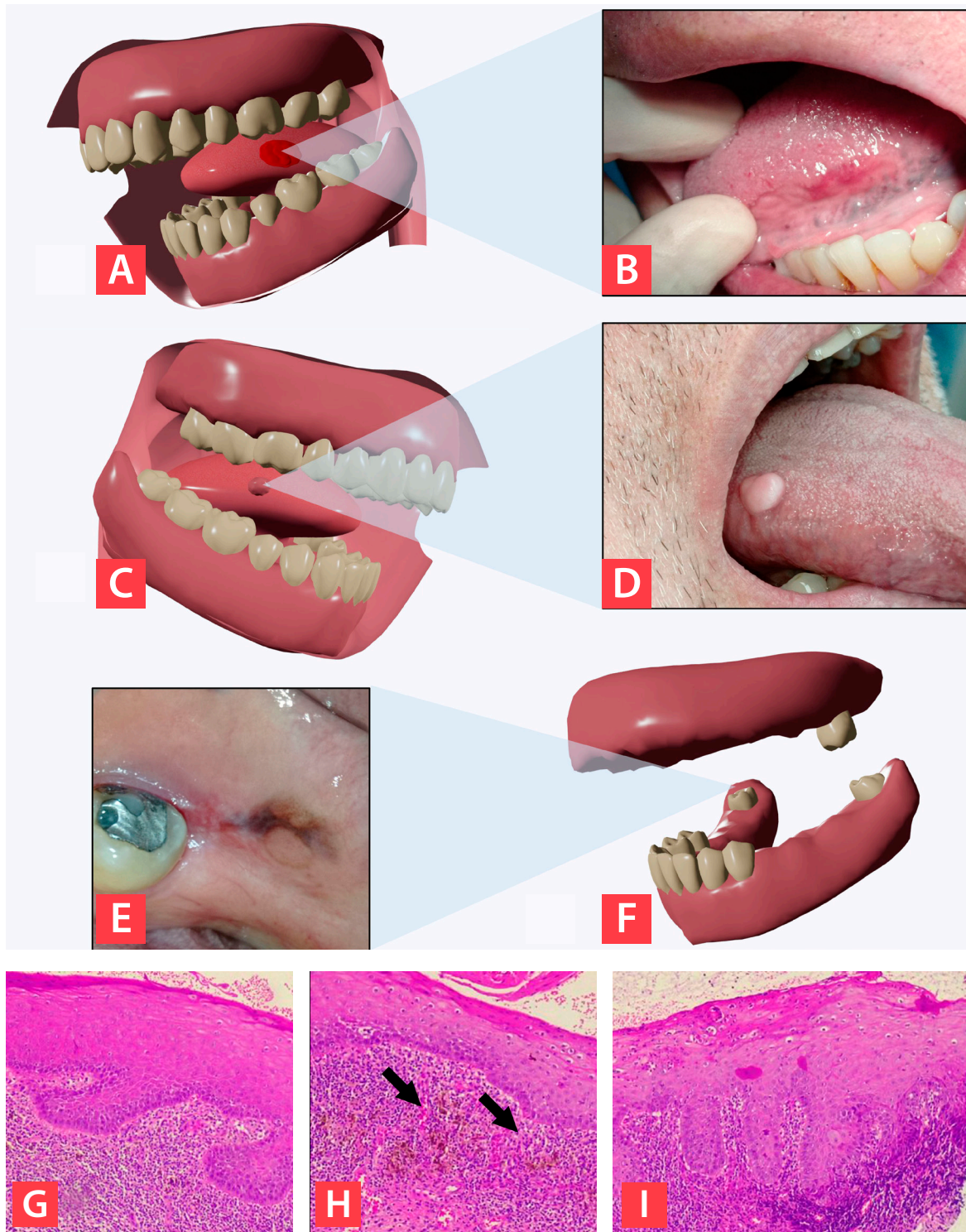
Tissue samples were sent to one of the oral pathologists for laboratory procedure and microscopic analysis. Figure 1 shows details of digital representations of lesions and examples of clinical and histopathology analysis.

Figure 1. Intraoral examination section interface (Soft tissues and mucosa).



A. Scheme of digital representation of most frequent lesions (oral pathology selector). **B.** Display of nested / appended information in an anatomical reference marker associated with the surface of a virtual 3D phantom, which is visualized by the specialist who receives the interconsultation through the platform..

Figure 2. Intraoral examination section interface (Soft tissues and mucosa).



A. Digital representation of a lesion clinically diagnosed as Erythroplasia and the clinical information sent to the specialist. **B.** Clinical appearance of lesion digitally represented in A, in the left border of tongue. **C.** Digital representation of a typical irritation fibroma. **D.** Clinical appearance of lesion digitally represented in C, in the right border of tongue. **E.** Clinical appearance of a pigmented and erosive lesion in the retromolar area, distally to tooth 4.8. **F.** Digital representation by a digital odontogram section. **G,H** and **I.** Shows a pigmented and erosive lesion with a histopathologic analysis showing a sub epithelial lymphocytic infiltrate, melanin pigment and epithelial disorder consistent with mild dysplasia.

DISCUSSION.

The study is related to the early diagnosis of oral cancer in adult patients who participated in a project to implement a platform for priority and emergency dental care in the context of the COVID-19 pandemic.

The purpose of the study was to contribute to early diagnosis of lesions in older patients, including potentially malignant lesions or those suspected of oral cancer, considering that this type of malignant neoplasm is frequently diagnosed in late stages, although the oral cavity is susceptible to visual examination, providing the opportunity to detect these lesions early for the prevention of malignant transformation.

Unfortunately, in many cases this is not achieved due to the difficulties that patients face in accessing dental care.⁵ Teledentistry, an innovative technology that uses advanced telecommunications procedures helps improve oral health care. It facilitates screening, diagnosis and earlier treatment, improving the prognosis,⁶ especially in remote areas where there are no specialists available or where patient's mobility is restricted because of pandemics, natural disasters or difficult geographical access.

Four lesions required biopsy and histopathological report. Squamous cell carcinoma was not found; but one of the lesions showed mild dysplasia, so it required special attention.

This finding is similar to that reported by Haron N *et al.*,³ who developed an application for mobile phones in order to consult oral lesions, identifying precancerous and benign lesions. These devices allowed to minimize the barriers that hinder the early detection of oral cancer, accelerating referral to the specialist that encourages early intervention in this population.⁷

Dentists should consider adapting the use of teledentistry for patient's care as a consultation method to provide a better service to a population, as well as to reduce the contagion of COVID-19, among other risks for the elderly.⁸

CONCLUSION.

This way, through this study it can be concluded that using a teledentistry platform that includes digital representations of oral lesions using different digital markers, together with a mobile system to provide dental care constitutes an excellent tool to treat patients that present oral lesions with potential cancer risk.

Conflict of interests:

The authors declare no conflicts of interest.

Ethics approval:

Study protocol approval was granted by the Universidad de la Frontera Ethics Committee, decision 090/20.

Funding:

This article is part of the project “Semi-presential technological support platform for urgent and priority dental care for the elderly in the context of the COVID-19 pandemic in the Chilean population”, funded by the Contest for Rapid Allocation of Funds of the National Agency of Research and Development (ANID), Reference No. COVID0766, Chile.

Authors' contributions:

Conceptualization: Venegas B, Beltrán V, Rueda S. Research, methodology and supervision: Venegas B, BV, Rueda S, Flores M. Data gathering: Cerda A.

Data analysis: Venegas B, Beltrán V, Rueda S. Writing—original draft: Venegas B, SR. Writing—review and editing: Venegas B, Beltrán V, Rueda S, Cerda A. Image work: Venegas B.

Acknowledgements:

None.

REFERENCES.

1. Santelices Ch MJ, Cárcamo I M, Brenner A C, Montes F R. Cáncer oral en Chile: Revisión de la literatura [Oral cancer: Review of the Chilean literature]. *Rev Med Chil.* 2016;144(6):758-766. doi:10.4067/S0034-98872016000600011
2. Herrera-Serna BY, Lara-Carrillo E, Toral-Rizo VH, do Amaral RC. Efecto de las políticas de control de factores de riesgo sobre la mortalidad por cáncer oral en América Latina [Effect of risk factor control policies on oral cancer mortality in Latin America]. *Rev Esp Salud Publica.* 2019;93:e201907050.
3. Haron N, Zain RB, Nabillah WM, Saleh A, Kallarakkal TG, Ramanathan A, Sinon SH, Razak IA, Cheong SC. Mobile Phone Imaging in Low Resource Settings for Early Detection of Oral Cancer and Concordance with Clinical Oral Examination. *Telemed J E Health.* 2017 Mar;23(3):192-199. doi: 10.1089/tmj.2016.0128. PMID:27541205.
4. Aquilanti L, Santarelli A, Mascitti M, Procaccini M, Rappelli G. Dental Care Access and the Elderly: What Is the Role of Teledentistry? A Systematic Review. *Int J Environ Res Public Health.* 2020 Dec 4;17(23):9053. doi: 10.3390/ijerph17239053. PMID: 33291719; PMCID: PMC7729836.
5. Abati S, Bramati C, Bondi S, Lissoni A, Trimarchi M. Oral Cancer and Precancer: A Narrative Review on the Relevance of Early Diagnosis. *Int J Environ Res Public Health.* 2020 Dec 8;17(24):9160. doi: 10.3390/ijerph17249160. PMID: 33302498; PMCID: PMC7764090.
6. Madi M, Kumar M, Pentapati KC, Vineetha R. Smart-phone based telemedicine: Instant messaging application as a platform for radiographic interpretations of jaw pathologies. *J Oral Biol Craniofac Res.* 2021 Jul-Sep;11(3):368-372. doi: 10.1016/j.jobcr.2021.04.003. PMID: 33996431; PMCID: PMC8093935.
7. Haron N, Zain RB, Ramanathan A, Abraham MT, Liew CS, Ng KG, Cheng LC, Husin RB, Chong SMY, Thangavalu LA, Mat A, Ismail HB, Mahalingam SA, Cheong SC. m-Health for Early Detection of Oral Cancer in Low- and Middle-Income Countries. *Telemed J E Health.* 2020 Mar;26(3):278-285. doi: 10.1089/tmj.2018.0285. PMID: 31081720.
8. Besimo CE, Zitzmann NU, Joda T. Digital Oral Medicine for the Elderly. *Int J Environ Res Public Health.* 2020 Mar 25;17(7):2171. doi: 10.3390/ijerph17072171. PMID: 32218112; PMCID: PMC7177661.