

## Anatomical variations of the maxillary sinus septa of an Iranian population using cone-beam computed tomography: a retrospective study.

Variaciones anatómicas de los tabiques del seno maxilar de una población iraní mediante tomografía computarizada de haz cónico: estudio retrospectivo.

Ali Heidari.<sup>1</sup>  
Fatemeh Salemi.<sup>2</sup>  
Zohre Arefpoor.<sup>3</sup>  
Mohammad Tajik.<sup>4</sup>  
Ali Reza Soltanian.<sup>5</sup>  
Shiva Ghaderi.<sup>6</sup>

### Affiliations:

<sup>1</sup>Dept of Oral and Maxillofacial Surgery, Faculty of Dentistry, Hamadan University of Medical Sciences, Hamadan, Iran.

<sup>2</sup>Dental Implant Research Center, Dept of Oral and Maxillofacial Radiology, Faculty of Dentistry, Hamadan University of Medical Sciences, Hamadan, Iran.

<sup>3</sup>Dept of Oral and Maxillofacial Radiology, Faculty of Dentistry, Zahedan University of Medical Sciences, Zahedan, Iran.

<sup>4</sup>Dept of Oral and Maxillofacial Radiology, Dental School, Shiraz University of Medical Sciences, Shiraz, Iran.

<sup>5</sup>Modeling Of Noncommunicable Diseases Research Center, School of Public Health, Hamadan University of Medical Sciences, Hamadan, Iran.

<sup>6</sup>Dept of Oral and Maxillofacial Radiology, Faculty of Dentistry, Hamadan University of Medical Sciences, Hamadan, Iran.

**Corresponding author:** Zohre Arefpoor. Department of Oral and Maxillofacial Radiology, Faculty of Dentistry, Zahedan University of Medical Sciences, Zahedan, Iran. **Phone:** (98) 9151924167. **E-mail:** zohre.arefpoor@yahoo.com

**Receipt** : 01/30/2020 **Revised:** 04/27/2020  
**Acceptance:** 07/18/2020

### Cite as:

Heidari A, Salemi F, Arefpoor Z, Tajik M, Soltanian AR & Ghaderi S.

Anatomical variations of the maxillary sinus septa of an Iranian population using cone-beam computed tomography: a retrospective study.

J Oral Res 2020; 9(3):171-179.

Doi:10.17126/joralres.2020.033

**Abstract:** This study sought to assess the internal anatomy of the maxillary sinuses and their septa using cone-beam computed tomography (CBCT) in an Iranian population. **Materials and Methods:** Resorption of alveolar bone decreases the height of the maxillary alveolar ridge. This height reduction may be so severe that it warrants ridge augmentation by a sinus lift. Manipulation of the maxillary sinuses, as in sinus lift surgery, requires adequate knowledge about the sinus anatomy. **Results:** Maxillary sinus septum, as an anatomical variation, may complicate the surgical procedures and increase the risk of complications such as sinus membrane perforation. In this retrospective study, 366 sinuses, 190 from females and 176 from males, aged between 10 and 65 years old presenting to the Oral and Maxillofacial Radiology Department of School of Dentistry at Hamadan University of Medical Sciences were evaluated by two oral radiologists. The extension of the maxillary sinuses, presence of septa, number of septa and their location were determined. Data were analyzed using the chi square test (level of significance  $p \leq 0.001$ ). The coefficient of agreement between the two oral radiologists was calculated based on Cohen kappa. Septa were present in 40.5% of the maxillary sinuses, out of which, 31.6% had one, 7.9% had two and 1% had three or more septa; 38% of the septa were horizontal while 62% had an oblique orientation. In total, 184 septa were found in 183 patients; out of which, 91 septa were 2mm to 5mm long while 93 septa were longer than 5mm. **Conclusions:** Comprehensive knowledge about the three-dimensional internal anatomy of the maxillary sinuses acquired by CBCT *prior* to surgical procedures can greatly help to prevent postoperative complications.

**Keywords:** Maxillary sinus; anatomic variation; alveolar ridge augmentation; cone-beam computed tomography; Iran; radiologists.

**Resumen:** Este estudio buscó evaluar la anatomía interna de los senos maxilares y sus septos mediante tomografía computarizada de haz cónico (CBCT) en una población iraní. **Materiales y Métodos:** La resorción del hueso alveolar disminuye la altura de la cresta alveolar maxilar. Esta reducción de altura puede ser tan severa que justifique el aumento de la cresta mediante una elevación de seno. La manipulación de los senos maxilares, como en la cirugía de elevación del seno, requiere un conocimiento adecuado sobre la anatomía del seno.

**Resultado:** El tabique del seno maxilar, como una variación anatómica, puede complicar los procedimientos quirúrgicos y aumentar el riesgo de complicaciones como la perforación de la membrana sinusal. En este estudio retrospectivo, dos radiólogos orales evaluaron 366 senos, 190 de mujeres y 176 de hombres, con edades comprendidas entre 10 y 65 años que se presentaron en el Departamento de Radiología Oral y Maxilofacial de la Facultad de Odontología de Hamadan University of Medical Sciences. Se determinó la extensión de los senos maxilares, la presencia de septos, el número de septos y su ubicación. Los datos se analizaron mediante la prueba de chi cuadrado (nivel de significación  $p \leq 0.001$ ). El coeficiente de concordancia entre los dos radiólogos orales se calculó en base a Cohen kappa. Los septos estaban

presentes en el 40.5% de los senos maxilares, de los cuales, el 31.6% tenía uno, el 7.9% tenía dos y el 1% tenía tres o más septos; El 38% de los septos eran horizontales, mientras que el 62% tenía una orientación oblicua. En total, se encontraron 184 septos en 183 pacientes; de los cuales, 91 septos tenían de 2mm a 5mm de largo, mientras que 93 septos tenían más de 5mm. **Conclusion:** El conocimiento exhaustivo sobre la anatomía interna tridimensional de los senos maxilares adquiridos por CBCT antes de los procedimientos quirúrgicos puede ayudar en gran medida a prevenir complicaciones postoperatorias.

**Palabra Clave:** *Seno maxilar; variación anatómica; aumento de la cresta alveolar; tomografía computarizada de haz cónico; Irán; radiólogos*

## INTRODUCTION.

Implant-supported restorations are the treatment of choice for replacement of the lost teeth due to their high success rate. Implant placement, particularly in the posterior maxilla, may be clinically challenging due to poor quality of bone and pattern of alveolar ridge resorption. An edentulous posterior maxilla with severe bone resorption and sinus pneumatization requires bone augmentation prior to implant placement in order to increase the success rate of treatment with implants. Sinus floor augmentation in partially or fully edentulous patients is performed via different surgical techniques prior to implant placement.<sup>2</sup>

In adults, the maxillary sinuses are pyramid-shaped; the base of the pyramid is the lateral nasal wall while the tip of the pyramid is the zygomatic process of the maxilla.<sup>3</sup>

After tooth extraction, resorption of the alveolar process occurs. Since the maxillary alveolar process forms the sinus floor, assessment of the changes that occur in the maxillary sinus is necessary, especially prior to implant treatment. The sinus floor elevation technique is among the most commonly practiced procedures prior to implant placement in an atrophic posterior maxilla.<sup>4</sup>

One complication of this technique is perforation of the Schneiderian membrane reported in 10%-60% of the cases.<sup>5</sup> Anatomical variations, presence of septa, history of sinus infection and history of sinus surgery are among the factors that increase the risk of perforation of the Schneiderian membrane.

Septa are present in 13%-35% of maxillary sinuses.<sup>1</sup> A maxillary sinus septum is a thin wall of cortical bone within the maxillary sinus, which divides the maxillary

sinus into at least two compartments and plays an important role in structural strength of the sinus bone.<sup>4</sup>

On radiographic images of the maxillary sinuses, septa are seen in the form of one or several transverse radiopaque lines.<sup>3</sup> Presence of septa increases the risk of membrane perforation during sinus lift surgery. Therefore, information about the prevalence, location and orientation of septa helps the surgeon to better recognize the risks of surgical procedures in this area.<sup>5</sup>

In the 20<sup>th</sup> Century, clinical assessments and two-dimensional radiographic modalities were commonly used as diagnostic tools in implant therapy. However, data collected by using these tools were incomplete and of poor quality. To overcome the limitations of these techniques, three-dimensional images such as computed tomography (CT) scans were introduced to provide more comprehensive information, compared to the two-dimensional radiographic modalities; however, CT emits higher radiation to the patient.<sup>6</sup> In recent decades, cone-beam computed tomography (CBCT) was introduced as an excellent imaging modality for the assessment of anatomical structures with much lower radiation doses than CT.<sup>7</sup>

CBCT has advantages over CT such as having isotropic and dimensionally smaller voxels, enabling assessment of structures with tenth of a millimeter accuracy and obtaining non-orthogonal images.<sup>8</sup> Accurate information about the prevalence of septa can help to predict the potential complications and enables correct treatment planning. Considering the gap of information regarding maxillary sinus septa, this study aimed to assess the prevalence and frequency of maxillary sinus septa on CBCT images.

## MATERIALS AND METHODS.

In this retrospective study, CBCT scans of 366 sinuses were evaluated, 190 from females and 176 from males, aged between 10 and 65 years old presenting to the Oral and Maxillofacial Radiology Department of School of Dentistry at Hamadan University of Medical Sciences were evaluated by two oral radiologists.

The images were selected randomly based on the following inclusion criteria: Visibility of at least 2cm above the sinus floor, and no motion or scattering artifacts. Images exhibiting changes in the morphology of sinus walls due to trauma or pathologic conditions were excluded from the study. All CBCT scans were obtained using NewTom 3G CBCT system (NewTom, Verona, Italy). The technical exposure parameters settings were 110 kVp, 0/5 mA, 1/8 mAs range, scanning time 3/6s, 6 and 12-inch field of view, 0.25 mm voxel size. This study was conducted between 2016 and 2017.

All images were assessed by a second-year post-graduate student of oral and maxillofacial radiology and an oral and maxillofacial radiologist with five years of clinical experience. Panoramic images were reconstructed of CBCT scans to assess the anterior extension of the maxillary sinuses. The anterior border of the sinus was determined where it had  $\leq 5$ mm distance from the apex of teeth. The first tooth with an apex  $\leq 5$ mm away from the sinus floor was considered as the anterior limit. The anterior limit of the sinus in edentulous patients was the distal of the nasal ala. The middle limit of the sinus was the pupil, and the posterior limit (sinus extension) was the maxillary tuberosity.<sup>1</sup>

The axial, sagittal images were reconstructed to visualize the septa. In the case of detecting a septum, the axial section image was used to determine its longitudinal axis. If the longitudinal axis of the septum had a  $90^\circ \pm 5^\circ$  angle relative to the mid-palatal line, the septum was considered to be oriented horizontally. If this angle was  $>95^\circ$  or  $<85^\circ$ , the septum was considered to have an oblique orientation (Figure 1A).

Sagittal images were reconstructed so they were perpendicular to the longitudinal axis of the septum on axial sections. The location of septum was determined on sagittal sections such that if it was located mesial to the first premolar tooth, it was considered to be in the anterior segment. If it was located between the mesial of first premolar and distal of second premolar, it was considered to be in the middle segment and if

it was located distal to the second premolar, it was considered to be in the posterior segment (Figure 1B).

On sagittal sections, the length of septum was measured from its most inferior point in the sinus floor to its tip on a section with the longest image of septum using the ruler feature in the software. Structures  $<2$ mm were not considered as septa. The collected data were recorded in datasheets and analyzed using the chi square test.

Qualitative variables, such as sex and length of septa, were described as frequency and percentage. Quantitative variables (e.g., age) were reported as percentage. The chi-square test was used to analyze the presence or absence of septa based on the demographic information of patients. The Cohen's kappa was used to assess the coefficient of agreement between the two examiners.

## RESULTS.

Table 1 shows sex, age, dentition status and existence of septa in the assessed 366 maxillary sinuses from 183 patients as evaluated on CBCT scans.

Of 183 patients evaluated in this study, 129 were between 10 to 40 years, and 54 were in the age range of 40 to 65 years. Of 183 patients evaluated in this study, 102 (55.7%) were partially edentulous, 14(7.7%) were fully edentulous and 67(36.6%) had complete dentition (except for third molars).

Of 183 right maxillary sinuses, 75(41%) had septa while 108(59%) did not have septa. Of 183 left maxillary sinuses, 73(39.9%) had septa while 110(60.1%) did not have septa. Of a total of 366 sinuses, 148(40.5%) had septa and 218(59.5%) did not have septa.

Regarding the extension of the maxillary sinuses, of a total of 366 sinuses, 54(14.7%) had extended anteriorly to the apex of the canine tooth, 41(11.2%) had extended anteriorly to the apex of first premolar tooth, 175(47.9%) had extended anteriorly to the apex of second premolar tooth and 96(26.2%) had extended anteriorly to the apex of first molar tooth.

Posteriorly, all sinuses had extended to the distal of third molar tooth and maxillary tuberosity.

Of all 184 septa, 9 (4.8%) were anterior, located at the site of canine tooth, 51 (27.7%) were at the site of premolars (middle region) and 124 (67.5%) were at the site of molar teeth (posterior region).

Table 2 shows longitudinal axis of septa on CBCT and their inferred position.

Table 3 shows length of septa. Table 4 shows sex, age and dentition status had no significant association with presence of septa ( $p>0.05$ ).

As depicted in Figure 2, dentition status had no significant association with the extension of the maxillary sinuses ( $p=0.9$ ).

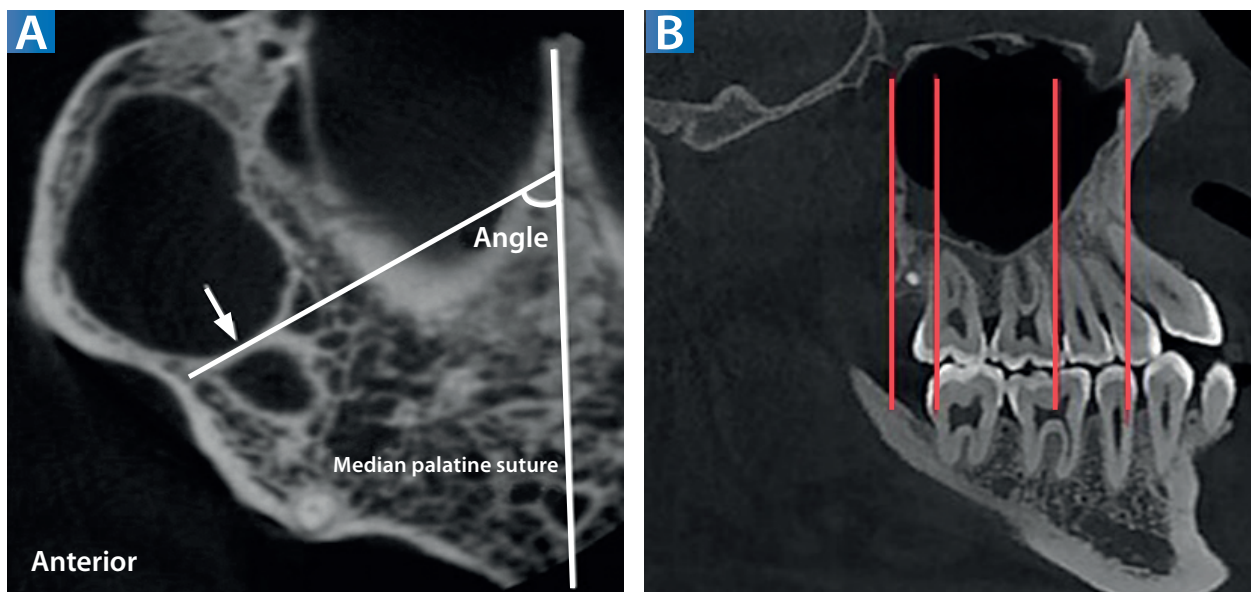
Table 5 shows a significant association between the presence of septa in the right and left maxillary sinuses ( $p<0.05$ ). Similarly, in the right and left sides, 58(31.7%)

sinuses had one septum. A total of 29 sinuses had two septa including 14(7.7%) right maxillary sinuses and 15(8.2%) left maxillary sinuses.

Three sinuses had three septa (1.6%), which were all in the right side. No sinus had four or more septa.

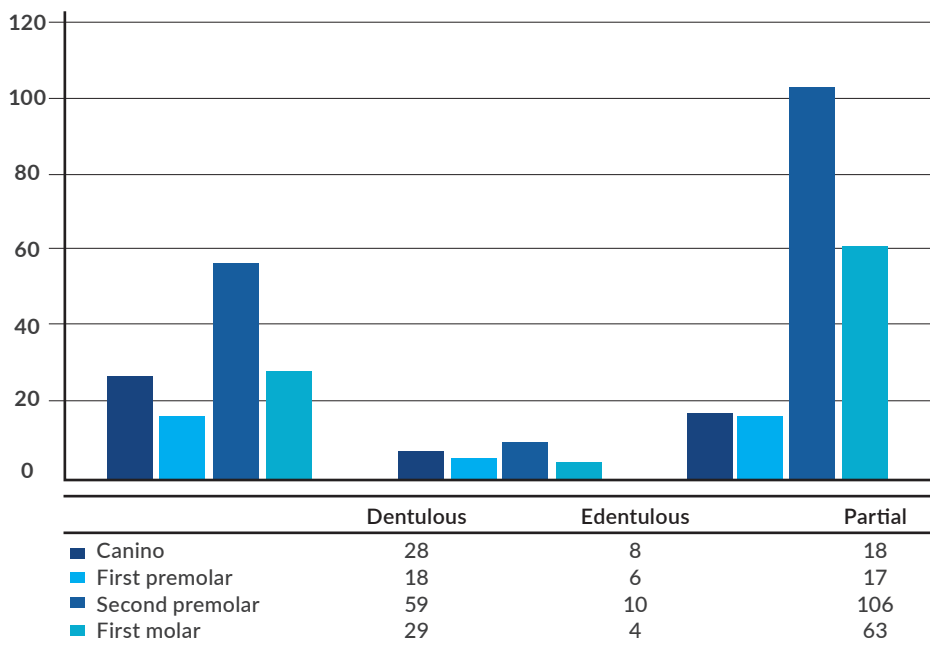
A significant association was noted between the number of septa in the right and left sides ( $p=0.001$ ). The two evaluators had excellent inter-observer agreement according to Cohen Kappa (0.88).

**Figure 1.** CBCT axial section and CBCT sagittal section.



A: Calculation of the angle of maxillary sinus septa. B: Locations of the septa were categorized into anterior, medial, and posterior regions.

**Figure 2.** Correlation of dentition status and extension of the maxillary sinus.



**Table 1.** Sex, age, dentition status of patients and the maxillary sinus septa as assessed on CBCT.

		Number	Percentage
Sex	Male	176	51.9
	Female	190	48.1
	Total	366	100
Age	10-40years	129	70.5
	>40	54	29.5
	Total	183	100
Dentition status	Complete dentition	67	36.6
	Partially edentulous	102	55.7
	Edentulous	14	7.7
	Total	183	100
Existence of septa	Yes	148	40.5
	No	218	59.5
	Total	366	100

**Table 2.** Position of the septa in the right and left sinuses, as inferred from their longitudinal axis on CBCT.

Sinus	Position	Number	Percentage
Right maxillary sinus	Horizontal	40	41.2
	Oblique	57	58.8
	Total	97	100
Left maxillary sinus	Horizontal	30	68.9
	Oblique	57	31.1
	Total	87	100
Total	Horizontal	70	38
	Oblique	114	62
	Total	184	100

**Table 3.** Length of septa in right and left maxillary sinuses.

	Length	Number	Percentage
Right maxillary sinus	2-5mm	53	54.5
	>5mm	44	45.5
Total		97	100
Left maxillary sinus	2-5mm	38	43.5
	>5mm	49	56.5
Total	Total	87	100
Total	2-5mm	91	49.5
	>5mm	93	50.5
	Total	184	100

**Table 4.** Sex, age and dentition status of patients and their correlation with presence/absence of septa.

Patient characteristics		Presence of septa		Statistically significance level
		NO (%)	YES (%)	
Sex	Male	104 (59.1)	72 (40.9)	<i>p</i> -value=0.77
	Female	115 (60.0)	76 (44.5)	
	Total	219 (59.6)	148 (47.6)	
Age (years)	10-40	161 (62.4)	97 (37.6)	<i>p</i> -value=0.122
	40 or older	58 (53.7)	50 (46.3)	
	Total	219 (59.8)	147 (40.2)	
Dental condition	Dentate	82 (37.44)	52 (35.13)	<i>p</i> -value=0.9
	Edentulous	16 (7.3)	13 (8.78)	
	Partially edentulous	121 (55.25)	83 (56.08)	
	Total	219 (59.8)	148 (47.6)	

**Table 5.** Presence septa of right and left maxillary sinuses.

		Presence of septa in the left sinus		
		No (n %)	Yes (n %)	Total
Presence of septa in the right sinus	No (n%)	85 (78.7)	23 (21.3)	108 (100)
	Yes (n%)	26 (34.7)	49 (65.3)	75 (100)
	Total	111 (60.7)	72 (39.3)	183 (100)

*p*-value=0/001

## DISCUSSION.

Panoramic radiography, CT and CBCT can be used for radiographic detection of maxillary sinus septa.<sup>3</sup> Panoramic radiography may result in misdiagnosis regarding presence/absence of septa in 12%-44% of the cases due to overlapping and superimposition of anatomical structures.<sup>9</sup>

With the advent of cone beam computed tomography (CBCT), the surgeon now is able to review the anatomical structures prior to surgery.<sup>10</sup> In contrast to panoramic radiography, CT and CBCT provide accurate and definite information about the presence/absence of septa, CBCT provides high-resolution images of fine bony structures with less radiation than CT.<sup>1</sup>

The problems related to superimposition and magnification, which are inherent to panoramic radiography, do not exist in CBCT; therefore, CBCT can be used as the three-dimensional imaging modality of choice for visualization of antral septa.

Implant placement is challenging in patients with decreased height of the maxillary alveolar bone. Sinus lift surgery has been suggested to overcome this problem. Several anatomical details are relevant for sinus lift procedures, including the residual ridge height, the maxillary sinus shape, the presence of an artery, and the presence, location, and appearance of sinus septa.<sup>11</sup>

However, the sinus lift technique and all other surgical interventions in the maxillary region require thorough and comprehensive knowledge about the anatomy and variations of the maxillary sinuses. Septa are bony walls within the sinus cavity; if present, they may complicate the surgical procedures conducted in the sinus area.<sup>2</sup>

This study did not consider bony structures less than 2mm in length as septa since they are too small to complicate the surgical procedures. In terms of sample size, a total of 366 sinuses were evaluated in our study,



which is larger than the sample size of most previous studies on this topic.<sup>1,3,12</sup>

From the total, 190 maxillary sinuses belonged to females and 176 belonged to males, a relatively equal gender distribution. Regarding the overall prevalence of septa, of a total of 366 sinuses, 148 (40.5%) had septa; the prevalence of septa was 48% in a study by Irinakis *et al.*,<sup>5</sup> while this value was 16%-48% in other studies.<sup>4,9</sup>

Ilguy *et al.*,<sup>12</sup> reported the prevalence of septa as 55.2% while Orhan *et al.*,<sup>7</sup> reported 58%. These differences may be related to the use of different imaging modalities as well as different study populations. Regarding the number of septa in each sinus, data revealed that irrespective of the number of sinuses without septa (50.5%), most sinuses that had septa had one septum only (n=116 sinuses, 31.6%); while 29 sinuses (7.9%) had two septa and only three sinuses (1%) had three septa. No sinus had more than three septa.

Sakhdari *et al.*,<sup>8</sup> reported that 44.8% of maxillary sinuses had at least one septum while 55.2% did not have any septa. Tadinada *et al.*,<sup>1</sup> reported that 20 sinuses (27.7%) had one single septum, 17 sinuses (23.6%) had two septa and five sinuses (6.9%) had three septa while one sinus (1.3%) had four septa.

We evaluated patients in two age groups, which has not been done in similar previous studies. This was performed to assess and compare the prevalence of septa in the middle aged and younger age group. The highest number of sinuses evaluated in our study were found in those aged 40 and below, while the lowest number belonged to those  $\geq 40$  years (and up to 65).

There was no patient under the age of 10 in our study since such cases were excluded due to having primary dentition. There was no case over 65 years of age in our study because of low demand for CBCT in this age group or their exclusion because of having pathological lesions in the area. In the age group of 10 to 25 years, 39.8% had maxillary sinus septa.

This rate was 35.7% in the age group of 25 to 40 years and 46.3% in the age group of 40 to 65 years. Analysis of the data revealed no significant difference regarding the presence of septa among different age groups ( $p=0.24$ )

In this study patients were classified according to their dentition, and the prevalence of septa was evaluated based on the type of dentition. Of a total

of 183 patients, 36.6% had complete dentition while 7.7% were completely edentulous; 55.7% were partially edentulous.

Statistical analysis found no significant association between the type of dentition and presence of septa. However, this finding was in contrast to the statements regarding the formation of septa secondary to tooth extraction.<sup>13</sup>

This finding was also contrary to the results of Qian *et al.*,<sup>4</sup> and Faramarzie *et al.*,<sup>14</sup> who reported that the prevalence of maxillary sinus septa in edentulous patients was higher than in dentate patients.

Such a difference in the prevalence of septa in edentulous and dentate patients may be related to the fact that secondary formation of septa is related to irregular pneumatization of the sinus floor following tooth loss.

In contrast to the afore-mentioned findings, we believe that our results confirm septa are derived from appendages formed during fetal development,<sup>15</sup> as there was an absence of a significant difference in prevalence of septa among different age groups in our study. Assessment of the prevalence of septa in the right and left sides revealed no significant difference ( $p=0.01$ ). Similarity the prevalence of septa in the right and left maxillary sinuses may indicate that septa are congenital and have a fetal origin rather than being acquired.

Of a total of 184 septa found in the maxillary sinuses in our study, the longitudinal axis of 38% was horizontally oriented relative to the mid-palatal line while 62% had oblique orientation. None of the previous studies performed such classification.

Regarding the location of septa, our study demonstrated that most septa (67.5%) were at the site of molar teeth followed by premolars (27.7%) and canine teeth (4.8%). Therefore, the risk of finding septa is higher in surgical procedures conducted in the posterior maxilla, and this must be considered when performing such interventions.

Dragan *et al.*,<sup>2</sup> found the highest number of septa in the posterior region (55.4%); whereas, some others reported that the highest number of septa were in the anterior and the middle region.<sup>7,8,16-19</sup> Use of CBCT in our study enabled accurate assessment of the location of septa in the axial, coronal and sagittal planes.

From the total, 49.5% of the septa were 2mm to 5mm long while 50.5% were longer than 5mm, as such

septa may complicate the surgical procedures. Aside from the presence/absence of septa in 366 maxillary sinuses, we also evaluated the anterior extension of the sinuses, which had not been done before.

Results of this study indicate that in a considerable percentage of patients (about 26%), maxillary sinuses had extended anteriorly to the first premolar tooth or even further anteriorly. Moreover, type of dentition had a significant association with the extension of maxillary sinuses ( $p=0.001$ ).

In other words, partially edentulous individuals showed greater anterior extension of the maxillary sinuses compared to completely dentate patients (28% versus 8%). This is due to the pneumatization of maxillary sinuses following tooth extraction.

Further studies with more samples may be necessary in the future to evaluate the correlation between the orientation of the septa and rate of complications in the outcome of a sinus augmentation surgical procedure for implant placement.

## CONCLUSION.

The maxillary sinus septa have variations in prevalence, number, location and shape.

Considering the fact that presence of septa can affect the incidence of preoperative complications as well as the success rate of surgical procedures of the sinus, accurate three-dimensionally reconstructed CBCT images can greatly help.

**Conflict of interests:** The author declares no conflict of interest.

**Ethics approval:** This study was approved by the Ethics Committee of Hamadan University of Medical Sciences (IR.UMSHA.REC.1395.867).

**Funding:** The authors declared that this study received no financial support.

**Authors' contributions:** Surgical and Medical Practices: Heidari, Salemi, Arefpoor, Tajik, Soltanian, Ghaderi. Concept: Heidari, Salemi, Arefpoor, Tajik, Soltanian, Ghaderi, Design: Heidari, Salemi, Arefpoor, Tajik, Soltanian, Ghaderi. Data Collection or Processing: Heidari, Salemi, Arefpoor, Tajik, Soltanian, Ghaderi. Analysis or Interpretation: Heidari, Salemi, Arefpoor, Tajik, Soltanian, Ghaderi. Literature Search: Heidari, Salemi, Arefpoor, Tajik, Soltanian, Ghaderi. Writing: Arefpoor.

**Acknowledgements:** The authors would like to thank the research deputy of this university and school of dentistry for their support.



## REFERENCES.

1. Tadinada A, Jalali E, Al-Salman W, Jambhekar S, Katechia B, Almas K. Prevalence of bony septa, antral pathology, and dimensions of the maxillary sinus from a sinus augmentation perspective: A retrospective cone-beam computed tomography study. *Imaging Sci Dent.* 2016;46(2):109-15.
2. Dragan E, Odri GA, Melian G, Haba D, Olszewski R. Three-Dimensional Evaluation of Maxillary Sinus Septa for Implant Placement. *Med Sci Monit.* 2017;23:1394-1400.
3. Değerli Ş, Alkurt MT, Peker I, Cebeci ARİ, Sadık E. Comparison of cone beam computed tomography and panoramic radiographs in detecting maxillary sinus septa. *J Istanbul Univ Fac Dent* 2016;50(3):8-14.
4. Qian L, Tian X-m, Zeng L, Gong Y, Wei B. Analysis of the morphology of maxillary sinus septa on reconstructed cone-beam computed tomography images. *J Oral Maxillofac Surg.* 2016;74(4):729-37.
5. Irinakis T, Dabuleanu V, Aldahlawi S. Complications during maxillary sinus augmentation associated with interfering septa: a new classification of septa. *Open Dent J.* 2017;11:140.
6. Lozano-Carrascal N, Salomó-Coll O, Gehrke SA, Calvo-Guirado JL, Hernández-Alfaro F, Gargallo-Albiol J. Radiological evaluation of maxillary sinus anatomy: A cross-sectional study of 300 patients. *Ann Anat.* 2017;214:1-8.
7. Orhan K, Seker BK, Aksoy S, Bayindir H, Berberoğlu A, Seker E. Cone beam CT evaluation of maxillary sinus septa prevalence, height, location and morphology in children and an adult population. *Med Princ Pract.* 2013;22(1):47-53.
8. Sakhdari S, Panjnoush M, Eyvazlou A, Niktash A. Determination of the prevalence, height, and location of the maxillary sinus septa using cone beam computed tomography. *Implant Dent.* 2016;25(3):335-40.
9. Maestre-Ferrín L, Galán-Gil S, Rubio-Serrano M, Peñarrocha-Diago M, Peñarrocha-Oltra D. Maxillary sinus septa: a systematic review. *Med Oral Patol Oral Cir Bucal.* 2010;15(2):e383-6.
10. Sonoda T, Yamamichi K, Harada T, Yamamichi N. Effect of staged crestal maxillary sinus augmentation: A case series. *J Periodontol.* 2020;91(2):194-201.
11. Yu S-J, Lee Y-H, Lin C-P, Wu AY-J. Computed tomographic analysis of maxillary sinus anatomy relevant to sinus lift procedures in edentulous ridges in Taiwanese patients. *J Periodontal Implant Sci.* 2019;49(4):237-47.
12. Ilguy D, Ilguy M, Dolekoglu S, Fisekcioglu E. Evaluation of the posterior superior alveolar artery and the maxillary sinus with CBCT. *Braz Oral Res.* 2013;27(5):431-7.
13. Velásquez-Plata D, Hovey LR, Peach CC, Alder ME. Maxillary sinus septa: a 3-dimensional computerized tomographic scan analysis. *Int J Oral Maxillofac Implants.* 2002;17(6).
14. Faramarzie M, Babaloo AR, Oskouei SG. Prevalence, height, and location of antral septa in Iranian patients undergoing maxillary sinus lift. *J Adv Periodontol Implant Dent.* 2018;1(1):43-7.
15. Maestre-Ferrín L, Carrillo-García C, Galán-Gil S, Peñarrocha-Diago M, Peñarrocha-Diago M. Prevalence, location, and size of maxillary sinus septa: panoramic radiograph versus computed tomography scan. *J Oral Maxillofac Surg.* 2011;69(2):507-11.
16. Park Y-B, Jeon H-S, Shim J-S, Lee K-W, Moon H-S. Analysis of the anatomy of the maxillary sinus septum using 3-dimensional computed tomography. *J Oral Maxillofac Sur.* 2011;69(4):1070-8.
17. Neugebauer J, Ritter L, Mischkowski RA, Dreiseidler T, Scherer P, Ketterle M, et al. Evaluation of maxillary sinus anatomy by cone-beam CT prior to sinus floor elevation. *Inter J OralMaxillofac Impl.* 2010;25(2).
18. Shahidi S, Zamiri B, Danaei SM, Salehi S, Hamedani S. Evaluation of anatomic variations in maxillary sinus with the aid of cone beam computed tomography (CBCT) in a population in south of Iran. *J Dent.* 2016;17(1):7.
19. Chen M, Xie Y, Xie H, Wang G, He J. Cone-beam CT study of bone septa during maxillary sinus lift among Changzhou population. *Shanghai kou qiang yi xue= Shanghai journal of stomatology.* 2016;25(1):77-81.