

Reporte de Caso

Vascular leiomyoma affecting the lip: report of a case and an updated analysis of the 78 cases reported in the literature

Leiomioma vascular que afecta el labio: reporte de un caso y un análisis actualizado de los 78 casos reportados en la literatura

Leiomioma vascular que afeta o lábio: relato de um caso e análise atualizada dos 78 casos relatados na literatura

Melaine de Almeida Lawall¹✉, Erika Martins-Pereira²✉, Joana Albuquerque-Bastos-de-Sousa³✉, Raisa Sales-de-Sa⁴✉

1. Profesor de Doctorado en el Departamento de Morfología, Curso de Odontología, Universidad Federal de Maranhão- UFMA.

2. Profesor de Doctorado en el Departamento II, curso de Odontología, Universidad Federal de Maranhão- UFMA.

3. Estudiante de maestría en Odontología, Universidad Federal de Maranhão- UFMA.

4. Estudiante de doctorado, Universidad Estatal de Campinas, UNICAMP.

Fecha correspondencia:

Recibido: febrero de 2020.

Aceptado: junio de 2020.

Forma de citar:

Lawall MA, Martins-Pereira E, Albuquerque-Bastos-de-Sousa J, Sales-de-Sa R. Vascular leiomyoma affecting the lip: report of a case and an updated analysis of the 78 cases reported in the literature. Rev. CES Odont 2020; 33(2): 175-186.

Open access

© Derecho de autor

Licencia creative commons

Ética de publicaciones

Revisión por pares

Gestión por Open Journal System

DOI: [http://dx.doi.org/10.21615/](http://dx.doi.org/10.21615/cesodon.33.2.15)

cesodon.33.2.15

ISSN 0120-971X

e-ISSN 2215-9185

Abstract

Vascular Leiomyoma (VL) is a benign soft tissue tumor rarely observed in oral tissues. The aim of this paper is to present a new case of vascular leiomyoma of the lip (VLL), describing its clinical, microscopical, and immunohistochemical features, and review the literature on the tumor. A 27-year-old woman presented with a small painful lesion on lower lip mucosa. Excisional biopsy revealed a well-circumscribed, encapsulated mass formed by small and fusiform cells. Immunohistochemistry analysis revealed intense and diffuse expression of smooth muscle actin (SMA) within the tumor cells and CD34 immunoreactivity of the endothelial cells lining the vascular spaces, indicating the presence of blood vessels. A final diagnosis of VLL was established. No signs of recurrence were observed after five years of follow-up. Although VLL is a rare lesion, it must be considered in the differential diagnosis of nodular lesions on lower and upper lips.

Keywords: Lip neoplasms, vascular neoplasms, vascular leiomyoma.

Resumo

O Leiomioma Vascular é um tumor benigno de tecidos moles raramente observado nos tecidos da cavidade bucal. O objetivo desse artigo é apresentar um novo caso de um leiomioma vascular no lábio (LVL), descrevendo seus achados clínicos, microscópicos e imunoistoquímicos, e revisar a literatura sobre o tumor. Uma mulher de 27 anos de idade se apresentou com uma pequena lesão dolorosa na mucosa do lábio inferior. A biópsia excisional revelou um massa encapsulada e bem circunscrita, formada por células pequenas e fusiformes. A análise imunoistoquímica revelou

expressão intensa e difusa de actina musculo liso (AML) nas células tumorais e imunorreatividade para CD34 em células endoteliais que revestem espaços vasculares, indicando a presença de vasos sanguíneos. O diagnóstico final de LVL foi estabelecido. Não foram observados sinais de recorrência após cinco anos de acompanhamento. Embora o LVL seja uma lesão rara, deve ser considerada no diagnóstico diferencial de lesões nodulares nos lábios inferior e superior.

Palavras chave: Neoplasia de lábio, neoplasia vascular, leiomioma vascular.

Resumen

El leiomioma vascular (LV) es un tumor benigno de tejido blando que rara vez se observa en los tejidos orales. El objetivo de este trabajo es presentar un nuevo caso de leiomioma vascular del labio (VLL), describiendo sus características clínicas, microscópicas e inmunohistoquímicas, y revisar la literatura sobre el tumor. Una mujer de 27 años presentó una pequeña lesión dolorosa en la mucosa del labio inferior. La biopsia escisional reveló una masa encapsulada bien circunscrita formada por células pequeñas y fusiformes. El análisis de inmunohistoquímica reveló una expresión intensa y difusa de actina del músculo liso (AME) dentro de las células tumorales y la inmunorreactividad CD34 de las células endoteliales que recubren los espacios vasculares, lo que indica la presencia de vasos sanguíneos. Se estableció un diagnóstico final de VLL. No se observaron signos de recurrencia después de cinco años de seguimiento. Aunque VLL es una lesión rara, debe considerarse en el diagnóstico diferencial de las lesiones nodulares en los labios inferior y superior.

Palabras clave: neoplasia labial, neoplasia vascular, leiomioma vascular.

Introduction

Vascular leiomyoma (VL) is a smooth muscle benign tumor. It frequently occurs in the female genital tract and lower extremities, with skin and stomach being less commonly affected. The head and neck region lack smooth muscle; therefore the occurrence of VL in this area is extremely rare, accounting for less than 1% of all lesions (1-5). The most frequent locations in the oral cavity are the lips and the tongue (4-7).

Vascular leiomyoma of the lip (VLL) can appear at any age; however, there is a peak of incidence between the 5th and 6th decades of life, with over 76 percent being found in patients older than 40 years. It shows a predilection for males. Clinically, lip lesions present as a submucosal, firm, single, slow-growing, painless nodule. The color may vary from pale red to purplish, and the size rarely exceeds two centimeters (7-10). Due to the clinical presentation, VLL may mimic other mesenchymal or salivary gland tumor-like lesions, as well as traumatic lesions (3-7).

Histopathological analysis is essential for the definitive diagnosis of these lesions, which may present the following subtypes: solid, vascular and/or epithelioid. Even with these well-defined variables, immunohistochemical analysis is necessary in some cases to define the diagnosis and conduct the treatment. Conservative surgical excision is the treatment of choice, and the prognosis is excellent (2-7,11).

Case Report

A 27-year-old black woman was referred for evaluation at the School of Dentistry of the Federal University of Maranhão complaining of a small enlargement in the lower lip mucosa. The lesion appeared as a non-ulcerated circumscribed exophytic mass measuring approximately 8 mm in diameter, which has been present for one year. The painful white nodule had a smooth surface, resilient consistency, well-defined borders, and was slightly raised from the surrounding oral mucosa (Figure 1). The patient did not describe any episode of ruptures or release of any fluid content. The rest of the oral cavity was healthy. The medical history was unremarkable. Despite this, a clinical diagnosis of mucocele versus benign tumor was made, and the lesion was surgically excised under local anesthesia. The postoperative course of the patient was uneventful after a 10 days follow-up. The tissue was completely healed, and there was no sign of a scar.

Gross examination of the formalin-fixed specimen revealed one piece of smooth brown tissue measuring on the aggregate $0.9 \times 0.6 \times 0.4$ cm. Histological examination with hematoxylin and eosin stain showed a well-circumscribed, encapsulated mass formed by small and fusiform cells, with uniform, monochromatic, spindles nucleus, and blunt ends. There was neither nuclear atypia nor mitotic activity.

Due to the similarity of the histopathological profile with other neoplasms such as those with a fibroblastic and neural lineage, immunohistochemistry was necessary to confirm the diagnosis. The immunohistochemical study revealed intense and diffuse expression of smooth muscle actin (SMA) within the tumor cells and CD34 immunoreactivity of the endothelial cells lining the vascular spaces, indicating the presence of blood vessels (Figure 1). Based on these findings, a diagnosis of oral vascular leiomyoma was made. Nowadays, five years after the excision of the lesion, no signs of recurrence are observed.

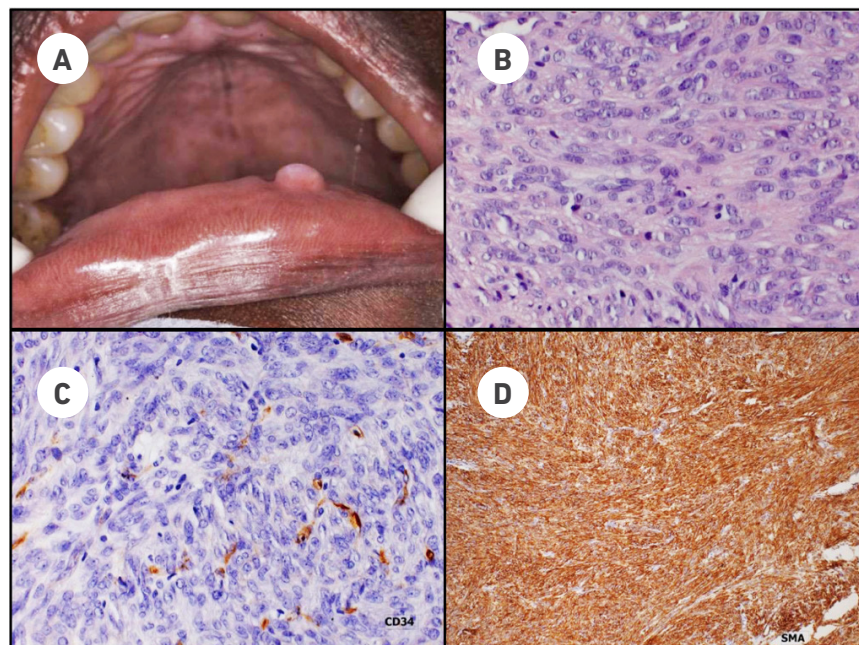


Figure 1. Clinical and histological features of the lesion

A. clinical characteristics of the lesion, **B.** spindle cells with pale stained elongated nuclei and blunt termination, **C.** immunoreactive positivity of endothelial cells lining the vascular spaces, indicating the presence of blood vessels, **D.** Immunohistochemical reactivity for diffuse and strong SDMA for tumor cells, indicating the large amount of smooth muscle cells.

Discussion

Oral leiomyoma is a rare tumor first described by Blanc in 1884 (4, 5). It is characterized by a neoplastic proliferation of mature smooth muscle cells associated with a variable amount of blood vessels (2, 4, 11). Its etiology is uncertain; however, some authors have associated its development with the medial tunic of smooth muscle blood vessel walls, and therefore it is called vascular leiomyoma or angioleiomyoma (12). In addition, the literature suggests other possible sources, such as heterotopic embryonic tissues, circumvallated papillae, and lingual ducts; origins that cannot be associated with the lesion presented in this report due to its location (3, 13, 14).

According to the literature, the majority of oral leiomyomas are observed in the lips, tongue, hard and soft palate, and with less frequency in the cheek. (15, 16). Some authors report the lip as the most affected area (17), while others report the tongue (16, 18-20). The small number of case series reported can explain this difference (7-10, 16, 21, 22).

The involvement of the labial region is extremely uncommon, with only 78 biopsy-proven cases of VLL reported in the literature (Table 1). In 1959, Duhig & Ayer described the first two cases affecting the lip in a series of 61 skin cases, and the last case was reported by Matiakis et al. in 2018 (23).

Although this case presented in the third decade of life, the review of the cases of VLL evidenced that 58,7% of them (n=37) occur in the fifth and sixth decades of life (Table 1), similarly to what has been reported in previous studies (7, 9, 10, 16, 24, 25). Considering only the cases of lip leiomyomas, other authors reported a higher prevalence in the third and fourth decades of life (8, 22, 26). The age of 63 out of 78 patients could be retrieved from the literature, and their mean age was 47.7 years. Vascular leiomyomas are particularly rare in children and adolescents (27, 28). In the present review, the youngest patient was 10 years old and the oldest was 83 years old, and only three cases were observed in adolescents (Table 1).

Regarding the gender, 41 cases were seen in males and 25 in females (Table 1), yielding a male to female ratio of 1.64:1. A similar gender distribution has been previously reported in the literature (7-9, 29). However, some authors reported a slight predilection for females (4, 5).

In the presented study, similarly to almost all previous reports of VLL, the tumor was less than 2 cm in diameter (Table 1). The size of the lesion in 55 out of 79 patients could be retrieved from the literature, and only one case reported a bigger size than 2 cm (30). According to Wang et al. (2004), the characteristic small tumor size in most vascular leiomyomas may be due to their superficial location and slow-growing nature (9).

Pain was not a characteristic finding in VLL, and only 3 patients had this complaint besides the case described in this report (Table 1). The pain has been reported as intermittent or severe on palpation (30-32). There are three theories that try to explain the pain in leiomyomas. The first relates the pain to contraction of smooth muscle vessels, which may cause local ischemia, particularly in solid-type tumors (33). The second connects the pain to the compression of nerves accompanying the blood vessels in the lesion (34), and the third is related to a secondary mild to moderate inflammation of the tumor (1,21,34). None of these theories was definitive to explain our case.

Clinically, VLL are characterized by a small, well-delimited, superficial, and slow-growing unspecific mass, ranging from 0.5 to 6 cm in size. The color of the lesion is varied, depending on its vascularization and its location (36). This diagnosis is hardly considered when a slow-growing, non-ulcerated asymptomatic mass is observed on the lip. Moreover, the labial lesions may present a varied clinical appearance with no specific diagnostic aspects (Table 1), which lead to a wide range of misdiagnosis, including mucocele (7,8,16,26,35,37-42), hemangioma (7,8,25,35,43,44), pleomorphic adenoma, (7,26,45,46), canalicular adenoma (7), neurofibroma (26), oral fibroma (23, 26), fibrous hyperplasia (7), giant cell granuloma, pyogenic granuloma (23), hyperkeratosis, and papilloma (8).

On the lower lip, mucocele was the most common differential diagnosis observed among the VLL cases reported in the literature (78.6%), as well as one of the differential diagnoses proposed in the case described. The location of the lesions can justify this. Moreover, the rounded, spherical, oval, raised, or dome-shaped aspect of the lesion located in the submucosal layer of the lip is the characteristic presentation of this traumatic glandular lesion. On the upper lip, hemangioma (41.7%) was the most commonly reported differential diagnosis. The treatment of choice for VLL is surgical excision, and recurrences are not expected like it was observed in the present case. Despite the prominent vascular component, bleeding is rarely observed when removing the lesion (4, 7, 8).

Based on the histopathologic findings, the World Health Organization classified leiomyoma into three groups: solid leiomyoma, vascular leiomyoma (angioleiomyoma), and epithelioid leiomyoma (leiomyoblastoma), being the vascular leiomyomas the most prevalent in the oral cavity, as it was the case in our report (2, 4, 11). Histologically, the solid-type is characterized by bundles of smooth muscle cells and thin-walled vessels; the vascular type shows thick vascular channels' walls and an arrangement of vascular musculature within the intervascular muscle bundles. The cavernous-type is composed of large vascular channels with delicate muscular walls. Some lesions may present mixed patterns, leading to a biphasic aspect (7).

Many other morphological variations have been described like areas of hemorrhage and deposits of hemosiderin, dense hyalinization of collagen, mature fat cells, and goblet-shaped endothelial cells (7, 38). Foci of ossification are rare and indicates tissue degeneration, which may be due to an inadequate blood supply. Considering the histopathological aspects of leiomyoma, the abundance of spindle-shaped cells adds other benign lesions to its differential diagnoses, such as myofibroma, heman-giopericytoma, neurofibroma, neurilemmoma and schwannoma.

Hematoxylin and eosin stain is routinely used to define the diagnosis of vascular leiomyoma. Special stains such as Masson's trichrome, Van Gieson's stain, or Mallory's phosphotungstic acid (PTAH) are specific for muscle cells and collagen fibers, and can also contribute in achieving the diagnosis (30, 32, 44, 47, 48). Nowadays, the confirmation of smooth muscle origin can be achieved immunohistochemically with smooth muscle markers such as SMA, desmin, HHF-35, calponin and h-caldesmon (7, 23, 30, 32, 47-53). For vascular endothelium the use of CD31, CD34, and factor VII are indicated (22). Our case demonstrated intense and diffuse expression of SMA within the tumor cells and CD34 immunoreactivity of the endothelial cell lining in the vascular spaces, indicating the presence of blood vessels and confirming the smooth muscle origin.

It is very important to differentiate vascular leiomyomas from its malignant counterpart leiomyosarcoma. The malignant lesions present myofibroblast-like cells and undifferentiated mesenchymal or fibroblast-like cells. Some immunohistochemical and molecular markers like Ki-67, p53, p16, p21, PCNA, B-cell lymphoma 2, cyclin-dependent kinase 4, and mouse double minute 2 homolog, can be used for identifying leiomyosarcoma (50, 54, 55).

The diagnosis of leiomyoma in the oral cavity is difficult because the lack of suspicion by the stomatologist and the oral pathologist concerning a tumor that it is rarely encountered. Knowing the clinical, microscopical, and immunohistochemical features of VLL is essential to achieve a correct diagnosis and to perform an adequate treatment.

Table 1. Summary of reported cases of labial vascular leiomyoma

References	N°	Sex	Race	Age (years)	Size (cm)	Duration	Location	Color	Consistency	Shape	Symptoms	Differential diagnosis
Duhig & Ayer (1959) ¹	1	UD	UD	UD	UD	UD	Lower	UD	UD	UD	UD	UD
	2	UD	UD	UD	UD	UD	Lower	UD	UD	UD	UD	UD
Hagy et al. (1964) ³⁶	3	F	black	76 years	2.0	UD	UD	slightly darker	firm	round, raised	asymptomatic	mucocele
MacDonald (1969) ¹⁸	4	M	UD	44 years	1.5 x 1.0	2 years	Upper	white	UD	UD	asymptomatic	UD
McGowan & Jones (1969) ²⁴	5	F	UD	48 years	1.0	12/14 years	Lower	purple-blue	UD	round	asymptomatic	mucocele
	6	M	UD	54 years	1.0	5 years	Upper	UD	UD	UD	asymptomatic	UD
Cherrick et al. (1973) ¹⁹	7	M	white	24 years	0.4	2 weeks	Lower	UD	UD	UD	asymptomatic	UD
Gutmann (1974) ³⁷	8	F	UD	44 years	1.0	UD	Lower	bluish	UD	UD	asymptomatic	mucocele
Farman (1975) ²⁹	9	M	UD	UD	UD	UD	Lower	UD	UD	UD	UD	UD
	10	M	UD	UD	UD	UD	Lower	UD	UD	UD	UD	UD
Damm & Neville (1979) ²⁶	11	M	white	47 years	1.5	3 months	Lower	UD	UD	round	UD	mucocele
	12	F	white	42 years	1.0	1 year	Lower	UD	UD	UD	UD	neurofibroma
	13	F	black	28 years	1.0	1 year	Lower	UD	UD	UD	asymptomatic	pleomorphic adenoma
Masuda (1980) ³⁰	14	M	UD	33 years	2.0 x 2.0 x 1.0	UD	Lower	UD	UD	UD	symptomatic	UD
Giles & Gosney (1982) ⁴⁴	15	M	white	46 years	1.0	4 years	Upper	bluish	UD	UD	asymptomatic	UD
Natiella et al (1982) ¹⁶	16	M	UD	14 years	0.9 X 0.9 X 0.5	UD	Lower	UD	UD	dome	UD	UD
	17	F	UD	28 years	UD	UD	Upper	UD	UD	UD	UD	UD
	18	M	UD	57 years	1.2 X 1.0 X 0.9	UD	Upper	UD	UD	UD	UD	UD
	19	F	UD	83 years	1.0 X 0.8 X 0.5	UD	Upper	UD	UD	UD	UD	UD
	20	M	UD	73 years	1.1 X 0.8 X 0.5	UD	Upper	UD	UD	UD	UD	UD
Savage et al (1983) ³⁸	21	F	white	34 years	0.4 to 0.5	4 years	Lower	bluish	UD	UD	UD	mucous extravasation cyst

References	N°	Sex	Race	Age (years)	Size (cm)	Duration	Location	Color	Consistency	Shape	Symptoms	Differential diagnosis
Hachisuga et al (1984) ²¹	22	UD	UD	UD	UD	UD	UD	UD	UD	UD	UD	UD
	23	UD	UD	UD	UD	UD	UD	UD	UD	UD	UD	UD
	24	UD	UD	UD	UD	UD	UD	UD	UD	UD	UD	UD
	25	UD	UD	UD	UD	UD	UD	UD	UD	UD	UD	UD
	26	UD	UD	UD	UD	UD	UD	UD	UD	UD	UD	UD
	27	UD	UD	UD	UD	UD	UD	UD	UD	UD	UD	UD
	28	UD	UD	UD	UD	UD	UD	UD	UD	UD	UD	UD
	29	UD	UD	UD	UD	UD	UD	UD	UD	UD	UD	UD
	30	UD	UD	UD	UD	UD	UD	UD	UD	UD	UD	UD
	31	UD	UD	UD	UD	UD	UD	UD	UD	UD	UD	UD
	32	UD	UD	UD	UD	UD	UD	UD	UD	UD	UD	UD
	Birman et al (1984) ²⁵	33	M	UD	46 year	UD	UD	Upper	UD	UD	UD	asymptomatic
34		M	UD	64 year	UD	UD	Lower	UD	UD	UD	asymptomatic	mucocele
Epiatianos et al (1985) ⁴⁵	35	M	UD	47 years	1.0 x 1.0	4 months	Upper	labial mucosa	UD	UD	asymptomatic	adenoma
Esguep & Sola (1986) ³⁴	36	M	UD	47 years	1.5 x 1.0	UD	Lower	UD	UD	UD	UD	mucocele
	37	M	UD	50 years	1.3 x 1.1	UD	Upper	UD	UD	UD	UD	hemangioma
Terui et al (1987) ³⁹	38	M	UD	34 years	1.0	8 years	Lower	whitish	UD	Dome	asymptomatic	mucous cyst
Kawakami et al (1987) ⁴²	39	M	UD	33 years	0.5	8 a 9 years	Lower	dark purple	UD	UD	asymptomatic	hemangioma
Candelaria et al (1988) ⁴⁰	40	F	white	55 years	0.5 x 0.5	UD	Upper	bluish	rubbery	UD	asymptomatic	mucocele
Maeda et al (1989) ⁴³	41	M	UD	37 years	0.7 x 0.8	UD	Upper	UD	soft	UD	UD	hemangioma
Anastassov et al (1995) ⁴⁶	42	M	white	51 years	1.5 x 1.0	1 year	Upper	reddish/bluish	elastic	UD	asymptomatic	mucocele
Reyes Santías et al (1998) ⁴¹	43	F	UD	74 years	UD	UD	Lower	UD	UD	UD	UD	UD
Toida et al (2000) ³¹	44	M	white	10 years	2.0 x 1.5	UD	Lower	UD	UD	spherical	symptomatic	mucocele
Orsini et al (2001) ⁴⁹	45	M	UD	59 years	0.8	UD	Upper	UD	indurated	UD	asymptomatic	UD
Brooks et al (2002) ⁸	46	M	white	14 years	0.3 x 0.3	UD	lower	reddish blue	UD	slightly raised	UD	hemangioma
	47	M	white	18 years	0.4 x 0.5	1 month	Lower	whitish	IUD	round, raised	UD	mucocele
	48	M	white	59 years	UD	4 months	Lower	white	UD	UD	UD	Hyperkeratosis
	49	F	white	44 years	0.2 x 0.2	1 year 1/2	Upper	UD	UD	round, raised	UD	papiloma
	50	F	white	UD	0.3 x 0.8 x 0.9	UD	UD	UD	UD	encapsulated	UD	mucocele
Wang et al (2004) ⁹	51	F	UD	52 years	0.6	UD	Upper	UD	UD	UD	UD	UD
	52	F	UD	65 years	0.7	UD	Upper	UD	UD	UD	UD	UD
	53	F	UD	67 years	0.6	UD	Lower	UD	UD	UD	UD	UD

References	N°	Sex	Race	Age (years)	Size (cm)	Duration	Location	Color	Consistency	Shape	Symptoms	Differential diagnosis
Ide et al (2008) ¹⁰	54	M	UD	55 years	0.1	UD	Upper	UD	UD	UD	UD	UD
	55	M	UD	42 years	0.2	UD	Lower	UD	UD	UD	UD	UD
	56	M	UD	57 years	1.0	UD	Lower	UD	UD	UD	UD	UD
	57	M	UD	48 years	1.6	UD	Lower	UD	UD	UD	UD	UD
	58	F	UD	67 years	1.0	UD	Upper	UD	UD	UD	UD	UD
	59	M	UD	44 years	1.8	UD	Upper	UD	UD	UD	UD	UD
	60	F	UD	43 years	0.4	UD	Lower	UD	UD	UD	UD	UD
	61	M	UD	30 years	0.8	UD	Lower	UD	UD	UD	UD	UD
	62	M	UD	40 years	0.7	UD	Lower	UD	UD	UD	UD	UD
	63	M	UD	60 years	0.9	UD	Lower	UD	UD	UD	UD	UD
	64	M	UD	57 years	0.8	UD	Upper	UD	UD	UD	UD	UD
65	M	UD	54 years	1.2	UD	Upper	UD	UD	UD	UD	UD	
Gaitan-Cepeda et al (2008) ²²	66	F	UD	43 years	0.7 x 0.5 x 0.4	9 months	Lower	UD	resilient	irregular oval	asymptomatic	UD
	67	M	UD	36 years	1.5 x 1.0 x 1.0	7 years	Upper	light brown	firm	irregular	asymptomatic	UD
	68	M	UD	48 years	1.7 x 1.0 x 1.0	UD	Upper	brownish	UD	UD	asymptomatic	UD
Chang & Kessler (2008) ⁴⁷	69	F	UD	45 years	UD	UD	UD	UD	UD	UD	UD	UD
Gueiros et al (2011) ⁷	70	F	UD	54 years	1.0 x 1.0	6 months	Lower	UD	fibrous	UD	asymptomatic	mucocele
	71	M	UD	66 years	UD	19 years	Upper	UD	fibrous	UD	asymptomatic	UD
	72	M	UD	53 years	0.8 x 0.5 x 0.5	5 months	Upper	UD	fibrous	UD	UD	fibrous hyperplasia
Gianluca et al (2011) ²	73	M	UD	49 years	UD	8 years	Lower	brownish	resilient	irregular oval	asymptomatic	UD
Yoon et al (2013) ⁵¹	74	F	UD	60 years	0.7	UD	Upper	UD	UD	UD	UD	UD
Liu et al (2014) ⁴⁸	75	M	UD	58 years	6.0	15 years	UD	UD	UD	UD	symptomatic	UD
Carvalho et al (2015) ⁵²	76	F	white	44 years	2.0	UD	Lower	labial mucosa	firm	UD	asymptomatic	UD
Hassona et al (2017) ⁵³	77	F	UD	52 years	UD	6 months	Upper	labial mucosa	firm	oval	asymptomatic,	pleomorphic adenoma
Matiakis et al (2018) ²³	78	F	UD	51 years	0.8	9 months	Upper	red-bluish	hard elastic	UD	asymptomatic	oral fibroma
Silva et al	79	F	UD	27 years	0.8	12 months	Lower	white	resilient	nodular	symptomatic	mucocele

UD: Undefined

References

1. Duhig JT, Ayer JP. Vascular leiomyoma: A study of sixty-one cases. Arch Pathol 68: 424, 1959.
2. Gianluca S, Marini R, Tonoli F, Cristalli MP. Leiomyoma of oral cavity: case report and literature review. Ann Stomatol (Roma). 2011; 2(1-2): 9-12.
3. Alves PMA, Novaes MN, Neto AL, Gody GP, Costa DA, Medeiros AMC, Queiroz LMG. Leiomioma vascular oral: relato de caso e estudo imunohistoquímico. rev. cir. Traumatol.buco-maxilo-fac.2013;13(1) Camaragibe

4. Veeresh M, Sudhakama M, Girish G, Naik C. Leiomyoma: A rare tumor in the head and neck and oral cavity: Report of 3 cases with review. *J Oral Maxillofac Pathol.* 2013;17(2): 281–287.
5. Arpag OF, Darmlar I, Killiç S, Altan A, Tas ZA, Ozgur T. Angioleiomyoma of the gingiva: a report of two cases. *J Korean Assoc Oral Maxillofac Surg* 2016; 42:115-119.
6. Silveira VAS, Amadei SU, Machado ACP, Prado RF, Neves AC, Quirino MRS, Carvalho YR. Leiomioma vascular bucal: relato de dois casos, revisão da literatura e estudo imuno-histoquímico. *J. Bras. Patol. Med. Lab.* 2007;43(3).
7. Gueiros LA, Romanach MJ, Soubhia AMP, Pires FR, Almeida OP, Vargas PA. Angioleiomyoma affecting the lips: Report of 3 cases and review of the literature. *Med Oral Patol Oral Cir Bucal.* 2011;16 (4):e482-487.
8. Brooks JK, Nikitakis NG, Goodman NJ, Levy BA. Clinicopathologic characterization of oral angioleiomyomas. *Oral Surg Oral Med Oral Pathol Oral Radiol Endod.* 2002;94:221-227.
9. Wang CP, Chang YL, Sheen TS. Vascular leiomyoma of the head and neck. *Laryngoscope.* 2004;114:661-665.
10. Ide F, Mishima K, Yamada H, Saito I, Horie N, Shimoyama T, et al. Perivascular myoid tumors of the oral region: a clinicopathologic re-evaluation of 35 cases. *J Oral Pathol Med.* 2008;37:43-49.
11. El-Naggar AK, Chan JKC, Grandis JR, Takata T, Slootweg PJ. WHO Classification of Head and Neck Tumours (4th edition). IARC: Lyon, 2017).
12. Ramesh P, Annapureddy SR, Khan F, Sutaria PD. Angioleiomyoma: a clinical, pathological and radiological review. *Int J Clin Pract.* 2004;58:587–591.
13. Kaur G, Gondal R. Oral leiomyoma. *J Oral Maxillofacial Pathol.* 2011; 15(3): 361–362.
14. Sánchez MAG, Bonnin MC, Aytés LB, Escoda CG. Leiomyoma of the hard palate: A case report. *Med. Oral patol. Oral. Cir.bucal (internet).*2007;12(3).
15. Benet ML, Bagán JV, Miguel EL, Morant AB, Alonso S. Leiomioma oral: A propósito de un caso clínico. *Med Oral* 2003;8:215-219.
16. Natiella JR, Neiders ME, Greene GW. Oral leiomyoma: report of six cases and a review of the literature. *J Oral Pathol.* 1982;11(5):353-365.
17. Baden E, Doyle JL, Lederman DA. Leiomyoma of the oral cavity: a light microscopic and immunohistochemical study with review of the literature from 1884 to 1992. *Eur J Cancer B Oral Oncol.* 1994;30B:1-7.
18. MacDonald DG. Smooth muscle tumors of the mouth. *Br J Oral Surg.* 1969; 6:207-14.

19. Cherrick HM, Dunlap CL, King OH. Leiomyomas of the oral cavity. *Oral Surg Oral Med Oral Pathol.* 1973; 35:54-66.
20. Ravindranathan N, Heslop IH. *Br J Oral Surg.* 1978; 16(1978-79):93-99.
21. Hachisuga T, Hashimoto H, Enjoji M. Angioleiomyoma. A clinicopathologic reappraisal of 562 cases. *Cancer.* 1984;54:126-130.
22. Gaitan-Cepeda LA, Quezada Rivera D, Tenorio Rocha F, Leyva Huerta ER, Mendez Sánchez ER. Vascular leiomyoma of the oral cavity. Clinical, histopathological and immunohistochemical characteristics. Presentation of five cases and review of the literature. *Med Oral Patol Oral Cir Bucal.* 2008;13:E483-8.
23. Matiakis A, Karakostas P, Pavlou AM, Anagnostou E, Pouloupoulos A. Angioleiomyoma of the oral cavity: a case report and brief review of the literature. *J Korean Assoc Oral Maxillofac Surg.* 2018; 44:136-139.
24. McGowan DA, Jones JH. Angioma (vascular leiomyoma) of the oral cavity. *Oral Surg Oral Med Oral Pathol.* 1969;27:649-652.
25. Birman EG, Neto JG, Araújo VC, Araújo NS. Leiomioma da cavidade bucal: revisão da literatura e relato de dois casos com estudo ultramicroscópico. *Rev Port Estomatol Med Dent Cir Maxilofac.* 1984; XXV:918-933.
26. Damm DD, Neville BW. Oral leiomyomas. *Oral Surg.* 1979; 47:343-348.
27. Bertolini F, Bianchi B, Corradi D, Caradonna L, Sesenna E. Mandibular intraosseous leiomyoma in a child: report of a case. *J Clin Pediatr Dent.* 2003; 27(4): 385-387.
28. Valls-Ontanon A, Pozuelo-Arquimbau L, Mateu-Esquerda G, Arranz-Obispo C, Cuscó-Albors S, Melero-Luque M, Morla A, Marí-Roig A. Intraosseous Leiomyoma of the Jaw in an Adolescent. *J Dent Child (Chic).* 2017;84(2):90-96.
29. Farman AG, Kay S. Oral leiomyosarcoma. Report of a case and review of the literature pertaining to smooth-muscle tumors of the oral cavity. *Oral Surg Oral Med Oral Pathol.* 1977; 43:402-409.
30. Liu Y, Li B, Li L, Liu Y, Wang C, Zha L. Angioleiomyomas in the head and neck: a retrospective clinical and immunohistochemical analysis. *Oncol Lett* 2014;8: 241-247
31. Masuda N, Kawai K, Ishikura M, et al. Vascular leiomyoma of the lower lip. *Otolaryngology (Tokio).* 1980, 52:355.
32. Toida M, Koizumi H, Shimokawa K. Painful angiomyoma of the oral cavity: report of a case and review of the literature. *J Oral Maxillofac Surg.* 2000;58:450-453.
33. Morimoto N. Angiomyoma (vascular leiomyoma): a clinicopathological study. *Med J Kagoshima Univ.* 1973;24:663-683.

34. Montgomery H, Winkelmann RK: Smooth-muscle tumours of the skin. *AMA Arch Derm* 79: 32-40, 1959.
35. Esguep A, Solar M. Oral vascular leiomyoma - - report of 5 cases and review of the literature. *J Oral Med* 41: 126-129, 1986.
36. Lloria Benet M, Bagan JV, Lloria de Miguel E, Borja Morant A, Alonso S. Leiomyoma oral: a proposito de un caso. *Med Oral* 2003;8:215-219.
37. Hagy DM, Halperin V, Wood C. Leiomyoma of the oral cavity. *Oral Surg Oral Med Oral Pathol.* 1964; 17:748-755.
38. Gutmann J, Cifuentes C, Balzarini MA, Sobarzo V, Vicuña R. Angiomyoma of the oral cavity. *Oral Surg Oral Med Oral Pathol.* 1974;38:269-273.
39. Savage NW, Adkins KF, Young WG, Chapman PJ. Oral vascular leiomyoma: review of the literature and report of two cases. *Aust Den J.* 1983; 28: 346-351.
40. Terui T, Takahashi M, Tagami H. Angioleiomyoma of the lip. *Int J Dermatol.* 1987;26:119-20.
41. Candelaria LM, Warnock GR, Pankey G. Nonpainful, smooth-surfaced, bluish nodule on the upper lip. *J Am Dent Assoc.* 1988;117:48748-8.
42. Reyes-Santías RM, Suárez Peñaranda JM, Martín Martín C, Abdulkader I, Forteza Vila J. Smooth muscle tumor of the lower lip. A report of a case of rapid growing and increased mitotic activity. *Acta Otorrinolaringol Esp.* 1998;49:495-497.
43. Kawakami T, Hasegawa H, Chino T. A transmission electron microscopic study of two cases of oral smooth muscle neoplasm. *J Oral Maxillofac Surg.* 1987;45: 551-555.
44. Maeda Y, Hirota J, Osaki T, Hayashi K, Sonobe H, Otsuki Y. Angiomyoma of the upper lip: report of a case with electron microscopic and immunohistochemical observation. *Br J Oral Maxillofac Surg.* 1989;27:236-242.
45. Giles AD, Gosney MB. Oral angiomyoma: a case report. *Br J Oral Surg.* 1982;20: 142-146.
46. Epivatianos A, Trigonidis G, Papanayotou P. Vascular leiomyoma of the oral cavity. *J Oral Maxillofac Surg.* 1985;43:377-382.
47. Anastassov GE, Van Damme PA. Angioleiomyoma of the upper lip: report of a case. *Int J Oral Maxillofac Surg.* 1995;24:301-302.
48. Chang JY, Kessler HP. Masson trichrome stain helps differentiate myofibroma from smooth muscle lesions in the head and neck region. *J Formos Med Assoc.* 2008; 107:767-773.
49. Orsini G, Rubini C. Leiomyoma of the lip: report of a case. *J Oral Maxillofac Surg.* 2001, 59:80-83.

50. Nikitakis NG, Lopes MA, Bailey JS, Blanchaert RH Jr, Ord RA, Sauk JJ. Oral leiomyosarcoma: review of the literature and report of two cases with assessment of the prognostic and diagnostic significance of immunohistochemical and molecular markers. *Oral Oncol* 2002;38:201-208.
51. Yoon TM, Yang HC, Choi YD, Lee DH, Lee JK, Lim SC. Vascular leiomyoma in the head and neck region: 11 years experience in one institution. *Clin Exp Otorhinolaringol* 2013; 6:171-175.
52. Carvalho CHP, Oliveira BRS, Nascimento GJF, Santos PPA, Costa ALL. Leiomioma oral: relato de caso e revisão da literatura. *Brasilia Med* 2015; 52:28-32.
53. Hassona Y, Sawair F, Scully C. Angioleiomyoma of the upper lip. *BMJ Case Rep* 2017. doi: 10.1136/bcr-2016-219172.
54. Schutz A, Smeetes R, Driemel O, Hakim SG, Kosmehl H, Hanken H, Kolk A. Primary and Secondary Leiomyosarcoma of the Oral and Perioral Region - Clinicopathological and Immunohistochemical Analysis of a Rare Entity With a Review of the Literature. *J oral Maxillofac Surg* 2013; 71:1132-1142.
55. Montgomery E, Goldblum JR, Fisher C. Leiomyosarcoma of the head and neck: a clinicopathological study. *Histopathology* 2002; 40:518-255