

Compared Cranial Osteology of Species of *Leptoptilus* (Lesson, 1831) (Aves, Ciconiidae)

Pamela Rayara de Souza Oliveira¹, Reginaldo José Donatelli², Arthur Serejo Neves¹,
Francisco das Chagas Vieira Santos¹, Suely Silva Santos¹, Muryllo do Santos Nascimento¹,
Guilherme José Bolzani de Campos Ferreira³, Anderson Guzzi^{1*}

¹Federal University of Piauí, Parnaíba, Brazil

²São Paulo State University, Bauru, Brazil.

³Federal University of Piauí, Bom Jesus, Brazil

*Corresponding author, e-mail: guzzi@ufpi.edu.br

Abstract

The species of the Ciconiidae family (Ciconiiformes), commonly known as storks, exhibit a cosmopolite distribution, being represented by swamp birds of medium and large size. The present work aimed to describe minutely and comparatively the cranial osteology of *Leptoptilus* species. The study was performed based on the description of cranial bones of the species *Leptoptilus dubius*, *L. crumeniferus*, and *L. javanicus*. The studied specimens were previously prepared (dry crania and mandibles). Among the studied characteristics, it was possible to observe some structures of systematic importance, such as the zygomatic process, the temporal fossa, the ectethmoid, the superior maxilla, the quadrate bone that interconnects the palate, the neurocranium, and the mandible, performing a key role in the work of cranial kinesis. *Leptoptilus javanicus* possesses, in the lateral portion of the cranium, an emargination of the rostradorsal edge of the postorbital process, not observed in either *Leptoptilus dubius* or *Leptoptilus crumeniferus*. The fossa ventralis possesses a projection in the caudal extremities in *L. dubius* and *L. crumeniferus*, which is absent in *L. javanicus*. The transpalatine process is present in both *L. dubius* and *L. crumeniferus* and is absent in *L. javanicus*. The pterygoid process of the palatine is short in both *L. dubius* and *L. crumeniferus*, and long in *L. javanicus*. The ectethmoid is reduced in both *L. dubius* and *L. javanicus*, whereas in *L. crumeniferus*, besides being more developed, it presents a "U" shape. Based on the present study, *L. dubius* and *L. crumeniferus* are phylogenetically closer to each other than *L. javanicus*.

Palavras-chave: Osteology, *Leptoptilus*, Ciconiidae.

Introduction

The species of the Ciconiidae family (Ciconiiformes), commonly known as storks, exhibit a cosmopolite distribution, being represented by swamp birds of medium and large size. Out of the 19 species that represent this family, 7 are listed among the Red List of Threatened Species, published in 2004 by the IUCN (International Union for Conservation of Nature): *Leptoptilus javanicus*, *Mycteria cinerea*, *Ciconia boyciana*, *Ciconia stormi*, *Ephippiorhynchus asiaticus*, *Leptoptilus dubius*, and *Mycteria leucocephala*. In spite of the status that theoretically assures greater protection to the above-listed species, all the remaining species are indirectly threatened, considering the

accelerated level of degradation in the flooded areas where these birds forage and reproduce (Elliott, 1992).

The family Ciconiidae is a well-defined group of birds divided into three tribes: Mycteriini, Ciconiini, and Leptoptilini (Kahl 1971, 1972, 1979). The tribe Leptoptilini, created by Kahl, which includes *Jabiru*, *Ephippiorhynchus*, and *Leptoptilus*, does not appear as a monophyletic group in any of the trees based on molecular characters.

Its fossil register dates from the beginning of the Tertiary, from the Upper Eocene in France and a greater irradiation in the Oligocene. However, most stork fossils are known from the

Tertiary in Europe, Asia, the Americas, and Africa, based in isolated fragmented remains that impede the comprehension of the phylogeny of Ciconiidae species (Feduccia 1996).

The oldest fossil of South-American stork, *Ciconiopsis antarctica* Ameghino 1899, was described from the beginning of the Oligocene in Santa Cruz (Argentina), although its original attribution has been questioned (Olson, 1985; Agnolin 2004). More recently, isolated fragments from tarsus and metatarsus, certainly referring to body parts of Mycteriini were reported dating from the Miocene, in the Río Provincia, Argentina (Noriega, 1995; Noriega and Agnolin 2006).

The Ciconiidae present different behaviors related to thermoregulation, such as gasping with the tongue raised and bristling of the feathers in order to dissipate the body heat, with the ability to perform urohidrosis (habit of defecating onto the feathers), in this way favoring the loss of heat through evaporation. This strategy is widely employed by species of the genus *Leptoptilus*, whereas *L. dubius* and *L. crumeniferus* use their hanging air sac to dissipate heat and as a sexual character during the reproductive period (del Hoyo et al. 1992).

Because of their large size and conspicuousness, and of several species being common in zoos, storks have been the focus of numerous ecological studies, both behavioral and morphological (Sibley and Ahlquist, 1990; Coulter, 1991). Species from tempered areas are active during most of the day, especially during the reproduction season, whereas tropical species tend to feed primarily in the early and late hours of the day, although large birds, such as *Leptoptilus crumeniferus* normally need to wait until the thermal currents have formed, in order to fly at morning. The daily schedule of coastal species such as *Leptoptilus javanicus* is often precisely regulated by the tides, and such birds tend to rest in several small trees during the high tide (del Hoyo et al. 1992).

The genus *Leptoptilus* consists of three species: *Leptoptilus javanicus*, *L. dubius*, and *L. crumeniferus*. *Leptoptilus crumeniferus* occurs in all of tropical Africa; *L. dubius* is distributed from India to Indochina, whereas *L. javanicus* occupies Borneo, Indonesia, Ceylon, northeastern India

and Indochina (del Hoyo et al. 1992).

Leptoptilus javanicus is nowadays considered as globally vulnerable (BirdLife, 2011). This occurs a consequence of a small and declining population due to the loss and degradation of habitats, hunting, and disturbance. Current efforts for the conservation of species include, among others, nest protection measures (Visal & Clements, 2008; Clements et al. 2009; BirdLife, 2011), as well as low-scale programs of captive breeding (Salakij et al. 2004; Maust et al. 2007).

Leptotilus dubius occurs in the north and northeast of India, Nepal, Bangladesh, Myanmar, Thailand, Cambodia, and southern Vietnam (Baker 1929, Ali and Rip-Lei 1987, Fleming et al. 1979; Hancock et al. 1992), currently restricting to the Brahmaputra Vally, Assam (Saikia and Bhattacharjee 1989a, b; Rahmani 1989; Rahmani et al. 1990).

According to Sibley & Ahlquist (1990), several stork species are included in the phylogeny of the world birds based on DNA-DNA hybridization data. This pattern of phylogenetic relationship conflicts with that obtained by Slikas (1997), in the tree represented with the lowest number of steps based on DNA-DNA hybridization data.

The cranium of the birds might represent a significant part in phylogenetic analyses of new characters, and anatomical evidence for their states was raised (Zusi, 1984).

Based on the foregoing, this work aimed to describe minutely and comparatively the cranial osteology of species representative of the genus *Leptoptilus* of the Ciconiidae family.

Material and Methods

The cranial osteological characters of the following *Leptoptilus* species in the Ciconiidae family were studied and described: *Leptoptilus javanicus*, *L. dubius*, *L. crumeniferus* (Table 1).

The description of the cranial osteology was comparative and illustrated by drawings in dorsal, ventral, mandibular, and lateral views (draftsman: Francisco Pedro de Souza Oliveira), followed by subtitles in order to ease the observation of structures.

The studied specimens were previously

prepared (dry crania and mandibles). Considering that most of the cranial bones are even and that a bilateral symmetry exists, the osteological description occurred in the singular.

The nomenclature employed for this description followed the *Nomina Anatomica Avium* (Baumel *et al.* 1993). Due to the fusion of the cranial bones in the birds, the bone boundaries of the crania followed the description presented by Jollie (1957), and also those used by Höfling and Gasc (1984), Höfling (1995), Donatelli (1991, 1996, 1996 e 1997), Marceliano (1996), Ladeira (1997), Marceliano *et al.* (1997), Méndez (1998), Posso (1999), Silveira (1999), Faustino *et al.* (1999), Pascotto (2000), and Guzzi (2003).

The classification and nomenclatures of the species are the same presented by Howard & Moore (1998).

The specimens studied *in loco* had been previously prepared (dry cranium and mandibles) and belong to the collection of the National Museum of Natural History (USNM), Smithsonian Institution, Washington, DC, EUA.

Results

Ossa cranii

The interorbital width corresponds to about 85% of the temporal width in *L. javanicus*, *L. dubius*, and *L. crumeniferus*. In the frontal region, the lacrimal process of the frontal bone is absent in *L. javanicus*, *L. dubius*, and *L. crumeniferus*. The frontal region articulates rostrally with the nasal region through the craniofacial flexion zone (Craniofacial Flexion Zone. - ZFC – Figures 1A, 1B, and 1C), not fused in *L. javanicus*, *L. dubius*, and *L. crumeniferus*.

The same region presents an accentuated median rostral concavity of the frontal bone, absent in *L. javanicus*, *L. dubius*, and *L. crumeniferus*.

The frontal region continues caudally with the wide parietal region and continues laterocaudally with the robust post-orbital process. The proximal portion of the lacrimal has approximately 1/5 of the width of the distal part in *L. javanicus*, *L. dubius*, and *L. crumeniferus*.

The wide parietal region is lateroventrally limited with the squamosal region by the superior temporal crest, conspicuous in *L. javanicus*, *L.*

dubius, and *L. crumeniferus*. Laterocaudally it may be verified that the occipital region, through the *crista nuchalis transversa*, in its median caudal region, is continued with the supraoccipital region.

The squamosal region is laterodorsally delimited by the superior temporal crest, which occupies most of the lateral portion of the cranium, caudally to the postorbital process, ventrocaudally by the *meatus acusticus externus* and by the pronounced suprameatic process (*Proc. suprameaticus* – PrS, Figures 2A, 2B, and 2C), developed in *L. javanicus*, *L. dubius*, and *L. crumeniferus*.

Still in the lateral portion of the cranium, an emargination of the rostradorsal edge of the postorbital process was observed in *L. javanicus* (PrPO, Figures 2A, 2B and 2C), not observed in *L. dubius* and *L. crumeniferus*.

The temporal fossa (*Fossa temporalis* – FT, Figures 2A, 2B, and 2C) is rostradorsally longer than wide and shallow in *L. javanicus*, *L. dubius*, and *L. crumeniferus*. The temporal fossa is dorsally delimited by the superior temporal crest, and ventrally by the *crista nuchalis transversa*.

The squamosal region is rostrally projected and forms the zygomatic process (*Proc. zygomaticus* – PrZ, Figures 2A, 2B, and 2C). This process is long and widened in its base and presents a characteristic triangular shape, slightly twisted over itself, occupying from 40 to 50% of this distance in *L. javanicus*, *L. dubius*, and *L. crumeniferus*. The zygomatic process presents well-delimited dorsal, ventral, lateral, and medial surfaces, evidencing the places of origin of the *adductor*, *mandibulae externus*, *rostralis*, *lateralis*, and *medialis* muscles.

The squamosal region is rostromedially delimited with the laterosphenoid region, and rostradorsally with the frontal region by the postorbital process (*Proc. postorbitalis* – PrPO, Figures 2A, 2B, and 2C). This process is long, robust, and well-developed, with a wide base, long in *L. javanicus*, *L. dubius*, and *L. crumeniferus*.

The occipital region comprehends the supraoccipital (*Os supraoccipitale*), exoccipital (*Os exoccipitale*) and basioccipital (*Os basioccipitale*) fused bones. It is dorsolaterally limited with the squamosal region by the *meatus*

acusticus externus and the *crista nuchalis transversa*. The region of the exoccipital bone is delimited with the tympanic cavity by the pronounced paraoccipital process. Its limit with the basioccipital region is marked by the presence of foramens crossed by nerves, and channels crossed by vases, and by the *proc. condylaris*. The region of the basioccipital bone

hosts the conspicuous occipital condyle and the deep subcondylar fossa, which is surrounded by two well-developed basilar tubercles. Caudomedially, it is possible to observe the large foramen magnum. The cerebellar prominence of the region of the supraoccipital bone is protruded and tapered in *L. javanicus*, *L. dubius*, and *L. crumeniferus*.

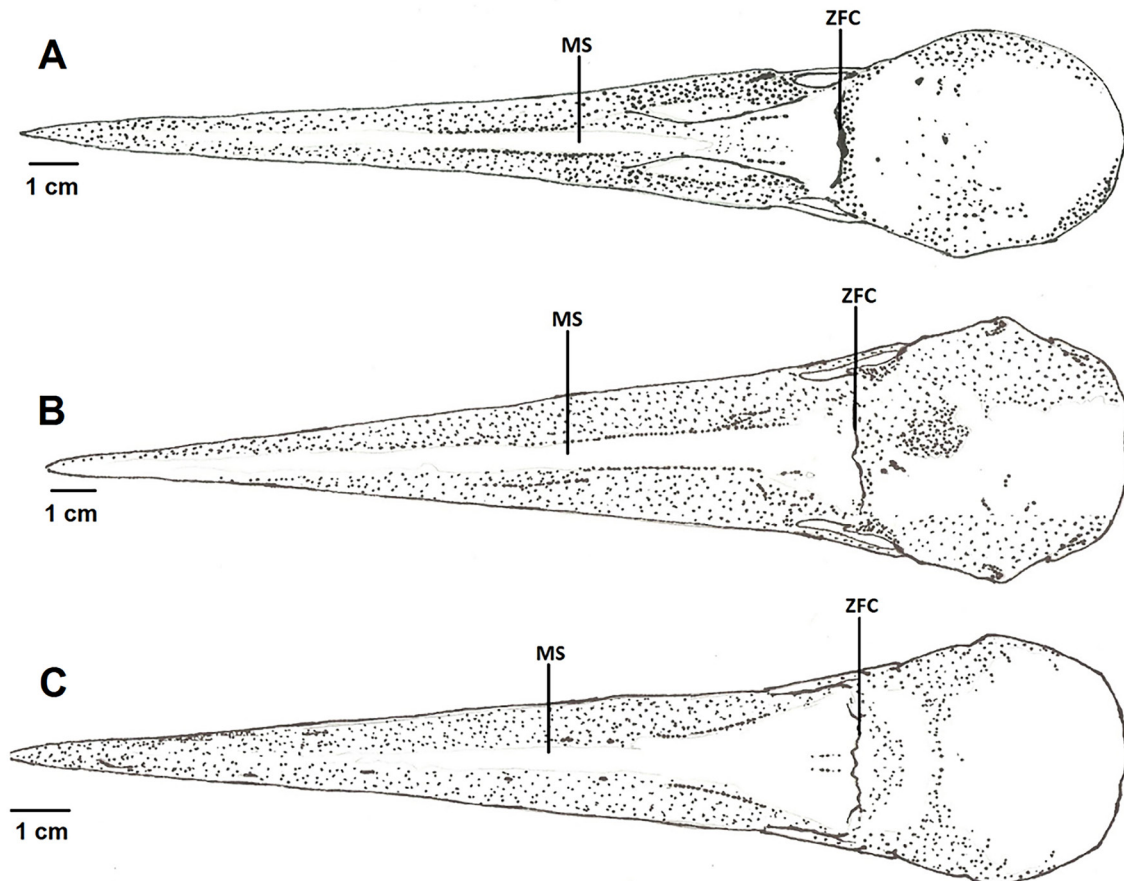


Figure 1(A-C). Dorsal surfaces of the crania of *Leptoptilus crumeniferus*, *Leptoptilus dubius*, and *Leptoptilus javanicus*. Subtitle: MS – superior maxilla; ZCF – craniofacial flexion zone.

The basioccipital region is rostrally continued with the basisphenoid region through the *tuberculum basilare*. The basisphenoid region is widened in its base, although it narrows rostrally in order to fuse with the parasphenoid region. These two regions, along with the basioccipital region, form most of the floor of the neurocranium.

From the region of the parasphenoid bone emerges the projection of the parasphenoid rostrum, which reaches about 50% of the distance of the occipital condyle and the *pes pterygoidei* in *L. javanicus*, *L. dubius*, and *L. crumeniferus*. The parasphenoid rostrum articulates rostrally with

the pterygoid, fuses dorsally with the interorbital septum, and contacts rostrally with the vomer through the *facies articularis vomeralis*.

The ectethmoid (*Os ectethmoidale* – ET, Figures 2A, 2B, and 2C) presents a “U” shape in *L. crumeniferus*; it is reduced in *L. javanicus* and *L. dubius*. It possesses a dorsoventrally long narrowed distal process in *L. javanicus*, *L. dubius*, and *L. crumeniferus*. In its *facies nasalis*, it fuses rostroventrally with the laterocaudal surface of the region of the frontal and lacrimal bones. Rostromedially, it fuses with the rostral region of the interorbital septum.

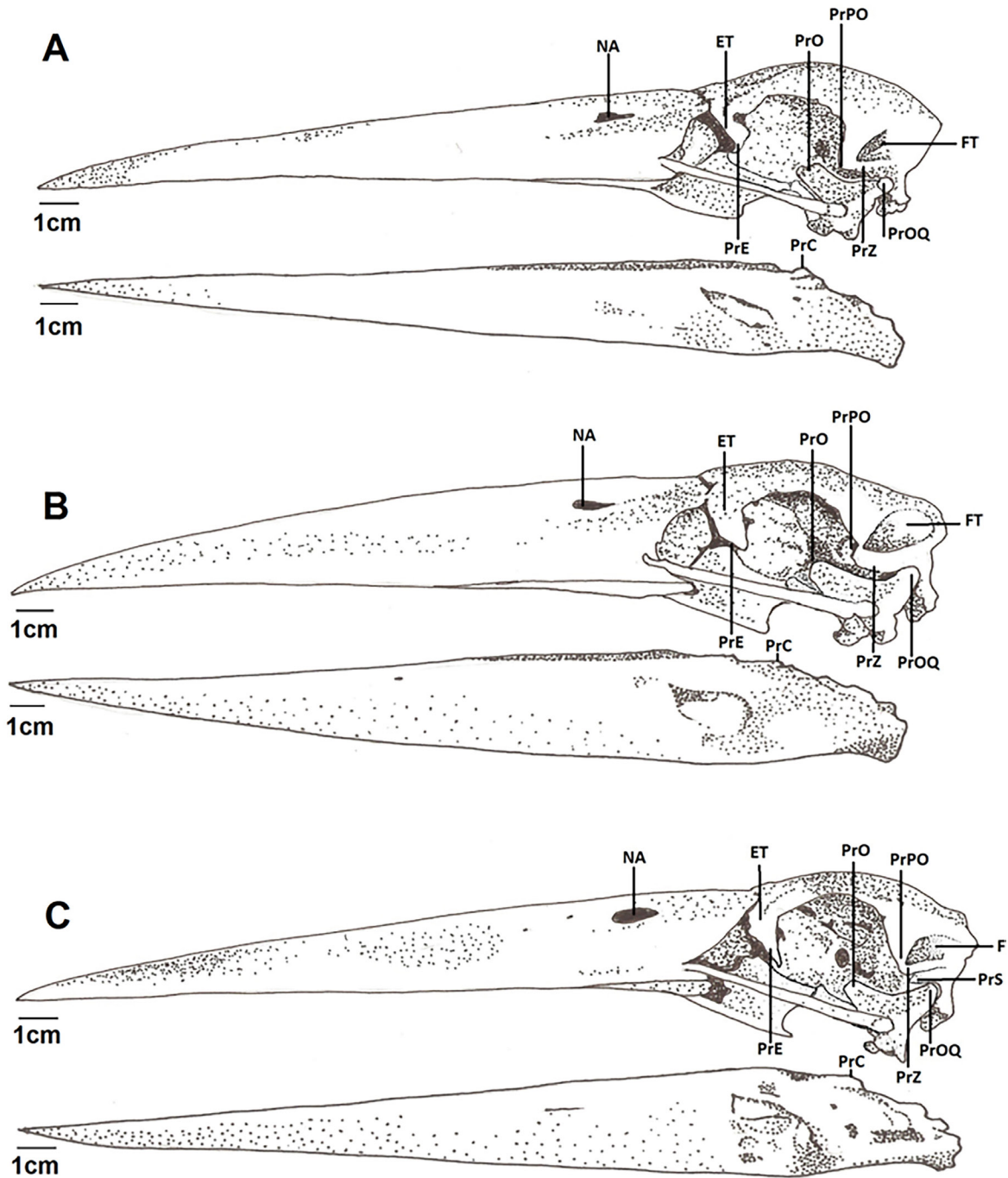


Figure 2(A-C). Lateral surfaces of the crania and mandibles of *Leptoptilus crumeniferus*, *Leptoptilus dubius* and *Leptoptilus javanicus*. Subtitle: FT – temporal fossa; NA – nostril; PrC – coronoid process; PrE – ectethmoid process; PrO – orbital process of the quadrate; PrOQ – optical process of the quadrate; PrPO – postorbital process; PrS – suprameatic process; PrZ – zygomatic process; ET – ectethmoid;

The interorbital septum is dorsally delimited with the region of the frontal bone through the olfactory groove and the conspicuous medial orbitonasal foramen. It is rostrolaterally delimited with the ectethmoid and ventrolaterally contacts with the parasphenoid rostrum and the palatine bone, and ventrolaterally with the pterygoid in *L. javanicus*, *L. dubius*, and *L.*

crumeniferus.

The laterosphenoid region is located in the caudal portion of the orbit, extending from the caudal portion of the interorbital septum until the lateral surface of the squamosal region. In its *facies temporalis*, a dorsolateral portion of the laterosphenoid region, the *proc. Postorbitalis* can be laterally observed. In its *facies cerebralis*,

positioned medially to the postorbital process, stands out a depression that is characteristic of the laterosphenoid region. The "T" tubercle can be verified ventromedially to the temporal fossa, being absent in *L. javanicus*, *L. dubius*, and *L. crumeniferus*. Ventrally to this tubercle it is observed that the foramen of the maxillo-mandibular nerve is extremely wide in all studied species. Dorsally to this foramen, the ophthalmic nerve foramen can be observed, with a smaller caliber than the first.

In the *pars medialis orbitae*, in the dorsomedial portion of the laterosphenoid region, stands out the *fonticuli orbitocranialis*, of variable size between species, which also reaches the *pars medialis orbitae*, the caudal portion of the interorbital septum. The laterosphenoid region is ventrolaterally delimited by the zygomatic process of the squamosal region and is medially delimited with the interorbital septum through the *fonticuli orbitocranialis*.

Ossa faciei

Ossa Maxillae

The superior maxilla (MS – Figures 1A, 1B, and 1C) is formed by the fusion of the premaxillary, maxillary and nasal bones, and contributes with approximately 70 to 75% of the total cranial length in *L. javanicus*, *L. dubius*, and *L. crumeniferus*. The nostrils (NA – Figures 2A, 2B, and 2C) present an oval shape, with a characteristic holorhinal type in *L. javanicus*, *L. dubius*, and *L. crumeniferus*. The length of the nostrils extends until the proximity of the craniofacial flexion zone, where it is dorsomedially delimited by the the *maxillaris* process of the *Os nasale*. The lateral maxillary process of the *Os nasale* is wide, short and inclined; the dorsal bars of the maxillary process of the nasal bone, which is long, are rostrally tapered and delimit the dorsocaudal portion of the nostril, with an homogenous configuration in the considered species. The craniofacial flexion zone occupies only the median portion between the frontal and nasal regions, with a clear lateral fusion between these two regions. The dorsal bar is fused to the rostrolateral surface of the region of the frontal bone, with the same occurring with the lateral bar, more laterally.

Palati

The palate region is formed by the palatine, pterygoid and vomer bones. The maxillary process of the palatine (*Proc. maxillaris* – PrMP, Figures 3A, 3B, and 3C) connects the caudolateral palatine lamella to the base of the superior maxilla. This process is short and narrow in its extension in all analyzed species.

The palatine caudolateral lamella of the *pars lateralis* is medially delimited by the prominent ventral palatine crest (*Crista ventralis* – CrV, Figures 3A, 3B, and 3C) of the *pars choanalis*, by the transpalatine process and laterally by the lateral palatine (*Crista lateralis* – CrL, Figures 3A, 3B, and 3C), with a deep palatine ventral fossa observed between the lateral and ventral crests of the palatine. The palatine ventral fossa is thus broad and deep, and forms most of the palatine caudolateral lamella, wide in *L. javanicus*, *L. dubius*, and *L. crumeniferus*. The ventral palatine fossa presents a projection in its caudal extremities in *L. dubius* and *L. crumeniferus*, absent in *L. javanicus*.

The ventral palatine crests (*Crista ventralis* – CrV, Figures 3A, 3B, and 3C) are located in the articulating region with the parasphenoid. The articulation with the pterygoid occurs dorsolaterocaudally via palatine *pars pterygoidea*. The ventral palatine crests are short in *L. javanicus*, *L. dubius*, and *L. crumeniferus*.

The lateral palatine crest (*Crista lateralis* – CrL, Figures 3A, 3B, and 3C) is long in *L. javanicus*, *L. dubius*, and *L. crumeniferus*. The *pars choanalis* is narrow and more developed if compared with the above-described *pars lateralis*.

The transpalatine process is absent in *L. javanicus* and present in *L. dubius* and *L. crumeniferus*.

The maxillopalatine process (PrMP, Figures 3A, 3B, and 3C) is short in *L. javanicus*, *L. dubius*, and *L. crumeniferus*.

The pterygoid process of the palatine (PrPP, Figures 3A, 3B, and 3C) appears short in *L. dubius* and *L. crumeniferus*, and long in *L. javanicus*.

The dorsal process of the pterygoid is present in *L. javanicus*, *L. dubius*, and *L. crumeniferus*.

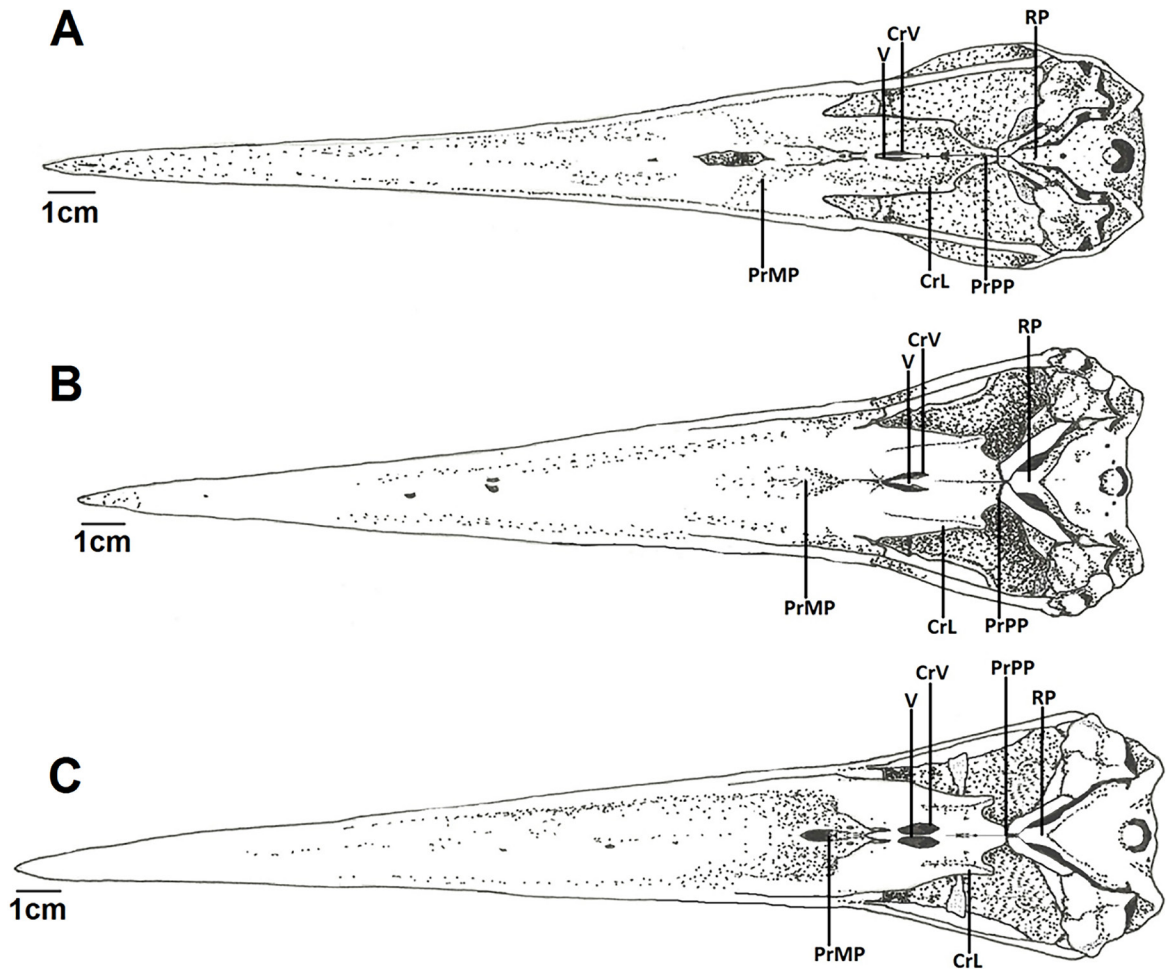


Figure 3(A-C). Ventral surfaces of the crania of *Leptoptilus crumeniferus*, *Leptoptilus dubius*, and *Leptoptilus javanicus*. **Subtitle:** CrL –lateral palatine crest; CrV –ventral palatine crest; PrMP – maxillary process of the palatine; PrPP – pterygoid process of the palatine; RP – parasphenoid rostrum; V – vomer;

The vomer (V – Figures 3A, 3B, and 3C) is rostrally sharp and is narrow in *L. javanicus*, *L. dubius*, and *L. crumeniferus*, articulating caudally with the *pars choanalis* of the palatine and with the parasphenoid rostrum through the *facies articularis vomeralis*.

The quadrate bone is located in a central region of the cranium, interconnecting the palate, the neurocranium, and the mandible. This structure plays an important role in cranial kinesis. It presents a central *corpus ossi quadrati* from which three processes emerge: orbital, optical, and mandibular.

The orbital process of the quadrate bone (*Proc. orbitalis* – PrO, Figures 2A, 2B, and 2C) is projected rostromedially in the orbit, tenuously tapering distally and ending in a bulb shape, being wide and longer in *L. javanicus*, *L. dubius*, and *L. crumeniferus*.

The optical process of the quadrate

bone (*Proc. oticus* – PrOQ, Figures 2A, 2B, and 2C) is widened from the *corpus ossi quadrati*, being well developed in *L. javanicus*, *L. dubius*, and *L. crumeniferus*. It articulates with the neurocranium in two distinct places: 1) through the external optical process, supported in the ventrocaudal surface of the zygomatic process, and 2) through the internal optical processes, which articulates with the *cotylae quadraticae otici* of the pro-optical and opisthotic bones, processes of homogenous configuration among the species.

The external and internal capitulum of the optical process of the quadrate is developed in *L. javanicus*, *L. dubius*, and *L. crumeniferus*.

The mandibular process of the quadrate presents four distinct condyles: the medial condyle, with a round shape in all analyzed species; the lateral condyle, long and more robust than the medial, articulating laterally with the jugal bar from a dorsal process; the caudal

condyle, an extension of the lateral condyle, being fused; and the *pterygoideus* condyle, located medially, which articulates with the pterygoid by its quadratic articulated surface.

The caudal condyle of the quadrate is larger than the medial condyle in *L. javanicus*, *L. dubius*, and *L. crumeniferus*.

The lateral condyle of the quadrate also comprehends the *cotyla quadratojugalis*, which articulates with the *quadraticus* condyle of the jugal bar, a subtle depression through which the jugal bar articulates with the quadrate, being conspicuous in *L. javanicus*, *L. dubius*, and *L. crumeniferus*. The medial surface of the quadrate, particularly that relative to the *corpus ossi quadrati*, possesses a characteristic fossa, more wide than deep in *L. javanicus*, *L. dubius*, and *L. crumeniferus*.

The pterygoid (*Pterygoideum*) has a rostral expansion that widens rostrorodorsally and articulates dorsolaterocaudally with the palatine through a structure named *pes pterygoidei*, observed in *L. javanicus*, *L. dubius*, and *L. crumeniferus*. In general, the pterygoid appears as a relatively flattened lamella, obliquely placed in the orbit. It articulates laterocaudally with the quadrate bone through the *facies articularis quadratica* of the quadratic process of the pterygoid, developed and conspicuous in *L. javanicus*, *L. dubius*, and *L. crumeniferus*. In this region of the pterygoid there is a foramen that does not totally cross this structure, in the more flattened surface laterolaterally, in *L. javanicus*, *L. dubius*, and *L. crumeniferus*.

The jugal bar presents the quadratic condyle that articulates with the *cotyla quadrato-jugalis*, in *L. javanicus*, *L. dubius*, and *L. crumeniferus*.

Ossa mandibulae

The *pars symphysialis mandibulae* occupies from 25 to 35% of the total length of the mandible in *L. javanicus*, *L. dubius*, and *L. crumeniferus*. The *pars intermedia* possesses a well-developed mandibular fenestra, although shallow in all its extension in *L. javanicus*, *L. dubius* and *L. crumeniferus*, whereas the *pars caudalis* hosts the muscles that move the jaws, besides being the area of articulation of the

quadrate bone, an important structure of the mandibular kinesis.

In the dorsal region of the mandible the well-developed coronoid process can be observed (*Proc. coronoideus* – PrC, Figures 3A, 3B, and 3C), the region of the supra-angular bone, at the height of the caudal portion of the mandibular fenestra. The coronoid process is present in *L. javanicus*, *L. dubius*, and *L. crumeniferus*. Caudally, the “K” process stands out. This process is present in *L. javanicus*, *L. dubius*, and *L. crumeniferus*.

In the dorsocaudal region of the mandible the *crista intercotylaris* can be observed, being pronounced in *L. javanicus*, *L. dubius*, and *L. crumeniferus*.

The lateral cotyle and the medial cotyle appear conspicuous in *L. javanicus*, *L. dubius*, and *L. crumeniferus*. The well-developed medial process projects dorsomedially, being wide in its base and narrowing distally in *L. javanicus*, *L. dubius*, and *L. crumeniferus*.

The pseudotemporal tubercle of the medial region of the mandible is inconspicuous in *L. javanicus*, *L. dubius*, and *L. crumeniferus*.

The *fossa caudalis* stands out in the caudal region, well developed in *L. javanicus*, *L. dubius*, and *L. crumeniferus*, delimited laterally with the lateral crest, medially with the medial crest, and dorsally with the *crista transversa fossae*.

Discussion

Cranial osteology

The interorbital diameter corresponds to more than 85% of the width of the parietal region in *L. javanicus*, *L. dubius*, and *L. crumeniferus*. This increase in the overlapping of the visual field may promote an increase in the hunting ability, and according to Zusi (1984), the binocular vision of some birds requires a decrease of the antorbital region.

The craniofacial flexion zone is known as a narrowing area of the nasal bones, responsible for most of the cranial kinesis (Zusi, 1984). The discussion of this character requires an analysis of the cranial kinesis in the studied bird species, considering that both are closely related since the movements of opening and closing of the

beak depend on the conformation and position of the structures that compose it. All studied specimens present a holorhinal condition of the nostrils and, in general, they present small nostrils, premaxillary strongly fused to the nasal bone, and both entirely calcified.

The temporal fossa is dorsally delimited by the superior temporal crest, and ventrally by the *crista nuchalis transversa*. The pattern of the temporal fossa in *Leptoptilos* differs from the pattern verified by Méndez (1998) in the Alcedinidae, and by Posso (1999) in the Cuculiformes, since in the species of these groups the temporal fossa is divided into two portions, and it possesses a less-developed postorbital process. The ventral palatine fossa presents a projection in the caudal extremities in *L. dubius* and *L. crumeniferus*, absent in *L. javanicus*.

According to Bock (1964, 1966), the palatine works as an origin area for several muscles and ligaments, being of utter importance in cranial kinesis in order to transmit force and to direct the movements of the mandible to the superior maxilla. The shape and thickness of the palatine are associated with the size and strength of the superior maxilla, as well as to the resistance of the muscles, as mentioned by the same author. In the present study, five characters directly related to the palate were considered: Maxillopalatine process; Lateral palatine crest; Pterygoid process of the palatine; Ventral palatine crest, and ventral palatine fossa, demonstrating the importance of this region for the systematics of the group.

The vomer is reduced and tapered rostrocaudally in all analyzed species, with the same pattern being verified by Posso (1999) in the New World Cuculiformes, by Pacotto (2000) in the Momotidae, and by Ladeira (1997) in the species of Bucconidae. Even being considered a systematically important structure by Zusi (1993), the vomer presents the same condition (bifurcate) in both Neognathae and Paleognathae birds, and presents variation (tri and/or tetrafurcate) within a same family, such as in Furnariidae (Feduccia, 1973), what obfuscates its pattern for the use by systematics researchers.

The quadrate bone is located in a central region of the cranium, interconnecting

the palate, the neurocranium, and the mandible, and developing a crucial role in cranial kinesis. Zusi (1984) comments that the presence of the postorbital ligament, along with the action of the quadrate bone and the muscles that move the jaws, allows the opening of the lower and upper jaws in a single movement. The intricate lever system might have redefined the muscular action, imprinting more speed and synchronism and thus increasing the success in the foraging behavior of the species that possess it.

General aspects of the genus Leptoptilos

Considering the phylogenetic relationship of the species of *Leptoptilos*, the present study corroborates with the hypothesis by Kahl (1971), according to which *L. crumeniferus* and *L. dubius* share specific recognition behaviors. The author justifies the difference of the behavior observed in these species from the observed in *L. javanicus* employing biogeography – in Bruma, there is an overlapping of the geographic distributions of *L. dubius* and *L. javanicus*, and the difference in the recognition behavior might justify the specific isolation.

Whereas most of the Ciconiidae present different behaviors related to thermoregulation, such as gasping with the tongue raised and bristling the feathers in order to dissipate the body heat, the species of the genus *Leptoptilos* present urohidrosis (habit of defecating onto the feathers, thus favoring the loss of heat through evaporation), whereas *L. dubius* and *L. crumeniferus* use their hanging air sac to dissipate heat and as a sexual character during the reproductive period (del Hoyo *et al.* 1992). In the present study, these two species are closer phylogenetically to each other than with any other.

Ali and Ripley (1968) approximate *L. dubius* and *L. javanicus* based on external morphological characters (such as the color and shape of the beak), which possibly might be a product of convergent evolution, instead of homology, being non-informative for phylogenetic systematics, besides differing from the data raised in the present study.

Conclusions

Based on the description and the analysis of the osteological characters of the cranium in species of *Leptoptilus*, it was possible to observe some structures and characteristics that differed within each other: *L. javanicus* possesses, in the lateral portion of the cranium, an emargination of the rostradorsal edge of the postorbital process, not observed in *L. dubius* and *L. crumeniferus*. The ventral palatine fossa presents a projection in the caudal extremities in *L. dubius* and *L. crumeniferus*, absent in *L. javanicus*. The transpalatine process is present in both *L. dubius* and *L. crumeniferus*, and is absent in *L. javanicus*. The pterygoid process of the palatine is short in *L. dubius* and *L. crumeniferus*, and long in *L. javanicus*. The ectethmoid is reduced in *L. dubius* and *L. javanicus*, whereas in *L. crumeniferus*, besides being more developed, it assumes a "U" shape. Based on the present study, *L. dubius* and *L. crumeniferus* are closer to each other than with *L. javanicus*.

REFERENCES

- AGNOLIN, F.L. 2004. Revisión sistemática de algunas aves deseádenses (Oligoceno Medio) descritas por Ameghino en 1899. *Revista del Museo Argentino de Ciencias Naturales*, n. s., 6 (2): 239–244.
- ALI, S.; RIPLEY, D. *Handbook of the birds of India and Pakistan*. London: Oxford University Press, 1968. v.1.
- ALI, S. and S. D. RIPLEY. 1987. *Compact handbook of the birds of India and Pakistan*. Second edition. Oxford University Press, Mumbai.
- BAKER, E. C. S. 1929. *The fauna of British India* Vol. 6. Taylor and Francis, London.
- BIRDLIFE INTERNATIONAL (2011) *Species factsheet: Leptoptilos javanicus*. <http://www.birdlife.org> [accessed 9 March 2011].
- BAUMEL, J.; KING, A.S.; LUCAS, A.M.; BREAZILE, J.E.; EVANS, H.E. *Nomina anatomica avium*. London: Academic Press, 1993. 637p.
- BOCK, W.J. Kinetics of the avian skull. *J. Morphol.*, v.114, n.1, p.1-52, 1964.
- BOCK, W.J. An approach to the functional analysis of bill shape. *Auk*, v.83, p.10-51, 1966.
- BOCK, W.J. Osteology of *Pedionomus torquatus* (Aves: Pedionomidae) and its allies. *Proc. R. Soc. Vic.*, v.82, n.2, p.187-232, 1969.
- COULTER, M.C.; BRYAN, A.L.; YOUNG JR., D.P.; BROUWER JR., K.; KAHL, M.P.; KING, C.E.; KUSHLAN, J.A.; LUTHIN, C.S., VAN WIERINGEN, V. *A bibliography of storks, ibises, and spoonbills*. Aiken: Savannah River Ecology Laboratory, 1991.
- DEL HOYO, J.; ELIOTT, A.; SARGATAL, J. (Eds.). *Handbook of the birds of the world*. Barcelona: Lynx, 1992. 2v.
- DONATELLI, R.J. *Anatomia craniana e aspectos evolutivos de Picidae (Aves, Piciformes) Neotropicais e Afrotropicais*. 1991. 154f. Tese (Doutorado em Ciências, Área de Zoologia) - Instituto de Biociências, Universidade de São Paulo, São Paulo.
- DONATELLI, R.J. The jaw apparatus of the neotropical and of the afrotropical woodpeckers (Aves: Piciformes). *Arq. Zool.*, v.33, p.1-70, 1996.
- DONATELLI, R.J. Osteologia e miologia cranianas de Dendrocolaptidae (Passeriformes, Tyranni). Gêneros *Glyphorhynchus*, *Campylorhynchus*, *Dendrocincla*, *Xiphorhynchus* e *Dendrocolaptes*. *Ararajuba Rev. Bras. Ornitol.*, v.5, p.19-37, 1997.
- ELLIOT, A. 1992. Ciconiidae [species account]. In: J. DEL HOYO, A. ELLIOTT, and J.
- ELLIOT, A., DEL HOYO, J. & SARGATAL, J. (1994) *Handbook of the Birds of the World. Volume 1. Ostrich to Ducks*. Lynx Edicions, Barcelona, Spain.
- FEDUCCIA, A. 1996. The Origin and Evolution of Birds 420pp. Yale University Press, New Haven.
- FEDUCCIA, A. Evolutionary trends in the Neotropical ovenbirds and woodpeckers. ornithological monographs. *Am. Ornithol. Union*, n.13, p.1-69, 1973.
- FLAUSTINO JR., O.A.; DONATELLI, R.J.; PASCOTTO, M.C. Osteologia e miologia cranianas de *Momotus momota* (Coraciformes: Momotidae). *Ararajuba Rev. Bras. Ornitol.*, v.7, n.2, p.109-124, 1999.
- FLEMING, R. L., Sr., R. L. Fleming, Jr. and L. S. Bangdel. 1979. *Birds of Nepal* (second edition). Avalok Publishers, Kathmandu, Nepal.
- GUZZI, A. *Osteologia craniana e aspectos evolutivos de Sclerurus (Aves: Furnariidae)* 2003. 125f. Dissertação (Mestrado) - Departamento de Zoologia, Instituto de Biociências, Universidade de São Paulo, São Paulo.
- HANCOCK, J.A.; KUSHLAN, J.; KAHL, M.P. *Storks, ibises, and spoonbills of the world*. San Diego: Academic Press, 1992. 385p.
- HÖFLING, E.; GASC, J.P. Biomécanique du crâne et du bec chez *Rhamphastos* (Aves, Rhamphastidae). *Gegenbaurs Morphol. Jahrb.*,

v.130, p.125-147, 1984.

HÖFLING, E. *Anatomia do crânio e da cintura escapular dos Ramphastidae (Aves: Piciformes) e de alguns grupos próximos, com implicações sistemáticas*. 1995. 185f. Tese (Doutorado em Ciências, Área de Zoologia) - Instituto de Biociências, Universidade de São Paulo, São Paulo.

HOWARD, R.; MOORE, A. *A complete checklist of the birds of the world*. 2.ed. San Diego: Academic Press, 1998. 630p.

JOLLIE, M. The read skeleton of the chickens and remarks on the anatomy of this region in other birds. *J. Morphol.*, v.100, p.389-436, 1957.

KAHL, M.P. Social behavior and taxonomic relationships of the storks. *Living Bird*, v.10, p.151-170, 1971.

KAHL, M.P. A revision of the family Ciconiidae (Aves). *J. Zool. (London)*, v.167, p.451-461, 1972.

KAHL, M.P. Suborder Ciconiae, family Ciconiidae. In: MAYR, E.; COTRELL, G.W. (Eds.). *Check-list of birds of the world*. Cambridge: Museum of Comparative Zoology, 1979. v.1, p.245-253.

LADEIRA, L.M.C.E.B. *Osteologia craniana de Bucconidae (Aves: Piciformes)*. 1997. 80f. Dissertação (Mestrado) - Instituto de Biociências, Universidade de São Paulo, São Paulo.

MARCELIANO, M.L. *Estudo osteológico e miológico do crânio de Opisthocomus hoazin (Muller, 1776) (Aves: Opisthocomidae) comparado com algumas espécies de Cracidae, Musophagidae e Cuculidae*. 1996. 95f. Tese (Doutorado) - Instituto de Biociências, Universidade de São Paulo, São Paulo.

MARCELIANO, M.L.; DONATELLI, R.J.; HÖFLING, E.; POSSO, S.R. Osteologia e miologia cranianas de Psophiidae (Aves, Gruiformes). *Bol. Mus. Para. Emílio Goeldi*, v.13, n.1, p.12-38, 1997.

MAUST, M., CLUM, N. & SHEPPARD, C. (2007) Ontogeny of chick behavior: a tool for monitoring the growth and development of lesser adjutant storks. *Zoo Biology*, 26, 533-538.

MÉNDEZ, A.C. *Osteologia craniana de Alcedinidae Neotropicais (Aves: Coraciformes)*. 1998. 104f. Dissertação (Mestrado) - Instituto de Biociências, Universidade de São Paulo, São Paulo.

NORIEGA, J.I. 1995. *The avifauna from the "Mesopotamian" (Ituzaingó Formation; Upper Miocene) of Entre Ríos Province, Argentina*. *Courier Forschungsinstitut Senckenberg* 181: 141-148

NORIEGA, J.I. and AGNOLIN, F.L. 2006. *Nuevos aportes al conocimiento de la avifauna del "Mesopotamiense" (Mioceno Tardío, Formación Ituzaingó) en Entre Ríos, Argentina*. 9º Congreso Argentino de Paleontología y Bioestratigrafía. Academia Nacional de Ciencias, Resúmenes, 53. Córdoba, Provincia de Córdoba, Argentina. *Northern Plains of Cambodia*. Wildlife Conservation Society, Phnom Penh, Cambodia.

OLSON, S.L. The fossil record of birds. In: FARNER, D.S.; KING, J.R.; PARKES, K.C. (Eds.). *Avian biology*. New York: Academic Press, 1985. v.8, p.79-238.

PASCOTO, M.C. *Osteologia craniana de Momotidae (Aves, Coraciformes), com implicações filogenéticas*. 2000. 138f. Dissertação (Mestrado) - Instituto de Biociências, Universidade Estadual Paulista, Botucatu.

POSSO, S.R. *Osteologia craniana dos Cuculiformes do Novo Mundo com implicações sistemáticas*. 1999. 142f. Dissertação (Mestrado) - Instituto de Biociências, Universidade Estadual Paulista, Botucatu.

RAHMANI, A. R. 1989. Blacknecked and Greater Adjutant Storks in India. CBP/IWRB. Specialist Group on Storks, Ibises and Spoonbills Newsletter 2: 3-6.

RAHMANI, A. R., G. NARAYAN and L. ROSALIND. 1990. Status of the Greater Adjutant Stork (*Leptoptilos dubius*) in the Indian sub-continent. *Colonial Waterbirds* 13:138-142.

SAIKIA, P. and P. C. BHATTACHARJEE. 1989a. Adjutant Storks at risk in Assam, India. ICBP/IWRB Specialist Group on Storks, Ibises and Spoonbills Newsletter 2: 6-8.

SAIKIA, P. and P. C. BHATTACHARJEE. 1989b. A Preliminary Survey of Adjutant Storks in Assam. *Asian Wetlands News* 2: 14-15.

SALAKIJ, C., SALAKIJ, J., ROCHANAPAT, N. & PITAKKINGTHONG, D. (2004) Hematology, morphology and cytochemistry of blood cells in lesser adjutant (*Leptoptilos javanicus*) and greater adjutant (*Leptoptilos dubius*). *Kasetsart Journal (National Science)*, 38, 400-408.

SARGATAL (eds.), *Handbook of the Birds of the World. 1. Ostrich to Ducks*. 456-465. Lynx Edicions, Barcelona.

SIBLEY, C.G.; AHLQUIST, J.E. Classification of birds based on DNA-DNA hybridization. In: _____. *Phylogeny and classification of birds: a study in molecular evolution*. New Haven: Yale University Press, 1990. p.253-264.

SILVEIRA, L.F. *Osteologia craniana dos Tinamidae (Aves: Tinamiformes), com implicações sistemáticas*. 1999. 109f. Dissertação (Mestrado)

- Instituto de Biociências, Universidade de São Paulo, São Paulo.

SLIKAS, B. 1997. Phylogeny of the avian family Coniidae (Storks) based on Cytochrome *b* sequences and DNA-DNA hybridization distances. *Mol. Phylogenet. Evol.*, v.8, n.3, p.275-300, 1997.

VISAL, S. & CLEMENTS, T. (2008) *Monitoring of large water birds at Prek Toal, Tonle Sap Great Lake 2008*. Wildlife Conservation Society Cambodia Program and Ministry of Environment, Phnom Penh, Cambodia.

ZUSI, R.L. A functional and evolutionary analysis of rhynchokinesis in birds. *Smithson. Contrib. Zool.*, v.395, p.1-40, 1984.

ZUSI, R.L.; LIVEZEY, B.C. Phylogenetic significance of zygomatic and postorbital processes of Anseriformes and Galliformes. *Ostrich*, v.69, p.414-415, 1988.

ZUSI, R. L. Patterns of diversity in the avian skull. In: HAKEN, J.; HALL, B.K. (Eds.). *The skull*. Chicago: Chicago University Press. v. 2, p. 391-437, 1993.