

# Mantle Cell Lymphoma – a less frequent presentation

Tiago Alves, Inés Coelho, Mário Santos, Teresa Inés

*Serviço de Medicina II, Hospital de Abrantes. Centro Hospitalar do Médio Tejo. Tomar. Portugal*

*Serviço de Medicina Interna I, Hospital de Abrantes. Centro Hospitalar do Médio Tejo. Tomar. Portugal*

## ABSTRACT

The clinical manifestations of non-Hodgkin's lymphomas (NHL) are unspecific and may vary with their location, growth rate or organs involved. Chylothorax consists of an accumulation of chyle in pleural space. Lymphoproliferative diseases represent the main non-traumatic aetiology. The authors report the case of an 81-year-old woman admitted with right pleural effusion and lower limbs oedema, initially interpreted as decompensated heart failure. The thoracentesis revealed a chylothorax and the aetiological study exposed a mantle cell lymphoma. The authors aim to alert to a less frequent presentation of NHL and remind that a low suspicion may delay the diagnosis.

**Keywords:** Chylothorax, Mantle, Lymphoma

## INTRODUCTION

The chyle is formed by chylomicrons and very low density lipoproteins absorbed in small intestine and secreted to intestinal lymphatics. Approximately a total of 2.4 litres of chyle are transported every day through the lymphatic system. Chylothorax results from a rupture, laceration or obstruction of the thoracic duct that leads to a large accumulation of chyle in the pleural space<sup>1</sup>. This condition was first described in 1633 by Bartolet<sup>2</sup>. The aetiology of the chylothorax can be traumatic or non-traumatic. In the group of non-traumatic, malignancy is the main cause, and lymphomas are found in 70% of the cases<sup>1</sup>. The diagnosis of chylothorax is made through pleural fluid analyses. The fluid usually has a milky appearance and present a level of triglyceride >110mg/dl and cholesterol <200mg/dl. A triglyceride level <50mg/dl with a cholesterol >200 mg/dl is found in pseudochylothorax usually associated with old exudative effusion that remains in pleural space<sup>1</sup>.

## CLINICAL CASE

The authors report a case of an 81-year-old woman who presented to the emergency department due to dyspnea, orthopnea, easy fatigue and worsening of lower limb oedema with 3 weeks of evolution. The patient had history of arterial hypertension treated with lisinopril plus hydrochlorothiazide 20+12.5mg id.

At the physical examination, the patient was conscious and oriented, afebrile with tympanic temperature of 37.2°C, blood pressure: 142/86mmHg, heart rate: 89bpm, tachypnoeic with respiratory rate of 24cpm with oxygen saturation of 89% with FiO<sub>2</sub>: 21%. Skin and mucous membranes had normal colour, and didn't present jugular vein engorgement. Pulmonary auscultation with abolished vesicular murmur at the base of the right hemithorax. Cardiac auscultation without changes. The abdominal exam was normal, without organomegaly or ascites. Bilateral malleolar oedema with Godet sign +. The laboratory study revealed leukocytosis: 9.400/ul with 93% neutrophilia, C-reactive protein: 4.3mg/dl, creatinine: 1.3mg/dl, urea: 35mg/dl, LDH: 732U/L.

The chest radiography showed bilateral pleural effusion moderate at right and slight at left with an increased cardiothoracic index.

The condition was interpreted as decompensated heart failure, and the patient was admitted for hospitalization for therapeutic

optimization. At the medical nursery, a thoracentesis was performed, which revealed a milky pleural fluid, with the following biochemical analyses: total leukocyte count: 2.500/mm<sup>3</sup> (98% lymphocytes), triglycerides: 1899mg/dl, cholesterol: 123mg/dl, LDH: 452 IU/L, pH: 7.0, Proteins: 2.8g/dl, glucose: 155mg/dl, adenosine deaminase: 16.0U/L. Pleural fluid was negative for acid-fast bacilli and sterile on culture.

Due to the absence of recent surgery or trauma, to exclude a malignancy aetiology a thoraco-abdomino-pelvic computed tomography was performed, which revealed bilateral pleural effusion, with medium volume on the right hemithorax, with slight cardiomegaly, without pericardial effusion. Normal pulmonary parenchyma and no mediastinal, hilar or axillary adenomegalies. In the abdominal cavity was observed a voluminous adenopathic inter-aortic-cava conglomerate, where a mass with around 7cm stood out. Multiple adenopathies in the celiac trunk and hepatic hilus were also visible.

The patient underwent a biopsy of the mesenteric adenopathy, whose histological result revealed Mantle Cell Non-Hodgkin's Lymphoma, classified as stage IV with serous involvement. The Oncologist was contacted and, considering the characteristics of the patient, started chemoimmunotherapy with R-mini-CHOP scheme (Rituximab, Cyclophosphamide, Doxorubicin, Vincristine and Prednisolone). During hospitalization, as a result of respiratory worsening a chest drainage was performed along with a low-fat diet (medium chain triglycerides), with significant improvement. After 6 cycles of R-mini-CHOP chemoimmunotherapy the patient achieved complete response and is currently on remission on Rituximab therapy.

## DISCUSSION

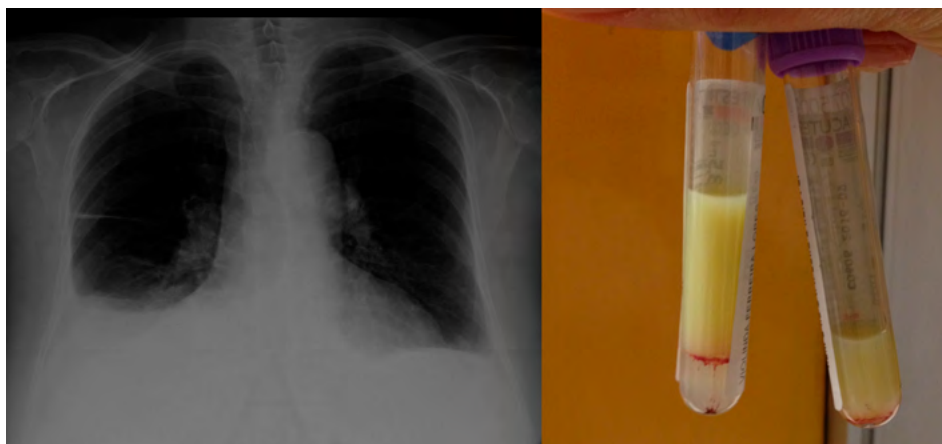
The clinical manifestations of non-Hodgkin's lymphomas (NHL) are unspecific and may vary with their location, growth rate or organs involved. The typical manifestation that include the B-symptoms<sup>3</sup> (fever, weight loss exceeding 10% of body weight in 6 months, drenching night sweats), adenomegalies or splenomegaly aren't always present, and their presence might be associated with aggressive behaviour lymphomas or advance stage disease. The mantle cell lymphoma represents less than 10% of all NHL and has a heterogeneous clinical behaviour ranging from indolent to very aggressive<sup>3</sup>. In this case, the patient didn't have any B-symptom or suspect adenomegalies or organomegaly at the physical examina-

Correspondencia: tiago.pereira.alves88@gmail.com

Cómo citar este artículo: Alves T, Coelho I, Santos M, Inés T. Mantle Cell Lymphoma – a less frequent presentation. *Galicia Clin* 2020; 81 (3): 83-84

Recibido: 11/01/2019; Aceptado: 04/02/2019 // <http://doi.org/10.22546/57/1879>

Figure 1. Posterior-anterior chest radiograph with bilateral pleural effusion (left), pleural effusion sample (right)



tion. The dyspnea and orthopnea caused by the chylothorax were the principal symptoms that drove the patient to the emergency department. In fact, these symptoms associated with oedema of the lower limbs, right pleural effusion and increased cardiothoracic index may fit in a context of decompensated heart failure. Thoracentesis was essential for the patient's diagnostic. In the presence of non-traumatic chylothorax it's mandatory to exclude malignancy, in which lymphoproliferative diseases represent 70% of the situations. Less frequent non-traumatic aetiologies are metastases, sarcoid or tuberculosis<sup>2</sup>.

Considering the age, comorbidities of the patient and toxicity of the chemoimmunotherapy, it was decided to initiate R-mini-CHOP (reduced doses of cyclophosphamide and doxorubicin) followed by rituximab maintenance, that has been shown to be a good compromise between efficacy and safety in older patients<sup>4,5</sup>.

The chylothorax treatment can be complex and differs according to the aetiology. The first principle approach is to treat the underlying disease. However, in the case of lymphomas, chemotherapy may improve the disease burden, but sometimes it doesn't translate into an improvement in chylothorax. Other strategies include low-fat diet with medium

chain triglycerides, total parenteral nutrition, somatostatin or analogues drugs. The need for invasive procedures such as chemical or surgical pleurodesis should be evaluated on a second phase, depending on the patient's evolution and characteristics<sup>2</sup>. Our patient presented a very good response to chemotherapy, maintaining complete remission under Rituximab therapy, without exacerbation of the chylothorax.

With this case the authors aims to alert to an uncommon presentation of Non-Hodgkin's Lymphoma and remind that sometimes the low suspicion and the unspecific symptomatology may delay the correct diagnosis and jeopardise the patient's prognosis.

## REFERENCES

1. McGrath EE, Blades Z, Anderson PB. Chylothorax: aetiology, diagnosis and therapeutic options. *Respir Med* 2010;104(1):1-8.
2. Patel S, Kim AW. Thinking outside the duct. *J Thorac Cardiovasc Surg* 2018;155:820-1.
3. Cohen JB, Zain JM, Kahl BS. Current Approaches to Mantle Cell Lymphoma: Diagnosis, Prognosis, and Therapies. *Am Soc Clin Oncol Educ Book*. 2017;37:512-525.
4. Hammersen J, Rüttrich MM, Kleber M, Wedding U, Sommer M, Müller D et al. R-Mini-CHOP Versus R-Bendamustine As Primary Treatment for Diffuse Large B-Cell Lymphoma (DLBCL) in Elderly and Comorbid Patients. *Blood* 2014;124(21):5436.
5. Hoster E, Kluin-Nelemans H, Hermine O, Walewski J, Trnety M, Geisler CH et al. Rituximab Maintenance after First-Line Immunochemotherapy in Mantle Cell Lymphoma: Long-Term Follow-up of the Randomized European MCL Elderly Trial. *Blood* 2017;130(1):153.

Figure 2. CT-scan of adenopathic inter-aortic-cava conglomerate in transversal plane (left) and coronal plane (right)

