

## Electrocardiography in Times of COVID-19 (Prone Leads)

### *Electrocardiografía en tiempos de COVID-19 (Derivaciones pronas)*

RICARDO LEVIN<sup>1</sup> , FERNANDO LIPOVETSKY<sup>2</sup>, MARCO GARCÍA AURELIO<sup>1</sup>

The images correspond to an 82-year-old male patient who was admitted with severe pneumonia and positive diagnosis for COVID-19, requiring mechanical ventilation. In view of his unfavorable course, with hypoxemia refractory to the use of high fraction of inspired oxygen (PaO<sub>2</sub>/FiO<sub>2</sub> ratio of 152), the patient was positioned in prone position, as a ventilation strategy.

Several electrocardiograms were recorded in that position. Prone (Pr) leads were placed on the patient's back, in a scheme equivalent to the use of right precordial leads, where "V1Pr" (V1 prone) was placed in the dorsal equivalent to V1R (or conventional V2); "V2Pr" was placed in the dorsal equivalent to V2R (or conventional V1); and likewise, "V3Pr" to "V6Pr" were placed in positions similar (but always on the back) to V3R to V6R leads, respectively.

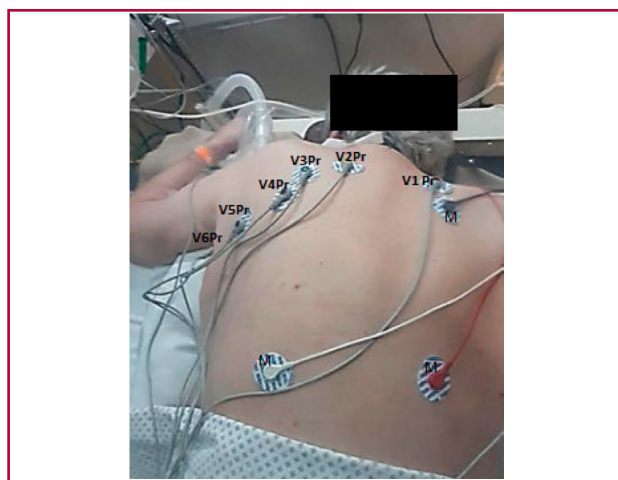
Compared with the electrocardiogram in supine position, it is evident the similarity between the limb-lead tracings (whose placement has to be reversed) and a variation in the recording of the precordial prone leads with lower voltage, as a result of the greater distance between the heart and the scanning electrodes (Figure 2 A and B), which would set a low voltage in a different context.

An image consistent with counterclockwise rotation was also observed, with images of the left ventricle that were evident from V2Pr and V3Pr.

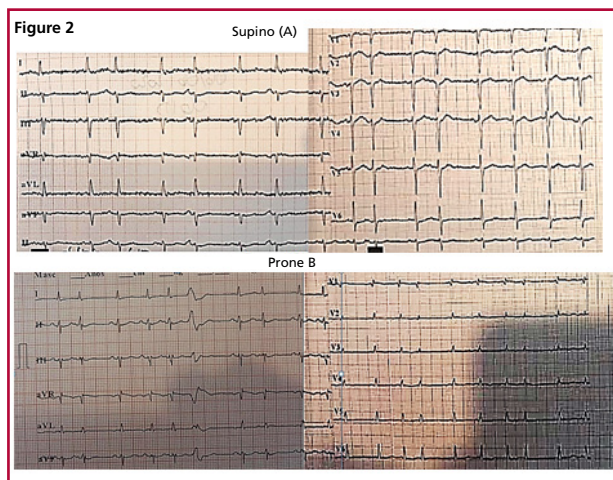
The global COVID-19 pandemic confronts us with new strategies for the management of critical patients, particularly due to the imposition of various mechanical ventilation strategies that sometimes force us to adapt our usual cardiology practice, such as electrocardiographic recordings, in this case, with the use of "prone" leads.

#### Conflicts of interest

None declared (See authors' conflicts of interest forms on the website/ Supplementary Material).



**Fig. 1.** The image shows prone (Pr) leads from V1Pr to V6Pr. The electrodes connecting to the monitor (M) can also be observed.



**Fig. 2.** Figure A shows the electrocardiogram in supine position, while Figure B shows the electrocardiogram of the same patient in prone position.