

Heart failure: the importance of getting the right cause

Sara Freitas¹, Joana Marques¹, Ana Grilo¹, Pedro António²

¹Servicio de Medicina Interna, Hospital Beatriz Ângelo, Loures, Portugal

²Servicio de Cardiología, Hospital de Santa Maria, Lisboa, Portugal

ABSTRACT

Amyloidosis is a systemic disease, with an incidence of 5-12 people per million per year. Autopsy studies suggest a higher incidence¹. Is characterized by deposition of amyloid fibrils in extracellular tissue of various organs and systems, and therefore with multiple possible presentations. The causative amyloid fibril deposits are of monoclonal light chain (AL) or transthyretin (TTR) in most cases. TTR amyloidosis may be acquired, associated with wild type TTR or hereditary (associated with variants in TTR gene² (table 1).

The AL amyloidosis condition can occur alone or associated with multiple myeloma or other B-cell dyscrasias³. The main affected organs in AL amyloidosis are the heart, kidney, liver, gastrointestinal tract and the peripheral and autonomic nervous systems. Patients often present with non-specific symptoms, such as asthenia, weight loss, palpitations and syncopal attacks⁴. Thus, diagnosis is usually delayed, and renal and cardiac failure can be forms of presentation.

We report a case of a 68-year-old woman, who presented with new onset heart failure as the main presentation form of multiple myeloma with associated cardiac amyloidosis. This case highlights the need of a high level of suspicion in order establish an early diagnosis and initiate specific therapy, and therefore delay the development of this condition.

Keywords: Amyloidosis; heart failure; multiple myeloma.

Palabras Clave: Amilosis, insuficiencia cardiaca, mieloma múltiple.

CLINICAL CASE

A 68-year-old woman, with no relevant medical history, was admitted in the emergency department due to asthenia and marked limitation in activity due to shortness of breath when walking short distances, progressive in the last 3 months.

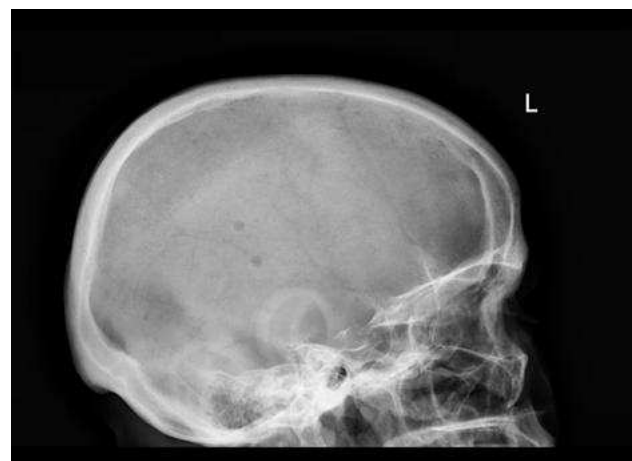On examination she had profuse sweating, blood pressure (BP) 89/52mmHg, heart rate of 55bpm, eupnoeic at FiO₂ 21%, rhythmic heartbeat, without murmurs, and presented mild crepitations on the right pulmonary base. There was no peripheral oedema nor other abnormalities at examination. The electrocardiogram (ECG) showed junctional rhythm, frequent ventricular ectopies, low voltage in frontal leads and pathological Q waves in inferior and anterior (V1 to V4). Plasma levels of N-terminal pro b-type natriuretic peptide (NT pro-BNP) were markedly increased (7676 pg/ml) and troponin levels were mildly increased (table 2). Echocardiogram showed concentric left ventricle hypertrophy with posterior wall thickening (14 mm), interventricular septum thickening (17mm), mild pericardial effusion and high left ventricle (LV) filling pressures (E/E': 25.08). The LV ejection fraction was preserved (59.7%).

An infiltrative cardiomyopathy was suspected in the context of possible systemic disease and the patient was admitted at the Internal Medicine department. Plasma cell dyscrasia with high free light chain lambda was detected (table 2). Myelogram showed 24% plasma cells, but bone marrow biopsy was inconclusive (without sufficient tissue).

No amyloid deposits were found in abdominal fat, stomach, duodenum or rectum biopsies. Radionuclide bone scintigraphy with ^{99m}Tc-Hydroxymethylene diphosphonate (HMDP) showed multiple rib fractures but no evidence of myocardium involvement. Multiple

lytic lesions were documented on the skull x-ray (figure 1). Thoraco-abdominal TC scan revealed mild pleural effusion plus heterogenic bone trabeculation and centimetric lytic bone lesions in pelvic bones.

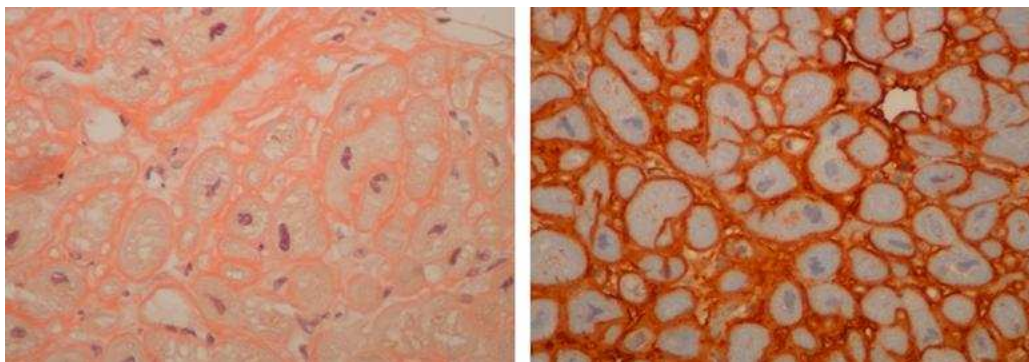
Figure 1. Lateral radiography of skull showing multiple lytic lesions.



During hospitalization the patient developed symptomatic bradycardia and a pacemaker was implanted. Due to intracardiac thrombus detection, hypocoagulation treatment was initiated.

After clinical stabilization she was discharged on diuretic treatment and referred to the Haematology clinic. However, shortly after she

Figure 2. Myocardial biopsy. Congo red staining of the interstitial amyloid (left). Lambda light chain positive immunostaining in the pericellular deposit consistent with AL amyloidosis with an immunoperoxidase method (right).



deteriorates again and was readmitted with heart failure (HF), this time at the Cardiology department. Endomyocardial biopsy was performed and amyloid fibrils were detected with Congo red staining and sulphated alcian blue staining. Immunocytochemical test was positive for lambda chains (figure 2). Despite the targeted treatment, unfortunately the patient died 3 weeks later due to refractory HF.

DISCUSSION

Cardiac involvement is common in AL amyloidosis, (approximately in 60%⁵) but only in 5% is present isolated cardiac involvement⁶. Myocardium involvement is also common in ATTR⁷.

Usually right-sided congestive HF symptoms dominate. Low BP, also present in our patient, is very common, mainly due to poor cardiac output but also due to peripheral vasomotor dysfunction secondary to autonomic neuropathy⁸.

NT pro-BNP has prognostic value and elevated troponin lev-

els are common reflecting myocardial cardiac injury⁷. Low voltage in ECG is more common in AL-type amyloidosis and has a documented prevalence of 46% to 74%^{5,9,10}.

Typical findings in echocardiogram include thickening of ventricular walls (commonly in a concentric pattern), diastolic dysfunction, restrictive filling in advanced disease, atrial septum thickening, biatrial enlargement, thickened valves and pericardial effusion. However, although a widely accessible tool, echocardiogram is neither sensitive nor specific for cardiac amyloidosis⁸.

Cardiac magnetic resonance imaging has much greater diagnostic value, with some characteristic findings as diffuse subendocardial or transmural gadolinium enhancement coupled with myocardial and blood-pool gadolinium kinetics².

Scintigraphy is an important tool in cardiac amyloidosis investigation. For instance, 99mTc-HMDP is an effective radiotracer in identifying TTR cardiac amyloidosis but not in AL

Table 1. Amyloidosis types with frequent cardiac involvement, clinical features, diagnostic modalities and treatment. HF – heart failure; HFpEF – heart failure with preserved ejection fraction (adapted from Bhogal et al., 20187)

Amyloidosis type	Primary light chain amyloidosis (AL)	Familial amyloidosis (ATTR)	Senile cardiac amyloidosis (SSA)
Protein involved	Monoclonal light chain	Variants of transthyretin with >120 mutations	Wild type transthyretin
Cardiac features	HFpEF, atrial/ventricular arrhythmias and first/second degree or advanced heart block	HFpEF, atrial/ventricular arrhythmias and first/second degree or advanced heart block	HFpEF, atrial/ventricular arrhythmias and first/second degree or advanced heart block
Extracardiac features	Characteristic findings: periorbital edema and macroglossia Other findings: hepatomegaly, nephrotic syndrome, purpura, easy bruising, carpal tunnel syndrome, peripheral neuropathy	Hepatomegaly, nephrotic syndrome, purpura, easy bruising, carpal tunnel syndrome, peripheral neuropathy	Bilateral carpal tunnel syndrome
Diagnostic modalities	Serum and urine protein electrophoresis, detection of free light chains, biopsy of affected organs	Technetium pyrophosphate, genetic testing, biopsy of affected organs	Exclusion diagnostic, biopsy of affected organs
Treatment	HF therapy, chemotherapy, heart transplant followed by autologous SCT	HF therapy, liver transplant, combined liver and heart transplant, Tafamidis	HF therapy, liver transplant

Table 2. Relevant laboratory values. LDH: lactate dehydrogenase; NT-pro BNP: N-terminal pro b-type natriuretic peptide; CRP: C reactive protein; Ig: immunoglobulins;

Exam	Results (normal range)
Haemoglobin	12.3 (12-16g/dl)
Glucose	81 (74-106mg/dl)
Urea	70 (17-49mg/dl)
Creatinine	1,07 (0,5-0,9mg/dl)
LDH	355 (132-214IU/L)
Troponin I	0.34 (<0.16ug/L)
NT pro-BNP	7676 (<300pg/ml)
Albumin	2.5 (3.5-5.2g/dl)
CRP	0.37 (<0.5mg/dl)
Sodium	143 (136-145mmol/L)
Potassium	3.9 (3.1-5.1mmol/L)
Calcium corrected to hypoalbuminemia	7.7 (8.8-10.2mg/dl)
Serum protein electrophoresis	Normal range
Urine analysis	Mild proteinuria
Serum immunofixation	monoclonal spike light chain lambda/free light chain lambda
Serum Ig A,G,M and D	Normal range
Serum free light chain lambda	403 (8.3-27mg/L)
Serum free light chain kappa	7 (6.7-22.4mg/L)
Serum free kappa/lambda ratio	0.02 (0.31-1.56)
24h-urine light chain lambda	24.6 (<1mg/dl)
24h-urine light chain kappa	0.9 (<1mg/dl)
Bence Jones protein	detected
Beta-2 microglobulin	2.52 (0.9-1 mg/dl)

amyloidosis¹¹. This explains the absence of cardiac involvement evidence in this case report.

The diagnosis is usually obtained through biopsy of a clinically affected organ, with Congo histology demonstrating pathognomonic green birefringence appearance under polarized light. Fat pad biopsy and rectal mucosa are usually initially preferred since they are mild invasive procedures. When those are negative, endomyocardial biopsy may be necessary since it has 100% sensitivity⁶.

Treatment depends on the type of amyloidosis, main organ involvement and disease extent (table 1). In AL amyloidosis the base treatment is chemotherapy with or without stem

cell transplantation, according to the underlying disease and stage. However, the presence of cardiac amyloidosis increases morbimortality rates from intensive chemotherapy¹². Cardiac amyloidosis treatment consists mainly on diuretics although this therapy should be carefully managed to prevent severe hypotension. Other drugs like beta-blockers, digoxin and certain calcium blockers should be avoided. Cardiac pacing may be necessary when there are conduction disturbances¹², as described in this case. The prognosis of AL amyloidosis with cardiac involvement is poor, with a mean survival of 10-14 months and the cause of death in 50% of cases is cardiac⁶.

In conclusion, AL amyloidosis is a rare, serious disease that requires a high suspicion level in order to diagnose based on clinical, imagological and histological exams. This is essential in order to initiate appropriate treatment at an initial stage of the disease since the prognosis is poor, in particular when cardiac involvement is present.

LEARNING POINTS

- A high level of suspicion is crucial to diagnose amyloidosis;
- A positive biopsy establishes the definite diagnosis, but other diagnostic technics are extremely important in guiding the investigation;
- Determining the underlying cause of amyloidosis is essential in order to initiate specific treatment.

REFERENCES

1. Keller FA, Jamshidi P, Boeck B De, Glatz K, Nowack M. Cardiac Amyloidosis Presenting With Myocardial Ischemia: Case Report and Literature Review. *J Med Cases*. 2016;7:531-5.
2. Gillmore JD, Maurer MS, Falk RH, Merlini G, Damy T, Dispenzieri A, et al. Nonbiopsy diagnosis of cardiac transthyretin amyloidosis. *Circulation*. 2016;133:2404-12.
3. Triantafyllou AI, Kapelakis IE, Triantafyllou EA, Lampropoulos KM, Manolis AS. Cardiac Amyloidosis: Mini Review and a Case Report. *Int J Cardiol Lipidol Res*. 2015;2:14-9.
4. Magesh B, Kadeli D, Bohra S, Krishnaprasath V, Keshava R. Cardiac amyloidosis, an infiltrative heart disease presenting as arrhythmia - A case report. *J Clin Diagnostic Res*. 2017;11:14-5.
5. Dubrey S, Cha K, Anerson J, Chamarthi B, Reisinger J, Skinner M, et al. The clinical features and outcomes of immunoglobulin light-chain amyloidosis with heart involvement. *Q J Med*. 1998;91:141-57.
6. Fernandes A, Caetano F, Almeida I, Paiva L, Gomes P, Mota P, et al. Diagnostic approach to cardiac amyloidosis: A case report. *Rev Port Cardiol*. 2016;35:1-7.
7. Bhogal S, Ladia V, Sitwala P, Cook E, Bajaj K, Ramu V, et al. Cardiac Amyloidosis: An Updated Review With Emphasis on Diagnosis and Future Directions. *Curr Probl Cardiol*. 2018;43:10-34.
8. Fikre M, Palecek T, Kuchynka P, Nemecek E, Bauerova L, Straub J, et al. Cardiac amyloidosis: A comprehensive review. *Cor Vasa*. 2013;55:60-75.
9. Murtagh B, Hammill SC, Gertz MA, Kyle RA, Tajik AJ, Grogan M. Electrocardiographic findings in primary systemic amyloidosis and biopsy-proven cardiac involvement. *Am J Cardiol* 2005;95:535-7.
10. Rahman JE, Helou EF, Gelzer-Bell R, Thompson RE, Kuo C, Rodriguez ER, et al. Noninvasive Diagnosis of Biopsy-Proven Cardiac Amyloidosis. *J Am Coll Cardiol*. 2004;43:410-5.
11. Andrikopoulou E, Bhambhani P. Nuclear imaging of cardiac amyloidosis. *J Nucl Cardiol*. 2017;18:1-4.
12. Selvanayagam JB, Hawkins PN, Paul B, Myerson SG, Neubauer S. Evaluation and Management of the Cardiac Amyloidosis. *J Am Coll Cardiol*. 2007;50:2101-10.