

Case report

Ozone therapy: adjuvant to endodontic treatment in a subluxation case – case report

Carlos Goes Nogales

Member of the Ozone Dental Group. Endodontic, Restorative Department of School of Dentistry of the University of São Paulo

Marina Beloti Ferreira

Member of the Ozone Dental Group

Francisco Ubiratan Ferreira de Campos

Member of the Ozone Dental Group. Faculty São Leopoldo Mandic

Magda Siqueira

Member of the Ozone Dental Group

Sergio Bruzadelli Macedo

Member of the Ozone Dental Group. Dentistry Department of the University of Brasilia

Keywords

subluxation,
ozone therapy,
ozone,
endodontic.

Abstract

INTRODUCTION: An injury to the tooth-supporting structures results in increased mobility, but without displacement of the tooth. Bleeding in gingival sulcus is a pathognomonic signal. The tooth is positive to a percussion test. Follow-up is required to test dental vitality. When pulp necrosis occurs, root canal treatment is indicated. Ozone therapy comes as a new possibility in root canal treatment to promote high disinfection and increase apical healing. This manuscript reports a subluxation case followed by pulp necrosis with an extended apical radiolucent image.

CASE REPORT: During conventional root canal treatment, 100 mL of 16 µg/mL ozonated water and 100 mL of 40 µg/mL ozone gas were applied into the root canal, and calcium hydroxide dressing was used. Apical radiolucent image decreased into 40 days. According to the literature and clinical data, ozone therapy has a great potential to be incorporated into endodontic therapy. Its biostimulator effects and antimicrobial potential are evident and corroborated by the literature.

CONCLUSION: According to the literature and the case report, ozone therapy is suitable to be used as an adjuvant to root canal treatment.

.
..

Suggestion on how to quote this paper:

Nogales CG et al. (2019). Ozone therapy: adjuvant to endodontic treatment in a subluxation case – case report, *Ozone Therapy Global Journal*, Vol. 9, nº 1, pp 161-169

Autor para correspondencia:: Nogales CG. Endodontic, Restorative Department of School of Dentistry of the University of São Paulo. Email: c.nogales173@gmail.com

Introduction

The subluxation framework is characterized by damage to the dental supporting structures. Therefore, fibers from the periodontal ligament and some from the neurovascular bundle tear and cause bleeding through the gingival sulcus, which is a pathognomonic sign. Usually the pain is caused by occlusion and mastication, however, there is no spontaneous pain. An increased dental mobility may occur though, nevertheless with no relation to the case prognosis. Such characteristics are added in a diagnosis that differs from the concussion^{1,2}.

In some cases, the intensity of the trauma may cause either the pulp necrosis or the calcification of the root canal system, in spite of the absence of symptoms. When pulp necrosis occurs, which can happen in 6% of cases², the root canal treatment must be indicated so the correct disinfection of the root canal system is achieved³.

Such disinfection in dental trauma cases has been obtained with an effective chemomechanical preparation besides the use of intracanal dressing with antimicrobial potential^{1,3,4}.

Nowadays, other aseptic resources of the root canal are being used, such as the ozone therapy^{5,6}. The basic principle of this method is the high oxidant potential of the ozone, which is the triatomic form of oxygen that grants an important antimicrobial action and stimulates the cellular metabolism of the healthy cells, thereby favoring tissue repair^{5,7-10}.

Ozone contact with the tissues causes a transitory oxidative stress in cells with the liberation of oxidant agents, as reactive oxygen species. Right after, these oxidative agents stimulate the releasing of antioxidants, such as catalase and superoxide dismutase, increasing the cellular metabolism^{6,10}.

Therefore, these oxidant agents, first liberated by the cells, act to stimulate the metabolism and present antimicrobial action through the denaturation of the proteins from the bacterial cell membrane¹⁰.

Considering that the insertion of ozone therapy as root canal adjuvant seems to be opportune, especially in traumatized teeth, the purpose of this manuscript was to present in a case report the ability of ozone to improve the periapical healing.

Case Report

The present chapter aims to describe the endodontic approach to an apical periodontitis came from a subluxation trauma 10 years ago

An 18-year-old female patient came with leukoderma. The orthodontist had asked for orthodontic documentation for the case planning and noticed in the exam a periapical radiolucent image in tooth 21.

Referring to the endodontic evaluation, in the anamneses the patient stated that she had a fall when she was 8 years old. The mentioned tooth presented bleeding gum, sensitivity to chewing, and mobility (suggestive of subluxation), which disappeared after some days. No dentist was consulted considering the relief of the symptoms.

In the clinical test, the absence of painful symptomatology was noticed, as well as negative tests to palpation and percussion, with no answer to sensitivity test with refrigerant gas, no color change, and no mobility or periodontal pocket.

In the initial radiographical test (Figure 1A), it was possible to notice an extensive radiolucent area in the periapical region of the tooth 21, which confirmed the indication to endodontic treatment, considering the other details from the clinical test.

At the first appointment, after the access surgery and root canal measurement, the chemomechanical procedure was performed with the association of 1% sodium hypochlorite (Fórmula e Ação™, São Paulo, Brazil) and Endo-PTC (urea peroxide, carbopol and carbowax – Fórmula e Ação™, São Paulo, Brazil) with final rinse with 10% citric acid solution, as described in a prior study⁹. After the root canal drying with vacuum cannula (Capillary Tip, Ultradent, USA) and absorbent paper tips, 100 mL of 15 µg/mL ozonated water activated by ultrasonic tip (Irrisonic, Helse Ultrassonic, Ribeirão Preto, Brazil) followed by 100 mL of 60 µg/mL ozone gas were applied. Subsequently, the root canal was filled with calcium hydroxide (Ultracal, Ultradent, USA) as intracanal dressing and provisional cement was placed. The same protocol was repeated twice.

At the third appointment, intracanal dressing was removed with 10% citric acid activated by passive ultrasonic irrigation. A new chemomechanical protocol was performed as described above, and an apical barrier was obtained through the insertion of MTA (Mineral Trioxide Aggregate, Angelus, PR, Brazil) in the apical third. Then the root canal was fulfilled with gutta-percha and AHPlus (Dentsply, Pennsylvania, USA), and sealed with bonding Z250 (3M, Sumaré, São Paulo) (Figure 1B).

The postsurgery was classified as successful in all stages, due to the total absence of signals and symptoms, including the follow-up of 3 months (Figure 1C), 9 years (Figure 1D), and 11 years (Figure 1E).

Ozone standardization

Ozone was generated *in situ* by an ozone generator (MedPlus, Philozon, Santa Catarina, Brazil) and supplied by pure oxygen (Respirox, São Paulo, Brazil). The ozone device self-calibrates to produce 1 L/min of ozone when oxygen flow is released. A glass column was connected to the ozone exit on the ozone generator to bubble ozone into the water, according to Figure 2. This bubbling was performed through a ceramic diffuser for 5 min, according to a prior study¹¹.

One liter of cold (14°C) bidistilled water was employed to be ozonated. The glass column was 50 cm high and 6 cm of diameter that received 1 L/min of oxygen/ozone flow rate. The ozone device was calibrated to produce 60 µg/mL of ozone, and the final concentration in water was 15 µg/mL, according to a prior study¹². It is important to point out that attached to the glass column was an ozone destructor to avoid any kind of intoxication. An ozone-resistant 25 mL syringe (Terumo, [Shibuya, Toquio, Japan](#)) was employed to deliver ozone gas into the root canal.

The results provided acceleration on apical periodontitis healing and bone neoformation in apical area as presented in the clinical sequence of radiographic.

Discussion

The subluxation mainly affects the dental support tissues, increasing the dental mobility. It was the most common trauma found (25.09 %) in a retrospective analysis of 287 traumatized teeth¹⁴.

Although the pulp necrosis is an uncommon fact in subluxation cases, when it occurs, it must be treated following the same principles of disinfection and cleaning used in any root canal treatment⁵.

Intracanal dressing in apical periodontitis cases is indicated and calcium hydroxide is the most used. Due to the capacity to induce mineralization, the local ionic liberation increases, precapillary sphincters of granulation tissue contract, and the local plasmatic flow is interfered with, which stimulates the calcification of the involved tissue¹⁷.

For the presented clinical case, the endodontic protocol was performed based on the association of the sodium hypochlorite 1% with Endo-PTC cream as proposed by Paiva and Antoniazzi¹³, and irrigation was done with 10 % citric acid and ozone in aqueous and gaseous forms, 15 µg/mL and 60 µg/mL, respectively. This protocol was performed in all appointments prior to intracanal dressing with calcium hydroxide and root canal filling. The aim, as it is presented by the literature, is to improve the antimicrobial effect and stimulate the repair through cellular metabolic activation^{2,10-12}.

The radiolucent image remission took place in a period of 40 days after the beginning of the root canal treatment. This fact opposes that demonstrated by the literature, where Lage-Marques and Antoniazzi⁸ related the possibility of visualization from the beginning of the radiographic repair 90 days after the traditional endodontic treatment was concluded.

The incorporation of the ozone therapy as a complementary therapy to the endodontic protocol showed improvement in the tissue repair, due to the increase of local circulation and important antimicrobial activity, as demonstrated by the literature^{2,10,12,18}. The elimination of the etiologic agent allows the wound to start the healing process.

Basic information about ozone mechanism of action shows that high ozone concentration provides antimicrobial activity and low ozone concentration provides biostimulus to the immune system^{2,12}. According to Ricucci & Siqueira Jr¹⁶, a radiographic image suitable to tooth apical bone resorption is caused by microbial infection into the root canal system. Thus, a high ozone dosage is perfectly indicated.

Scientific literature describes the best results of ozonated water when associated to ultrasonic activation^{6,9} and difficultly permeating into dentinal tubules when not activated⁹.

The association of gaseous ozone with ozonated water in a high dosage is meant to improve the antibacterial activity and to oxidize the biofilm attached to root canal walls. Thus, the ozonated water's already-proven biocompatibility¹² exerts inhibitory effects on the NF-kB system, with anti-inflammatory effects⁷ and activates Nrf2 to release antioxidants⁴.

Conclusion

Ozone therapy presents a great potential to be incorporated into endodontic therapy. Biostimulation and antimicrobial activity are evident and proven by the literature. Randomized clinical trials with a great number of subjects are necessary to the insertion of this therapeutic modality into the clinical arsenal.

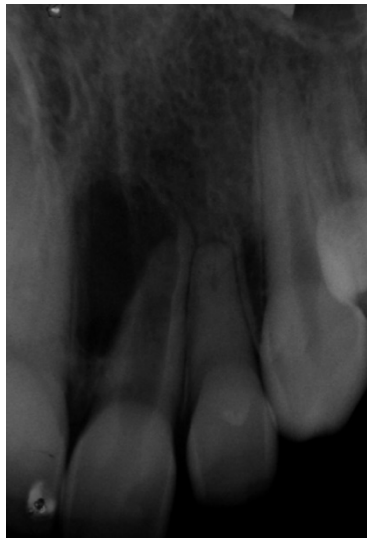
Conflicts of interest stamen

The Authors declare there is no conflict of interests in this publication.

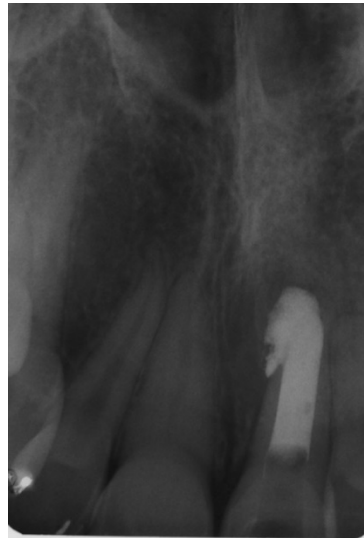BIBLIOGRAPHY

1. Andreasen JO, Andreasen FM, Skeie A, Hjrting-Hansen E, Schwartz O. Effect of treatment delay upon pulp and periodontal healing of traumatic dental injuries - a review article. *Dent Traumatol* 2002;18:116-128.
2. Bocci V. Oxygen-ozone therapy: a critical evaluation, 2002.
3. Cleen M. Obliteration of pulp canal space after concussion and subluxation: Endodontic considerations. *Quintessence Int* 2002;33:661-669
4. Galie M, Costanzo M, Nodari A, et al. Mild ozonisation activates antioxidant cell response by the Keap1/Nrf2 dependent pathway. *Free Radic Biol Med*. 2018;20(124):114-121.
5. Gulinelli JL, Hamata Saito TM, Garcia Junior IR, Panzarini SR, Poi WP, Sonoda CK, et al. Occurrence of tooth injuries in patients treated in hospital environment in the region of Araçatuba, Brazil during 6-year period. *Dent Traumatol* 2008;24:640-4.
6. Hubbezoglu I, Zan R, Tunc T, Sumer Z. Antibacterial efficacy of aqueous ozone in root canals infected by *Enterococcus faecalis*. *Jund J Microbiol*. 2014;7(7):e11411.
7. Huth KC, Saugel B, Jakob FM, et al. Effect of aqueous ozone on the NF-κB system. *J Dent Res*. 2007;86(5):451-456.
8. Lage-Marques JL, Antoniazzi JH. Versão eletrônica da técnica endodôntica da Faculdade de Odontologia da Universidade de São Paulo [CD Room]. São Paulo, 2008.
9. Nagayoshi M, Kitamura C, Fukuizumi T, et al. Antimicrobial effect of ozonated water on bacteria invading dentinal tubules. *J Endod*. (2004);30(11):778-81.
10. Nogales CG, Ferrari PH, Kantorovich EO, Lage-Marques JL. Ozonotherapy in medicine and dentistry. *J Contemp Dent Pract* 2008 May; (9)4:075-084.
11. Nogales CG, Ferreira MB, Lage-Marques JL, Antoniazzi JH. Comparison of the antimicrobial activity of three different concentrations of aqueous ozone on *Pseudomonas aeruginosa*, *Staphylococcus aureus* and *Enterococcus faecalis* – in vitro study. *Rev.Esp.Ozon*. 2014;4(1):9-15.
12. Nogales CG, Ferreira MB, Montemor AF, Rodrigues MF, Lage-Marques JL, Antoniazzi, JH. Ozone therapy as an adjuvant for endodontic protocols: microbiological – ex vivo study and cytotoxicity analyses. *J Appl Oral Sci*. 2016;24:607-13.
13. Paiva JG, Antoniazzi JH. [O uso de uma associação de peróxido de uréia e detergente (Tween 80) no preparo químico-mecânico dos canais radiculares]. *Rev Assoc Paul Cir Dent*. 1973;27(7):416-23.[Portuguese].
14. Panzarini SR, Pedrini D, Poi WR, Sonoda CK, Brandini DA, Castro JCM. Dental trauma involving root fracture and periodontal ligament injury: a 10-year retrospective study. *Braz Oral Res* 2008,22(3):229-34.
15. Pinheiro SL, da Silva CC, da Silva LA, Cicotti MP, Bueno CE, Fontana CE, et al. Antimicrobial efficacy of 2.5% sodium hypochlorite, 2% chlorhexidine, and ozonated water as irrigants in mesiobuccal root canals with severe curvature of mandibular molars. *Eur J Dent*. 2018;12:94-9.
16. Ricucci D, Siqueira Jr, JF. Biofilms and apical periodontitis: study of prevalence and association with clinical and histopathologic findings. *J Endod*.2010;36(8):1277-88.
17. Sathorn C, Parashos P, Messer H. Antibacterial efficacy of calcium hydroxide intracanal dressing: a systematic review and meta-analysis. *Int Endod J*. 2007 Jan;40(1):2-10.
18. Viebahn-Haensler R. The use of ozone in medicine. 4th ed, 2002.

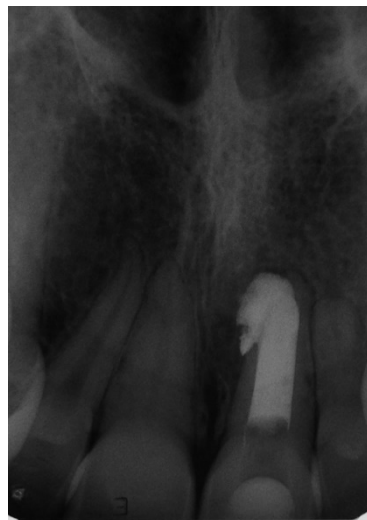Figures Legends



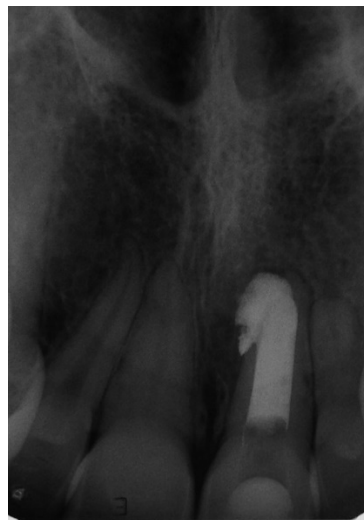(A) Initial radiography



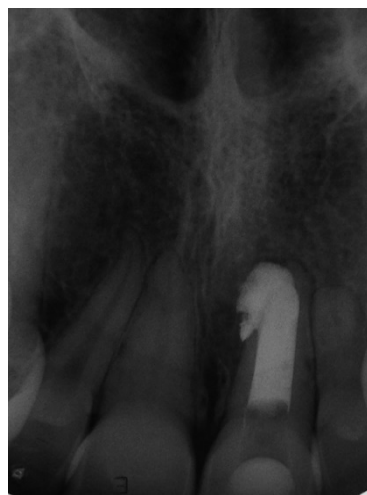(B) Final radiography



(C) 3 months follow-up



(D) 9 years follow-up



(E) 11 years follow-up

Figure 1. Clinical radiographical sequence. (A) Initial radiography; (B) Final radiography; (C) 3 months follow up; (D) 9 years follow up; (E) 11 years follow up