

Heart disease associated to eosinophilia

Hypereosinophilic Syndrome (HES) is a rare, underdiagnosed syndrome with an estimated male-to-female ratio of 4-9:1¹ defined as persistent and marked blood eosinophilia ($> 1.5 \times 10^9/L$ for more than six consecutive months). This condition is characterized by persistent eosinophilia for a period longer than 6 months associated with end-organ involvement and without a primary cause for eosinophilia².

Heart Disease associated to eosinophilia can be seen in several conditions, such as Löffler's Endocarditis, Polyangiitis with granulomatosis, HES, parasitic or haematological malignancies. Cardiac involvement in HES occurs in three phases: acute necrosis, thrombosis and finally fibrosis.²

A 43-years-old female patient presented to the Emergency Department with a one-week history of shortness of breath, asthenia and precordial pain. Examination revealed crackles on pulmonary auscultation. Blood analysis showed leucocytosis with eosinophilia 27000/ μL , C-Reactive Protein (CRP) 5mg/dL, troponin I 1.71ng/L, Erythrocyte Sedimentation rate (ESR) of 71mm/h. Electrocardiography (Figure 1) showed negative T waves in precordial leads and transthoracic echocardiography was consistent with left ventricle septal hypertrophy with diastolic dysfunction and minimal pleural effusion. Immunology laboratory studies including Anti-Neutrophil Cytoplasmic Antibodies (ANCA) and Anti-Nuclear Antibodies (ANA) were negative, and complement C3 and C4 were normal; there was no history of undercooked pig meat, stool evaluation for parasites was negative, serology by Enzyme-linked Immunosorbent Assay (ELISA) for *Strongyloides stercoralis* and *Taenia solium* were negative; Brain, Thoracic, Abdominal and pelvic CT scan showed no lesions attributable neither to parasitosis including Cysticercosis nor neoplasm; Peripheral Blood Lymphocyte populations were normal and myelogram demonstrated eosinophilia in several degrees of maturation, hypogranular and with large vacuoles. Cardiac Magnetic Resonance showed evidence of endomyocardial oedema and fibrosis of the medial and apical segments of the anterior and inferior septal walls (figures 2-4), and evidence of pericardial inflammation (figure 5). These findings were consistent with HES with Eosinophilic myocarditis and pericarditis.

The patient was treated with high dose methylprednisolone for 5 days followed by tapering dose of prednisolone. After 5 days of methylprednisolone, Eosinophilia had resolved (120/ μL), ESR normalised (11mm/H) and the patient's symptoms alleviated. After 10 days of

Figure 1. ECG at admission

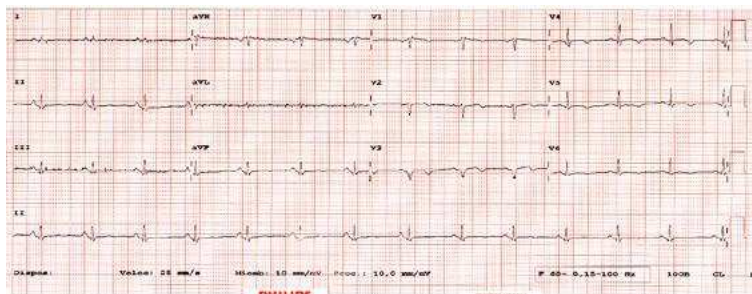


Figure 2. T2 Black Blood ponderation showing septal edema

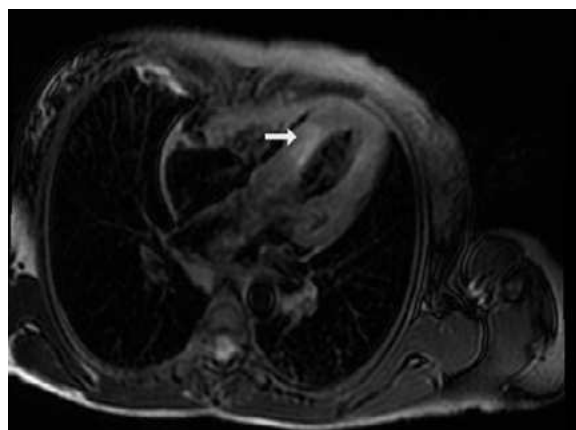
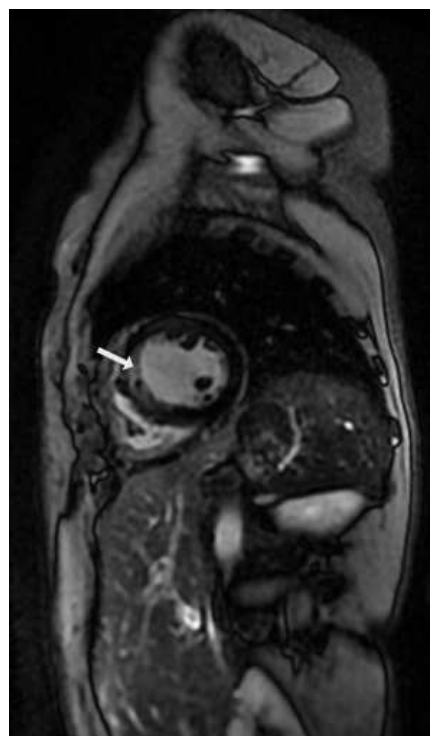


Figure 3. Early Gadolinium Enhancement MRI showing septal wall edema



prednisolone therapy, the patient maintained clinical and laboratory response and was discharged from hospital under prednisolone 10mg/day. Six months after hospital discharge, an attempt to taper corticoid therapy (to 5mg/qd) was met with a rise in peripheral blood eosinophils to 3540/ μ L, thus frustrating this attempt. After one year of follow-up the patient remains asymptomatic, without eosinophilia, under prednisolone 10mg qd.

REFERENCES

1. Roufosse FE, Goldman M, Cogan E. Hypereosinophilic syndromes. *Orphanet J Rare Dis* [Internet]. 2007;2(1):37. Available from: <http://ojrd.biomedcentral.com/articles/10.1186/1750-1172-2-37>
2. Ogbogu PU, Rosing DR, Horne MK. Cardiovascular Manifestations of Hypereosinophilic Syndromes. *Immunology and Allergy Clinics of North America*. 2007.

DIAGNOSIS

Eosinophilic myocarditis in idiopathic hypereosinophilic syndrome

Rui Assis, Andreia Brito

Centro Hospitalar do Médio Tejo. Portugal

Correspondencia: ruiandre.assis@gmail.com

Cómo citar este artículo: Rui A, Brito A

Heart disease associated to eosinophilia. *Galicía Clin* 2020; 81 (1): 26

Recibido: 16/12/2018; Aceptado: 04/03/2019 // <http://doi.org/10.22546/55/1855>

Figure 4. Late Gadolinium Enhancement MRI showing septal Wall fibrosis

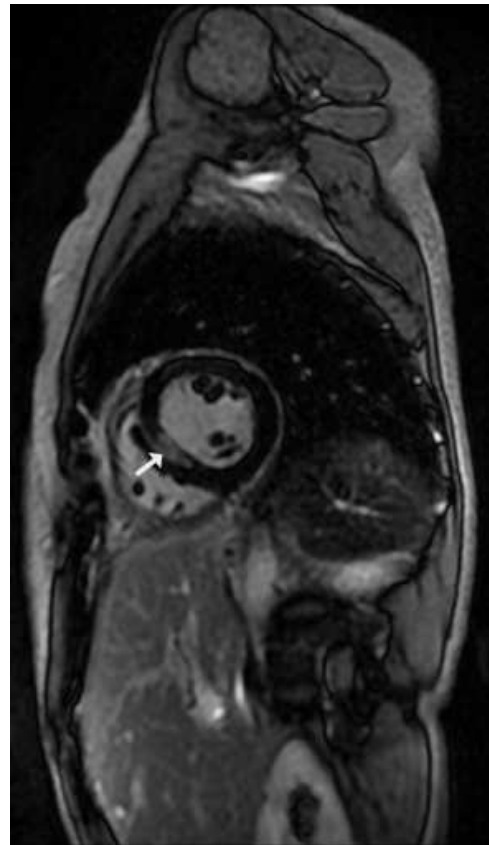


Figure 5. Late Gadolinium Enhancement MRI showing pericardial inflammation

