

Pelvic extra-peritoneal cyst

Echinococcosis is a zoonotic infection caused by *Echinococcus granulosus*, from the family of *taeniidae* of the *cestoda* class and is endemic in South America, Eastern Europe, Russia, Middle East and China¹. In humans, Cystic Echinococcosis involves usually the liver and lungs. Treatment involves medical therapy and surgical removal in any combination, dictated by the stage of disease according to the World Health Organization (WHO) classification¹.

A 75 year-old female patient presented to the Emergency department with a two week history of nausea and upper abdominal discomfort. Physical examination suggested hepatomegaly but laboratory screening was unremarkable. Abdominal Ultrasound was compatible with Cystic Echinococcosis of the Liver. Requested Indirect Hemagglutination for *Echinococcus granulosus* was positive with a tittle of 1/1280. Abdominal CT scan (Fig 1 and Fig 2) and Magnetic Resonance Imaging (Fig. 3 and Fig. 4) showed hydatidosis of the Liver and a Pelvic extra-peritoneal cyst with daughter cysts, consistent with active disease (WHO stage C3b of disease). The patient started medical therapy with Albendazol 400mg bid. Burden of disease was considered significant, with risk of cyst rupture. In this context, medical therapy was admitted as the initial strategy to lessen the cyst size and surgical therapy was deferred.

REFERENCES

1. Bhutani N, Kajal P, Hepatic Echinococcosis. A review, *Annals of Medicine and Surgery* 36 (2018) 99-105.

DIAGNOSIS

Extra-visceral Cystic Echinococcosis

Rui Assis, Andreia Brito

Centro Hospitalar do Médio Tejo, Portugal

Correspondencia: ruiandre.assis@gmail.com

Cómo citar este artículo: Rui A, Brito A
Pelvic extra-peritoneal cyst. *Gaceta Clínica* 2020; 81 (1): 24

Recibido: 04/12/2018; Aceptado: 04/02/2019 // <http://doi.org/10.22546/55/1844>

Figure 1. Hepatic hydatidosis with daughter Cysts on Abdominal CT Scan

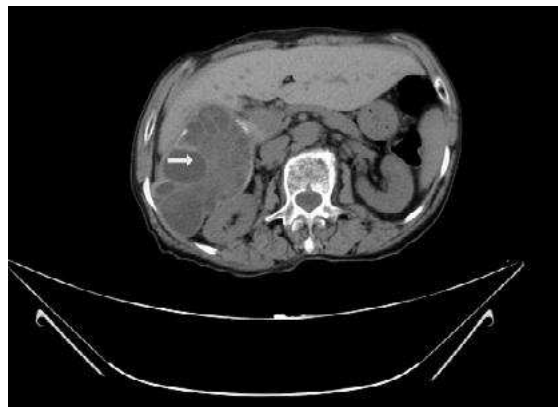

Figure 2. Pelvic cyst implantation on Pelvic CT scan

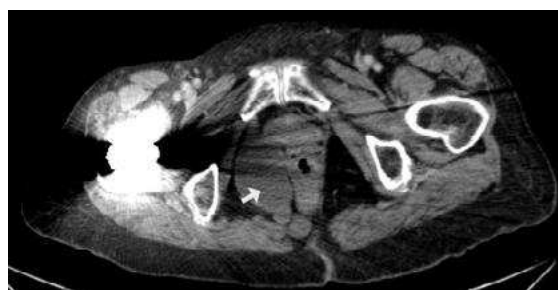

Figure 3. T2 ponderation of abdominal Magnetic Resonance Imaging showing daughter cysts in the liver

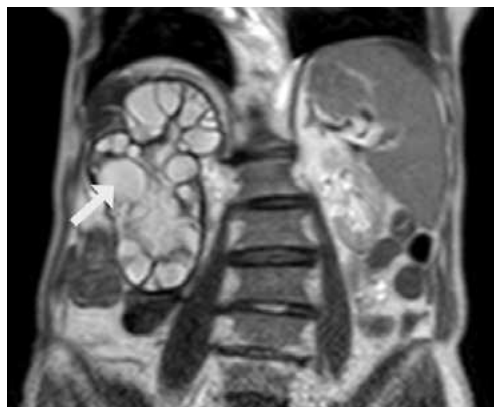


Figure 4. T2 ponderation of Pelvic Magnetic Resonance Imaging showing Pelvic implant with daughter cysts

