

A rare cause of liver abscess in a Western Country

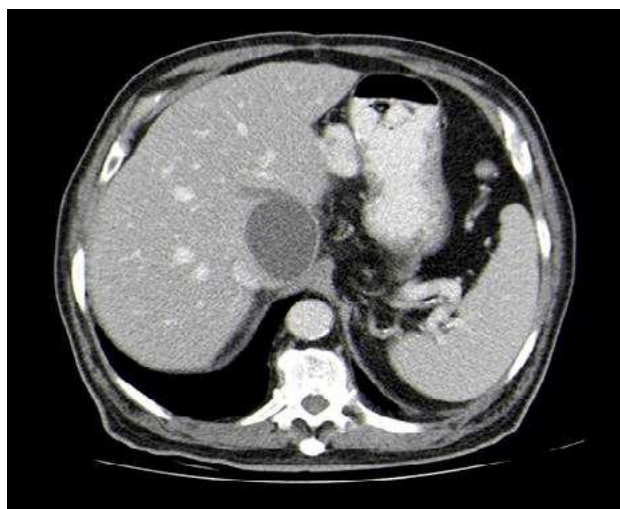
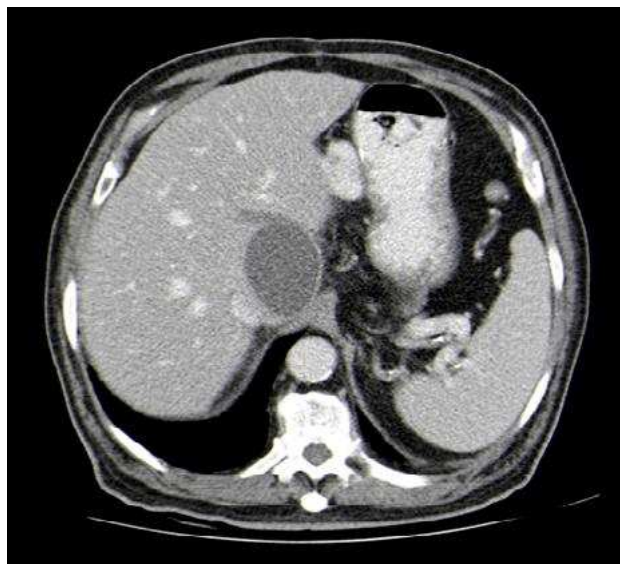
Klebsiella pneumoniae is a common cause of pyogenic liver abscess in patients with diabetes mellitus, pre-existing hepatobiliary disease and those from Southeast Asia¹, where it accounts for 50% to 73% of cases². But, in the last decades, there has been an increasing number of reports in Western countries³.

A 61-year-old portuguese male, without significant past medical history, was admitted with right upper quadrant abdominal pain and fever. He denied any recent foreign travel. Laboratory analysis showed 6900 leucocytes, C-reactive protein 287.5 mg/L, total bilirubin 1.1 mg/dL, AST 116 UI/L, ALT 88 UI/L, alkaline phosphatase 180 UI/L. Abdominal Computed Tomography (CT) scan revealed a 3.4x3.3cm complex mass in the IV hepatic segment with multiple septations. Blood cultures grew *Klebsiella pneumoniae* and, according to the antibiogram, he was placed on ceftriaxone for 21 days. The abscess was drained by interventional radiology and gram stain and cultures of pus were positive for *Klebsiella pneumoniae*. His clinical condition improved and a follow-up CT, after antibiotic therapy, showed complete resolution of liver abscess.

References

1. Lederman ER, Crum NF. Pyogenic liver abscess with a focus on *Klebsiella pneumoniae* as a primary pathogen: an emerging disease with unique clinical characteristics. *AM J Gastroenterol.* 2005 Feb;100(2):322-31.
2. Mavilla MG, Molina M, Wu GY. The evolving nature of hepatic abscess: A review. *Journal of Clinical and Translational Hepatology* 2016;4:158-168
3. Rahimian J, Wilson T, Oram V, Holzman RS. Pyogenic liver abscess: recent trends in etiology and mortality. *Clin Infect Dis* 2004, 39: 1654-1659.

Fig. 1. Abdominal Computed Tomography with voluminous mass compatible with hepatic abscess



Diagnosis

Pyogenic liver abscess caused by *Klebsiella pneumoniae*

Liliana Torres. Diana Pereira Anjos

Centro Hospitalar do Tâmega e Sousa. Portugal

Correspondencia: lilianatorres@hotmail.com

Cómo citar este artículo: Torres L, Pereira Anjos D

A rare cause of liver abscess in a Western Country. *Galic Clin* 2019; 80 (3): 64

Recibido: 22/08/2018; Aceptado: 30/09/2018 // <http://doi.org/10.22546/53/1749>