

## Evidence of persistent Müllerian duct syndrome in a Yorkshire terrier<sup>✉</sup>

*Evidencias de síndrome de persistencia del conducto Mülleriano en un Yorkshire terrier*

*Evidências de síndrome do ducto Mülleriano persistente em um Yorkshire terrier*

Priscila Silva<sup>1</sup>

Ricardo A R Uscategui<sup>1</sup>

Igor R H Gatto<sup>2</sup>

Marina B S De Brito<sup>1</sup>

Ana Paula R Simões<sup>2</sup>

VivianT Almeida<sup>1</sup>

Marcus A R Feliciano<sup>1,3\*</sup>

Wilter R R Vicente<sup>1</sup>

\*Corresponding author: Marcus Antonio Rossi Feliciano. School of Agricultural and Veterinarian Sciences, Department of clinical and veterinary surgery, São Paulo State University (Unesp), Via de acesso Prof. Paulo Donato Castellane, s/n, 14884-900, Jaboticabal, São Paulo, Brazil. Tel.: +55 16 3209 7100. Email: marcusfeliciano@yahoo.com.br.

<sup>1</sup>*School of Agricultural and Veterinarian Sciences, Department of clinical and veterinary surgery, São Paulo State University (Unesp), Jaboticabal, São Paulo, Brasil.*

<sup>2</sup>*School of Agricultural and Veterinarian Sciences, Department of preventive veterinary medicine and animal reproduction, São Paulo State University (Unesp), Jaboticabal, São Paulo, Brazil.*

<sup>3</sup>*Federal University of Recôncavo da Bahia, Bahia, Brazil.*

*(Received: November 24, 2017; accepted: February 7, 2018)*

✉ To cite this article: Silva P, Uscategui RAR, Gatto IRH, De Brito MBS, Simões APR, Almeida VT, Feliciano MAR, Vicente WRR. Evidence of persistent Müllerian duct syndrome in a Yorkshire terrier. Rev Colomb Cienc Pecu 2018; 31(4):315-319.

## **Abstract**

**Anamnesis:** A one-year-old female Yorkshire terrier, weighing 2.2 kg, was referred for evaluation of an abnormal structure in the inguinal region.

**Clinical and laboratory findings:** Upon examination, the structure -similar to a penis- was found protruding from the preputial orifice. Physical, laboratory, ultrasound, and radiographic examinations were performed. The initial suspicion was a case of sexual development disorder, so the dog was referred for exploratory laparotomy and karyotyping.

**Treatment approach:** During the surgical procedure, two macroscopically similar structures were found at the caudal pole of the left and right kidneys. These tissues were attached to two structures similar to the uterine horns, caudally fused to a body in the pelvic cavity. All the tissue was removed and submitted for histopathological examination, revealing the presence of typical seminiferous tubules (testis) and proliferative endometrial glands (uterine tubes). Subsequently, a surgical correction procedure was performed to cover the penile tissue and avoid damage by exposure and contact.

**Conclusion:** This case reports unique information on diagnosis and therapeutic approach in a Yorkshire terrier with persistent Müllerian duct syndrome (PMDS). Because they are unusual, sexual development disorders are challenging in terms of diagnostic and therapy, making this report a valuable tool for veterinarians.

**Keywords:** *dog, genetics, intersex, karyotype, reproductive disease.*

## **Resumen**

**Anamnesis:** Una hembra Yorkshire terrier de un año de edad y 2,2 kg de peso fue remitida para evaluación de una estructura anormal en la región inguinal.

**Hallazgos clínicos y de laboratorio:** Tras el examen, se encontró una estructura similar a un pene sobresaliendo del orificio prepucial. Se realizó examen clínico, paraclínico, ecografía y radiografía abdominal. El diagnóstico presuntivo inicial fue trastorno del desarrollo sexual, por lo que la perra fue remitida para laparotomía exploratoria y cariotipaje.

**Abordaje terapéutico:** Durante el procedimiento quirúrgico se encontraron dos estructuras macroscópicas similares en la región caudal de ambos riñones. Estos tejidos se unían a dos estructuras similares a los cuernos uterinos, caudalmente fusionados a un cuerpo en la cavidad pélvica. Se retiró todo el tejido y se envió para examen histopatológico, revelando la presencia de túbulos seminíferos típicos (testículos) y glándulas endometriales proliferativas (tubos

uterinos). Posteriormente se realizó un procedimiento quirúrgico de corrección para cubrir el tejido peniano y evitar daños por exposición y contacto.

**Conclusión:** Este informe aporta información única sobre el diagnóstico y el enfoque terapéutico en un Yorkshire terrier con síndrome de persistencia del conducto Mülleriano (PMDS). Dado que los trastornos del desarrollo sexual son inusuales y plantean un desafío diagnóstico y terapéutico, este reporte puede representar una valiosa herramienta para los veterinarios.

**Palabras clave:** *cariotipo, enfermedad reproductiva, genética, intersexo, perro.*

## **Resumo**

**Anamnesis:** Uma fêmea Yorkshire terrier de 1 ano de idade, com 2,2 kg de peso e uma estrutura anormal na região inguinal, similar ao orifício prepucial.

**Achados clínicos e laboratoriais:** Após o exame, uma estrutura semelhante a um pênis foi encontrada saindo do orifício prepucial. Foram realizados exames físicos, laboratoriais, ecográficos e radiográficos. A suspeita inicial seria um caso de desordem do desenvolvimento sexual, pelo que a cadela foi encaminhada para laparotomia exploratória e cariotipagem.

**Abordagem terapêutica:** Durante o procedimento cirúrgico macroscopicamente duas estruturas semelhantes foram encontradas: uma na região caudal do rim direito e outro na região caudal do rim esquerdo. Estes tecidos encontravam-se ligados a duas estruturas semelhantes aos cornos uterinos, caudalmente fusionados a um corpo na cavidade pélvica. Todo o tecido foi removido e enviado para exame histopatológico e revelou a presença de túbulos seminíferos típicos (testículos) e glândulas endometriais proliferativas (tubas uterinas). Subsequentemente, foi realizado procedimento cirúrgico de correção para cobrir o tecido peniano e evitar danos por exposição e contato.

**Conclusão:** Este relatório aporta informações únicas sobre diagnóstico e abordagem terapêutica em um Yorkshire terrier com síndrome de persistência do ducto de Müller (PMDS). Distúrbios do desenvolvimento sexual são anomalias incomuns que representam um desafio diagnóstico e terapêutico considerando este relato uma ferramenta valiosa para os veterinários.

**Palavras-chave:** *cão, cariotipo, doença reprodutiva, genética, intersex.*

## **Introduction**

Disorders of sexual development (DSD) are classified according to the stage of embryonic or fetal sex differentiation and are designated as chromosomal, gonadal, or phenotypic (Poth *et al.*, 2010; Meyers-Wallen, 2012). During genitalia development, changes in the production or function of Müllerian inhibitory substance (MIS), testosterone, insuline-like 3 (INSL3), Specific MIS type II receptor (MISRII), or iatrogenic masculinization in pregnant females may result in phenotypic DSD. In these individuals, chromosomal sex and gonadal sex are correct, but the external or internal genitalia do not correspond to them (Meyers-Wallen, 2009).

Pseudohermaphroditism is a rare anomaly. It occurs when chromosomal and gonadal sexes are equivalent, but there is a mismatch or ambiguity in the phenotype. Male or female pseudohermaphrodite are linked according to gonadal sex. Two types of male pseudohermaphroditism have been described, each one with distinct etiologies: impaired androgen- dependent masculinization and persistent Müllerian duct syndrome (PMDS) (Cristensen, 2012). The PMDS is considered a hereditary disease inherited as an autosomal recessive trait in miniature Schnauzer and Basset hound, also reported in other breeds (Poth *et al.*, 2010; Breshears and Peters, 2011). PMDS can be triggered by faults in production or function of the Müllerian inhibitory substance or by specific receptors of the same (MISRII) in the Müllerian ducts (Meyers-Wallen, 2009). Affected individuals have male chromosomes (78, XY) and present uterine tubes, a uterine body, cervix and cranial vagina, as well as internal and external male organs (Meyers- Wallen *et al.*, 1989).

Diagnosis of sexual development disorders in dogs has great clinical and epidemiological importance; however, few reports hinder the epidemiological, pathophysiological, and genetic study of these abnormalities, challenging the diagnostics, therapeutics, and prevention for clinical and obstetric routine. Therefore, this report describes the diagnostic findings and treatment performed on a Yorkshire terrier presenting persistent Müllerian duct syndrome.

### ***Patient examination***

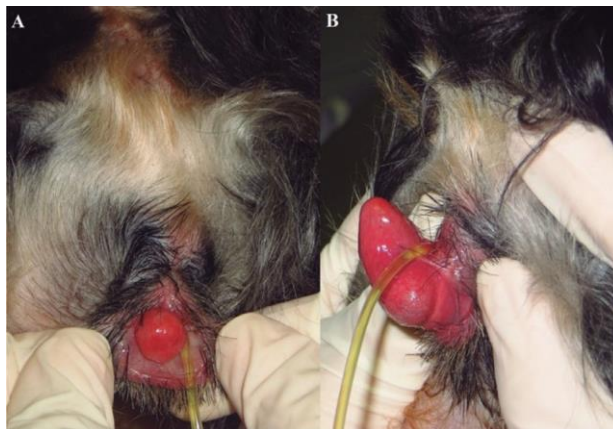
#### ***Anamnesis.***

A one-year-old female Yorkshire terrier, weighing 2.2 kg, with an abnormal structure in the inguinal region was presented for clinical evaluation at the Hospital Veterinário “Governador Laudo Natel”, Unesp-Jaboticabal, SP, Brazil. The owner denied similar changes in parents or

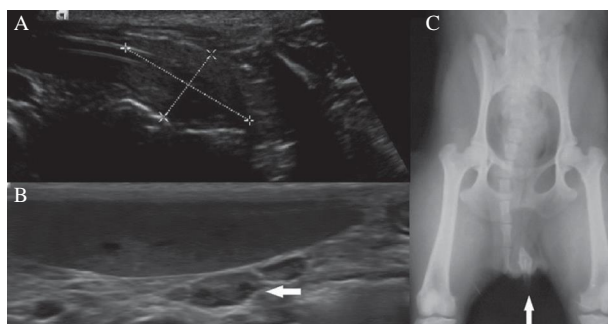
siblings.

### *Clinical and laboratorial findings.*

At physical examination of the inguinal region, a preputial orifice with a small structure similar to a penis was observed protruding from the canal in flow direction (Figure 1A). It presented an external urethral orifice immediately at the transition between the base and the pseudopenis (Figure 1B). The protrusion was not identified as other external genital structure. At abdominal ultrasound examination, caudally to the urinary bladder, an echogenic, elongated and bilobed structure involving the pelvic urethra was observed, suggesting the presence of prostatic tissue (Figure 2A). In the right retroperitoneal region there was an isoechogenic rounded-up structure in relation to splenic tissue, with architecture similar to the testis (Figure 2B); however, there were not any recognizable reproductive structures in the left region. Complementarily, radiographic examination of the perineal area showed a mineral-dense structure (radiopaque) corresponding to the rudimentary penis bone (Figure 2C).



**Figure 1.** Image of perineal region of a Yorkshire terrier dog with persistent Müllerian duct syndrome, showing A) preputial orifice in the inguinal region with a small structure resembling a penis protruding ventrally from the canal, and B) detail of the pseudo-penile structure and external urethral orifice.



**Figure 2.** Female Yorkshire terrier with persistent Müllerian duct syndrome: Sonographic images showing: A) an elongated echogenic structure traversed by a pelvic urethra (caliper 1.9 X 1.1 cm) caudally to the urinary bladder,

indicating prostate tissue; B) isoechogenic rounded structure in relation to the splenic tissue, with similar architecture to the testicle in the left hypogastrium; and C) Radiographic image in ventrodorsal projection indicating the presence of a penis (arrow).

### *Karyotyping analysis.*

Additionally, cytogenetic analysis of 100 metaphase cell preparations obtained from a patient's leukocyte culture was conducted, and the chromosomes were observed in Giemsa-stained preparations. The karyotype of this patient consisted of 38 pairs of autosomal acrocentric chromosomes, one metacentric X chromosome and one submetacentric Y chromosome (78, XY), considered normal for a male of the species *Canis familiaris*. Chimerism and mosaics were discarded, considering the number of metaphases analysed. The phenotypic changes, karyotype (78, XY), bilateral testis, uterine horns and uterine body correlate with abnormalities of sexual differentiation, consistent with PMDS.

### *Treatment approach.*

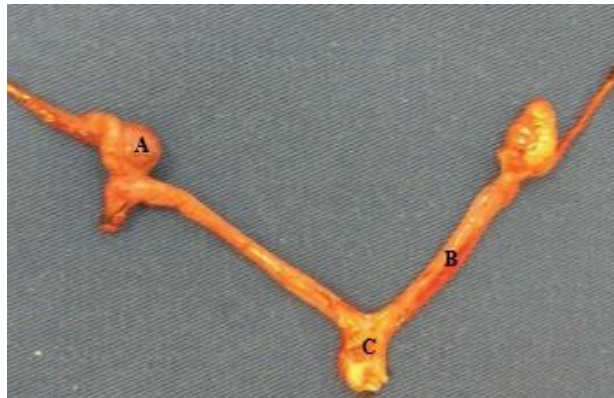After analysis of the findings, the initial suggested diagnosis was a sexual development disorder, such as pseudohermaphroditism. Then, an exploratory laparotomy was conducted to confirm and complete resection of the internal genital structures. Two structures macroscopically similar to the testicles were observed: one in the caudal region of the right kidney and the other in the left kidney. These tissues were connected to two structures similar to the uterine horns, caudally fused into one body and cervix that entered in the pelvic cavity. All tissue was removed and submitted for histopathologic examination.

Corrective surgery was then performed to cover the penile tissue and avoid damage by exposure and contact. The urethral orifice was carefully positioned in the region free of the opening. To ensure proper healing, the urethra remained probed for five days. Satisfactory recovery was observed during the postoperative clinical examination, and one year later the animal appears healthy, with no further history of clinical genitourinary complications.

Histology revealed the presence of typical seminiferous tubules, interspersed in Leydig cells infiltrate and light peritubular fibrosis, increased genital tubules with atrophic mucosa and the muscle layer, typically defined as testicular parenchyma and structures compatible with uterine tubes (Figure 3) characterized by proliferative endometrial glands. No ovarian tissue was found.

## Discussion

As previously described, PMDS is a disorder of the phenotypic sexual development that rarely affects other breeds besides the miniature Schnauzer and Basset hound (Poth *et al.*, 2010). Regarding the Yorkshire terrier, to our knowledge, this anomaly is rare; other researchers described a two-year-old animal with clinical, chromosomal, and internal genital characteristics similar to the present case; however, the external phenotype was intermediate between male and female; histologically, testicles had hyperplasia of Leydig and seminoma cells, and the animal showed male behaviours such as territorial marking and breeding inanimate objects (Hagel *et al.*, 2010).



**Figure 3.** Female Yorkshire terrier with persistent Müllerian duct syndrome: A) testis and epididymis structure, B) uterine horn, and C) uterine body.

Differences regarding behaviour are related to the age of the patient. After puberty, testes and genitalia increment their function and concomitant diseases, such as Sertoli cell tumor, hydrometra, cystic endometrial hyperplasia, pyometra, cystitis, and epididymal malformations commonly develop (Marshall *et al.*, 1982; Whyte *et al.*, 2009; Vegter *et al.*, 2010).

The specific diagnosis of this syndrome was based on a dog with karyotype 78, XY and the presence of both testicles and internal female genital organs verified by histopathology (Meyers-Wallen, 2009). Previous reports determined that these patients were SRY-positive (Hagel *et al.*, 2010). However, this test was not performed when addressing this case as both gonads corresponded to normal testicles, and this demonstrates the expression and function of the gene. For diagnosing a specific genetic etiology, molecular and proteomic tests would be needed to assess mutation of the MSIRII receptor as well as MIS expression and function (Meyers-Wallen, 2009). Nevertheless, in a clinical context, the diagnostic approach performed in this case allowed the DSD determination and male 78, XY phenotypic

classification coincident with PMDS features.

The recommended treatment for this abnormality is gonadectomy and internal genitalia excision to avoid or correct common complications described above (Meyers-Wallen, 2009). Regarding external genitalia, the treatment should be instituted according to the needs of each patient and determined in agreement with the owner. Penectomy or clitoridectomy associated with ureterostomy are commonly imposed in these malformations, but this approach was considered an invasive, risky, and dispensable technique in our patient since the pseudo-penis structure did not compromise any organic function that could pose a health risk (Borrow *et al.*, 2011; MacPhail, 2013). Therefore, corrective surgery was conducted to cover, protect, and prevent dryness, ulceration or infection of the penile structure, as indicated for treating paraphimosis (Pavletic and O’Bell, 2007; Fossum, 2008).

## **Conclusion**

Sexual development disorders represent a diagnostic and therapeutic challenge in small animal practice. The PMDS is an unusual anomaly, especially in Yorkshire terrier breeds. This report, which presents a diagnostic and therapeutic approach to PMDS, can be a valuable tool for clinical, epidemiological, and scientific studies on small animal practice, reproduction, and genetics.

## **References**

- Borrow RD, Gregory SP, Giejda AA, White RN. Penile amputation and scrotal urethrostomy in 18 dogs. *Vet Rec* 2011; 169:657-665.
- Breshears MA, Peters JL. Ambiguous Genitalia in a Fertile, Unilaterally Cryptorchid Male Miniature Schnauzer Dog. *Vet Pathol* 2011; 48:1038-1040.
- Christensen BW. Disorders of sexual development in dogs and cats. *Vet Clin North Am Small Anim Pract* 2012; 42:515-526.
- Fossum TW. Surgery of reproductive and genital systems. In: Fossum TW, editor. *Small animal surgery*. 3 ed. Elsevier, Saint Louis. 2008: 702-740.
- Hagel T, Baade S, Kirchhoff A , Kuiper H, Perk A. Persistent Mullerian duct syndrome in a Yorkshire terrier. *Kleintierpraxis* 2010; 55:547.



MacPhail CM. Surgery of the bladder and urethra. In: Fossum TW, editor. Small animal surgery. 4 ed. Elsevier, Saint Louis. 2013: 735-779.

Marshall LS, Oehlert ML, Haskins ME, Selder JR, Patterson DF. Persistent Müllerian duct syndrome in miniature schnauzers. J Am Vet Med Assoc 1982; 181:798-801.

Matsuu A, Hashizume T, Kanda T, Nagano M, Sugiyama A, Okamoto Y, Hikasa Y. A case of persistent Müllerian duct syndrome with sertoli cell tumor and hydrometra in a dog. J Vet Med Sci 200; 71:379-381.

Meyers-Wallen VN, Donahoe PK, Ueno S, Manganaro TF, Patterson DF. Müllerian inhibiting substance is present in testes of dogs with persistent müllerian duct syndrome. Biol Reprod 1989; 41:881-888.

Meyers-Wallen VN. Gonadal and sex differentiation abnormalities of dogs and cats. Sex Dev 2012; 6:46-60.

Meyers-Wallen VN. Review and update: genomic and molecular advances in sex determination and differentiation in small animals. Reprod Domest Anim 2009; 44:40-46.

Pavletic MM, O'Bell SA. Subtotal penile amputation and preputial urethrostomy in a dog. J Am Vet Med Assoc 2007; 230:375-377.

Poth T, Breue W, Walter B, Hecht W, Hermanns W, Disorders of sex development in the dog- Adoption of a new nomenclature and reclassification of reported cases. Anim Reprod Sci 2010; 121:197-207.

Vegter AR, Kooistra HS, Van Sluijs FJ, Van Bruggen LWL, Ijzer J, Zijlstra C, Okkens AC. Persistent Mullerian Duct Syndrome in a Miniature Schnauzer Dog with Signs of Feminization and a Sertoli Cell Tumour. Reprod Domest Anim 2010; 45:447-452.

Whyte U, Monteagudo LV, Diaz-Otero A, Lebrero ME, Tejedor MT, Falceto MV, Whyte J, Gallego M. Malformations of the epididymis, incomplete regression of the mesonephric tubules and hyperplasia of Leydig cells in canine persistence of Müllerian duct syndrome. Anim Reprod Sci 2009; 115:328-333.