






## Caso clínico

# Diagnóstico y tratamiento conservador de quiste dentígero: seguimiento a 3 años

*Diagnóstico e tratamento conservador em cisto dentígero: acompanhamento de 3 anos*

*Diagnosis and conservative treatment of dentigerous cyst: 3-year follow-up*

Natália Bertolo-Domingues<sup>1</sup> , Diego Giroto-Bussaneli<sup>2</sup> , Fabiano Jeremias<sup>3</sup> ,  
Elisa Maria Aparecida-Giro<sup>4</sup> , Cyneu Aguiar-Pansani<sup>5</sup> 

1. DDs, MSc, PhD Student, Department of Pediatric Dentistry and Orthodontics, Sao Paulo State University (Unesp), School of Dentistry, Araraquara, SP, Brazil. Address: Rua Humaitá, 1680 Araraquara/SP, Brazil -14801-903.

2. DDs, MSc, PhD, Department of Pediatric Dentistry and Orthodontics, Sao Paulo State University (Unesp), School of Dentistry, Araraquara, SP, Brazil.

3. DDs, MSc, PhD, Professor of Post-Graduate program in Dental Science, Department of Pediatric Dentistry and Orthodontics, Sao Paulo State University (Unesp), School of Dentistry, Araraquara, SP, Brazil.

4. DDs, PhD, Associate Professor, Department of Pediatric Dentistry and Orthodontics, Sao Paulo State University (Unesp), School of Dentistry, Araraquara, SP, Brazil.

5. DDs, PhD, Assistant Professor, Department of Pediatric Dentistry and Orthodontics, Sao Paulo State University (Unesp), School of Dentistry, Araraquara, SP, Brazil.

**Fecha correspondencia:**

Recibido: enero de 2017.

Aceptado: junio de 2018.

**Forma de citar:**

Bertolo-Domingues N, Giroto-Bussaneli D, Jeremias F, Aparecida-Giro EM, Aguiar-Pansani C. Diagnóstico y tratamiento conservador de quiste dentígero: seguimiento a 3 años. Rev. CES Odont 2018; 31(1): 57-65.

## Open access

© Derecho de autor

Licencia creative commons

Ética de publicaciones

Revisión por pares

Gestión por Open Journal System

DOI: [http://dx.doi.org/10.21615/](http://dx.doi.org/10.21615/cesodon.31.1.6)

cesodon.31.1.6

ISSN 0120-971X

e-ISSN 2215-9185

**Resumen**

El quiste dentígero es el quiste de desarrollo odontogénico más común. Aunque puede afectar cualquier diente incluido, los molares y caninos son los más afectados, seguidos por los premolares e incisivos. Este trabajo tiene como objetivo relatar el caso de una paciente de 11 años de edad quien refería ausencia del segundo premolar inferior derecho (45) en el arco dental. De esa manera, se hizo una revisión de literatura abordando el diagnóstico y tratamiento de esta condición. Luego del examen clínico y radiográfico se pudo observar una imagen compatible con un quiste dentígero, cuyo diagnóstico fue confirmado por el examen histopatológico y tomografía computarizada de haz cónico (cone beam). Fue realizado un procedimiento quirúrgico conservador de descompresión utilizando el resultado de la tomografía como guía quirúrgica. Después de 4 meses de seguimiento clínico y radiográfico, se realizó la enucleación de la lesión por curetaje. Se hizo seguimiento de la paciente durante 3 años hasta la erupción completa del diente 45 y su alineación en el arco. No se observaron lesiones y el tratamiento ortodóntico fue eficaz. La técnica de descompresión quirúrgica fue segura, evitó daños de otras estructuras importantes y proporcionó una rápida recuperación de la paciente.

**Palabras Clave:** Quiste Dentígero, descompresión quirúrgica, odontología pediátrica.

## Resumo

O cisto dentígero é o cisto de desenvolvimento odontogênico mais comum. Pode envolver qualquer dente incluso, embora molares e caninos sejam os mais afetados, seguidos pelos pré-molares e incisivos. Este trabalho tem como objetivo relatar o caso de uma paciente de 11 anos de idade com queixa de ausência do segundo pré-molar inferior direito (45) no arco dentário. Assim, uma revisão da literatura abordando o diagnóstico e tratamento desta condição é apresentada. No exame clínico e radiográfico pode-se notar imagem sugestiva de cisto dentígero, entretanto o diagnóstico foi confirmado por exame histopatológico e tomografia computadorizada de feixe cônico (cone beam). Optou-se por procedimento cirúrgico conservador de descompressão utilizando o exame cone beam como guia cirúrgico. Depois de 4 meses de acompanhamento clínico e radiográfico foi realizada a enucleação da lesão por curetagem. A paciente foi acompanhada durante 3 anos até a erupção completa do dente 45 e seu alinhamento no arco. Nenhuma lesão foi registrada e o tratamento ortodôntico mostrou-se eficaz. A técnica de descompressão cirúrgica foi segura, evitou danos a estruturas nobres e proporcionou uma rápida recuperação da paciente.

**Palavras-chave:** Cisto dentígero, descompressão cirúrgica, odontopediatria.

## Abstract

Dentigerous cyst is the most common developmental odontogenic cyst. It can involve any included tooth, although molars and canines are most frequently affected, followed by premolars and incisors. The aim of this article was to report the case of an 11-year-old female patient complaining of an eruption delay of a mandibular second premolar (45). Therefore, a literature review regarding the diagnosis and treatment of this condition is presented. At clinical and radiographic examination, the image suggested a dentigerous cyst; however, the diagnosis was confirmed by histopathological and cone-beam computed tomography (CBCT) exams. Surgical planning was carried out using a conservative method involving surgical decompression. CBCT was used as a surgical guide. At 4-month clinical and radiographic follow-up, cystic enucleation was performed by curettage. The patient was followed for 3 years until complete eruption and alignment of the teeth occurred. No lesion was recorded, and orthodontic treatment was proven to be successful. The surgical decompression was completely safe, avoiding damage in important structures, and resulted in rapid recovery of the patient.

**Keywords:** Dentigerous cyst, surgical decompression, pediatric dentistry.

## Introduction

Cystic lesions are characterized by the presence of a cavity lined by epithelial cells and filled with a liquid secreted by these and/or surrounding tissue cells (1). Internal pressure generated by fluid is responsible for the growth of the lesion, which is radiographically represented as a well-defined radiolucent area. Cysts of the jaws can be classified as odontogenic and non-odontogenic. Odontogenic cysts may originate from both epithelium of tooth formation and mesenchymal tissue, with periapical and dentigerous cysts being the most common ones (2).

Dentigerous cysts arise from a follicle of an impacted or a developing tooth through the accumulation of fluid between the reduced enamel epithelium and the crown of the affected tooth (3). These cystic lesions are often associated with third molars, upper canines and lower second premolars (4). They commonly occur in Caucasian

males, with an estimated rate of 1.44 per 100 impacted teeth (3,4). The highest incidence rates occur during the second to the fourth decade of life (5). Dentigerous cyst represents 14-20% of all cysts of the jaws and 15.2-33.7% of all odontogenic cysts (4). In addition, it is known to be the most common cyst in childhood (6).

Clinically, dentigerous cysts are asymptomatic and discovered occasionally during routine radiographic evaluation. The presence of an unilocular radiolucent area circumscribed around the impacted tooth or developing crown is considered to be the classic finding for differential diagnosis (5). Regarding cystic lesion size, in some cases, dentigerous cysts may become large, changing the original position of the involved tooth and leading to bone and root resorption. Consequently, it is essential to be aware of treatment modalities, especially for children, in which more conservative surgery should be considered to avoid injuries to centres of facial growth.

Taking into consideration the importance of correct diagnosis using images for a safer therapeutic approach, this article reports a clinical case to characterize the main features of impacted teeth with dentigerous cyst and the treatment guided by cone-beam computed tomography (CBCT) imaging. Therefore, it presents a review of the literature relating to this condition.

## Literature Review

### Diagnosis

Dentigerous cyst diagnosis occurs through imaging and histopathology, as these lesions are often asymptomatic and may exist for years without being discovered. Patients usually do not report pain or discomfort associated with these kinds of lesions. However, an important sign is the absence of a tooth during clinical examination, which makes this a low-sensitivity exam for dentigerous cyst diagnosis. In some cases, dentigerous cysts become large, leading to local inflammation and bone expansion, which may result in facial asymmetry and even mandibular fracture (6).

Regarding dentigerous cyst radiographic findings, it is typical to observe a well-defined unilocular radiolucent area associated with the crown of a developing or impacted tooth, which is often detected in a routine evaluation. However, this exam alone is insufficient to reach a final diagnosis due to similarities with other odontogenic lesions, such as keratocyst, central giant cell granuloma and unicystic ameloblastoma. Three-dimensional CBCT provides additional diagnostic information, such as the accurate and reliable measurements of cystic diameter and volume, proximity to important anatomical structures and precise location of the involved tooth (7). It is important to highlight that these pieces of information are essential to determining the surgical technique and planning treatment.

The final diagnosis of dentigerous cyst must be established by an association of clinical examination and imaging, followed by histopathologic confirmation. The presence of a pericoronal radiolucent area larger than 4 mm in diameter, histological findings of a non-keratinized stratified squamous epithelium and a cystic space between the enamel and the surrounding tissue during surgery are the recommended criteria for an accurate dentigerous cyst diagnosis (3).

### Treatment Modalities

Treatment of dentigerous cysts consists of complete surgical enucleation and associated impacted tooth removal (5). However, when a developing permanent tooth

is involved, more conservative treatment approaches must be considered, such as decompression or marsupialization (8). Both techniques aim to relieve intracystic pressure to promote potential bone regeneration and, consequently, reduce lesion size. This is a crucial point regarding large cyst treatment, as there is a risk of injuring anatomical structures, such as the inferior alveolar nerve, and the potential of causing mandibular fracture when enucleation is the first treatment choice. Furthermore, it was reported that when using decompression techniques, spontaneous eruption of impacted teeth can be expected in association with cystic lesion reduction (9).

Marsupialization involves the creation of a wide surgical bone window followed by the connection of the inner cystic wall with the oral mucosa to promote cystic content drainage (10). On the other hand, during decompression, limited access is created in the cystic capsule, and a tube is positioned to encourage drainage and allow for the irrigation of the cavity (11). This approach is especially interesting for paediatric patients, as it enables dentition development, minimizes injury to surrounding tissues and does not interfere with craniofacial growth (8), making the capsule lesion's removal safer and less invasive.

The eruption of the impacted tooth affected by the dentigerous cyst may occur up to 3 months after decompression/marsupialization, and orthodontic traction should be considered after this period (9). The prognosis associated with dentigerous cyst is considered to be good, and recurrence is rare after definitive treatment (5).

## Case Report

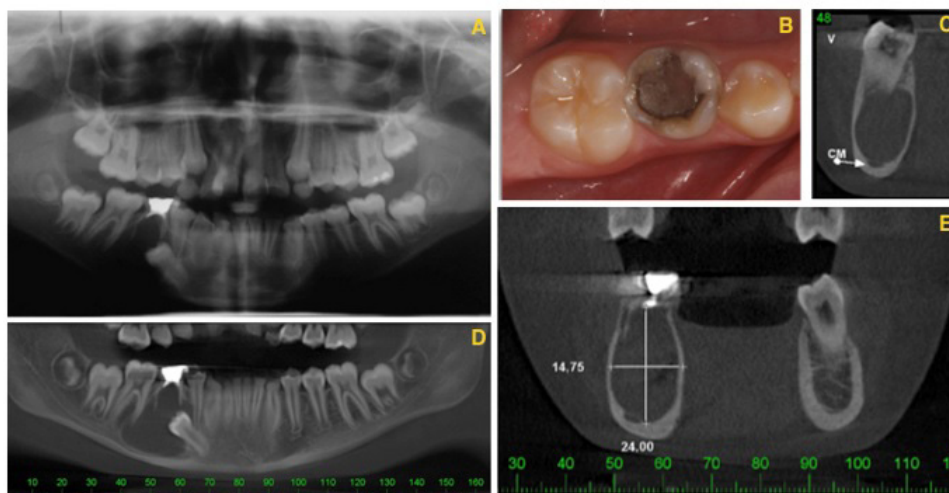
An 11-year-old female patient came to the Pediatric Clinic of Sao Paulo State University (Unesp) - School of Dentistry, Araraquara for evaluation and orthodontic treatment. At clinical examination, there were neither changes in the texture and integrity of the skin and mucosa nor signs of swelling or regional lymphadenopathy. In panoramic radiograph, the presence of an extensive radiolucent image was noted on the right side of the jaw surrounding the tooth 85 and closely related to the crown of the tooth 45 without reports of painful symptoms and with a hypothesized diagnosis of dentigerous cyst. Due to the lesion extension and possible involvement of the noble structures, CBCT was requested for better assessment and planning of the case. Analysis of these images revealed a unilocular hypodense lesion surrounded by a hyperdense halo. [Figure 1](#) provides details about the lesion location, such as the proximity to the mandibular canal.

The treatment plan consisted of two surgical times, the first being cystic cavity decompression and the second being the enucleation of the cyst. Before surgery, complementary haematological exams were conducted primarily to evaluate blood coagulation. Then, the right deciduous mandibular second molar (85) was extracted. After the cystic cavity was accessed directly, a sterile rubber cannula was positioned and was held via suture. Next, the cavity was irrigated with saline solution. The right mandibular second premolar was preserved in position. The patient was medicated with analgesic and antibiotic, and the parents were instructed to perform clean-up and daily irrigation with saline solution. The patient was evaluated monthly until the appropriate time came to complete the second surgical step ([Figure 2](#)).

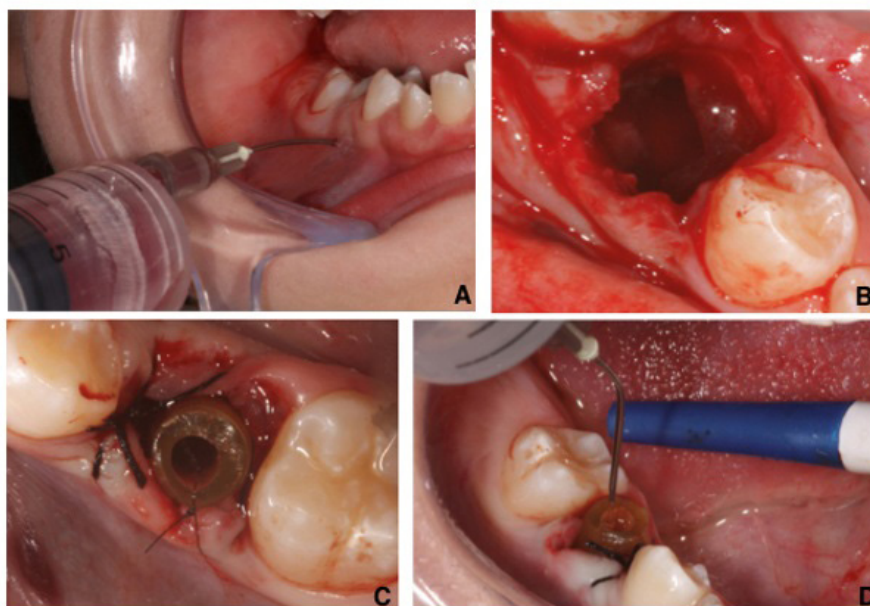
After 4 months of clinical and radiographic follow-up ([Figure 3A](#)), decreased cystic cavity and bone neoformation were noted. Cystic enucleation was performed by curettage of the cavity ([Figure 3B](#)), and removed fragments were sent for histopatholo-

gical analysis, which confirmed the diagnosis of dentigerous cyst. Again, the patient was medicated with analgesic for three days. Weekly observation occurred for a month (Figure 3C).

After 2 years of follow-up, the eruption of the lower right second premolar was observed without the need for orthodontic traction (Figure 4A). After one more year, the tooth was aligned in the dental arch with orthodontic appliance (Figures 4B-D).

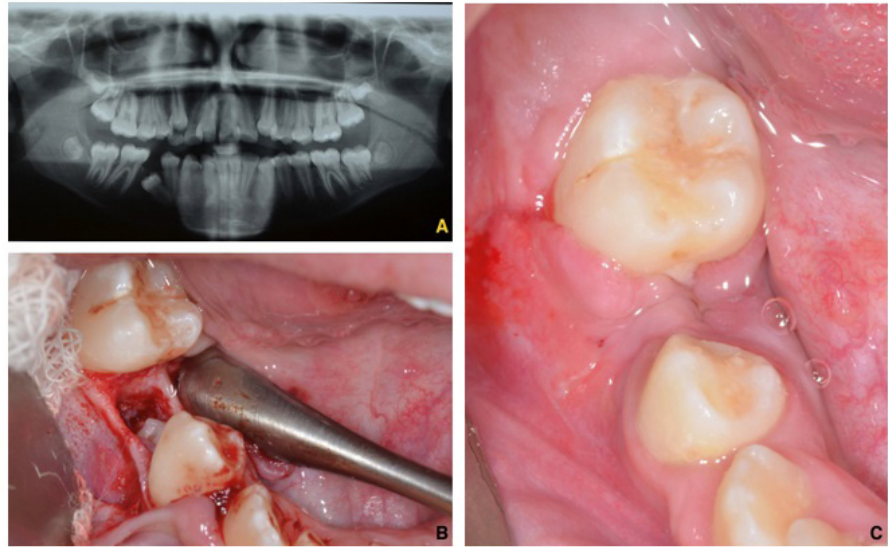


**Figure 1.** (A) Panoramic radiograph; (B) Initial clinical aspect; (C) Cross section showing the proximity of the lesion to the mandibular canal; (D) Panoramic image; (E) Coronal view and extension of the lesion.

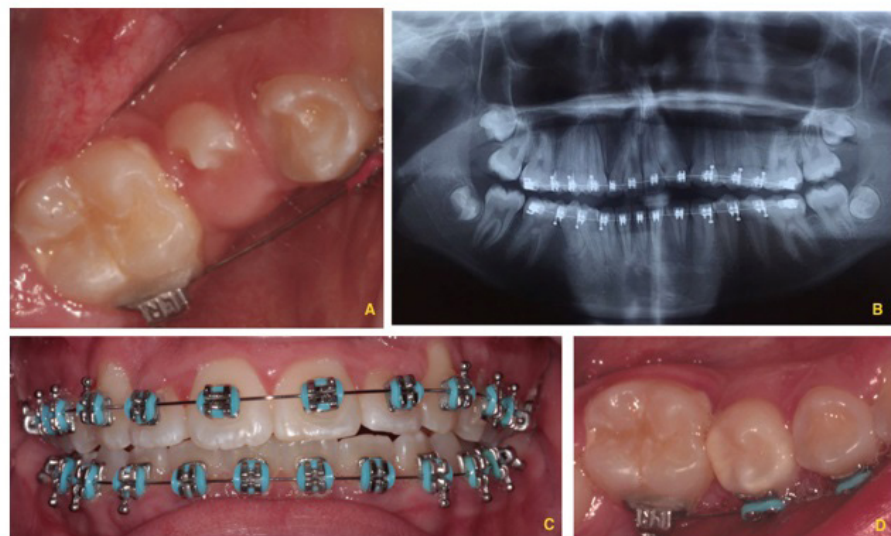

**Figure 2.** (A) Aspiration of the cystic liquid; (B) Access to the cystic cavity after tooth extraction (*right deciduous mandibular second molar*); (C) Sterile rubber cannula positioned and irrigation of the cystic cavity with saline solution; (D) Final appearance immediately after the first surgery.





**Figure 3.** (A) Panoramic radiograph at 4-month follow-up; (B) Curettage of the cystic cavity; (C) Postoperative at 1 week.



**Figure 4.** (A) 2-year follow-up - eruption of the lower right second premolar without the need for orthodontic traction; (B, C, D) Tooth erupted and aligned in the lower dental arch after 3 years of follow-up.

## Discussion

The treatment of cystic odontogenic lesions involves a series of abnormalities that the clinician must consider before determining what would be the most adequate technique for each type of lesion. It is interesting to note that the patient's age, size of the cystic cavity, presence of anatomic structures associated with the lesion, and clinical importance of the tooth involved may have a direct influence on the success of the selected treatment. In the case of dentigerous cysts, two surgical techniques may be indicated: (1) complete surgical enucleation of the lesion with or without osteotomy and (2) decompression/marsupialization, which aims to reduce the internal hydrostatic pressure of the cyst, allowing centripetal bone growth from the periphery to the interior of the cavity (8).

Generally, the standard treatment for dentigerous cysts is complete surgical enucleation of the lesion and extraction of the teeth involved (12), representing the therapy of choice in cases in which cysts are of smaller size and there is no relationship of proximity to important anatomic structures. This represents a definitive treatment with the possibility of histological study of the lesion. However, for cysts with large dimensions and accentuated bone loss, as described in the case reported in this article, any invasive surgical procedure could cause damage to the adjacent anatomic structures, such as the inferior alveolar canal, maxillary sinus and nasal cavity. In addition, there is a risk of complications, such as mandibular fracture, sinusitis and deficit in the inferior alveolar and infra orbital nerves (8), which contraindicate the use of this technique.

Decompression of odontogenic cystic lesions has been widely used as a more conservative alternative treatment that requires a smaller surgical window, creating an opening to the cystic cavity by suturing a device (tube or tent) at its periphery (13). This procedure relieves internal pressure, favouring the formation of bone tissue, reducing the risks of complications in comparison to enucleation, curettage and resection; however, this requires more frequent follow-up (13). According to Koca et al. (2009) (14), this technique must be the first treatment option in children, especially when the permanent tooth associated with the lesion prevents it from erupting. Nevertheless, the main disadvantage of cystic decompression is that the pathological tissue is left "in situ" without meticulous histological exam. Although the tissue collected from the surgical window may be submitted for histological exam, there may be a more aggressive lesion in the residual tissue (15).

In this reported case, apart from the risk of mandibular fracture, it was impossible for the permanent tooth associated with the lesion to erupt, and an attempt to enucleate the cyst could injure this tooth. CBCT was essential for planning a safe surgery because it showed clear evidence of the relationship between the lesion and the adjacent structures, especially the noble structures. Therefore, performing decompression was critical to reducing the cystic cavity and bone defect. After four months of follow-up, cystic reduction and bone neoformation were observed, making it feasible to perform complete enucleation of the remaining lesion. According to Zhao et al. (2011) (16), the time to perform enucleation after decompression/marsupialization is generally determined by the morphological changes within the cystic cavity. Therefore, it may be safely performed only when there is sufficient bone tissue formation. However, studies that have evaluated bone repair after decompression/marsupialization are scarce.

The decision to use the decompression technique at the first surgery followed by complete enucleation allowed for lesion repair without transoperative and postoperative complications. In addition, it allowed for the maintenance of the tooth associated with the cyst in the case reported. The benefits of this approach may be especially important for children and include the preservation of tooth germs, minimal harm to skeletal growth, and lower risk of damage to anatomic structures adjacent to the lesion, such as the maxillary sinus, mandibular nerve, and nasal and orbital cavities. Furthermore, children and their parents may show greater cooperation in the face of a less invasive approach (8).

Moreover, the use of treatment modalities with the purpose of alleviating internal cystic pressure are suggested to promote spontaneous eruption of the teeth that are enveloped by the cyst (17). Miyawaki et al. (1999) (18) observed that impacted teeth are capable of erupting more quickly if marsupialization is performed while the tooth

has the capacity to erupt, as there is a close relationship between this potential and the level of tooth root formation (19). Therefore, teeth that have not yet concluded their root formation have greater potential for spontaneous eruption. Other factors may also contribute to the spontaneous eruption of the impacted tooth, such as the presence of a rate of interdental space greater than or equal to 1.0 mm (20) and the angulation of the tooth associated with the cyst so that the smaller the inclination, the greater its chance of erupting spontaneously (9).

According to the literature, children aged 10 and 11 years have a higher percentage of spontaneous eruption after marsupialization in comparison to older individuals (9,14,19,20). In the present case, the patient had favourable conditions for spontaneous eruption of tooth 45 (age, open apex, and little inclination). For this reason, the decision was made to follow-up on the case, and the beginning of its eruption in the oral cavity was observed at 6-month radiographic follow-up. However, in unfavourable cases and/or older individuals, spontaneous eruption generally does not occur, and orthodontic traction would be indicated with the purpose of guiding the occlusion or facilitating the surgical removal of the entire cyst with the impacted tooth (20). Therefore, additional operative time would be necessary for bracket bonding.

In conclusion, treatment of dentigerous cysts with large dimensions in children demands the use of less invasive techniques, with to the goal of preserving the tooth that is associated with the cyst. This approach stimulates bone repair and favours the spontaneous eruption of the related tooth. Therefore, decompression has been shown to be effective in reducing the cystic cavity and increasing bone density, allowing for subsequent enucleation of the lesion without surgical complications.

### Conflicts of Interest

-The authors declare no conflicts of interest.

### References

1. Gohel A, Villa A, Sakai O. Benign Jaw Lesions. *Dent Clin North Am*. 2016; 60(1):125-41.
2. Devenney-Cakir B, Subramaniam RM, Reddy SM, Imsande H, Gohel A, Sakai O. Cystic and cystic-appearing lesions of the mandible: review. *AJR Am J Roentgenol*. 2011; 196(6 Suppl):WS66-77.
3. Daley TD, Wysocki GP. The small dentigerous cyst: a diagnostic dilemma. *Oral Surg Oral Med Oral Pathol Oral Radiol Endod*. 1995; 79(1):77-81.
4. Benn A, Altini M. Dentigerous cysts of inflammatory origin: a clinicopathologic study. *Oral Surg Oral Med Oral Pathol Oral Radiol Endod*. 1996; 81(2):203-9.
5. Arce K, Streff CS, Ettinger KS. Pediatric Odontogenic Cysts of the Jaws. *Oral Maxillofac Surg Clin North Am*. 2016; 28(1):21-30.
6. Arjona-Amo M, Serrera-Figallo MA, Hernández-Guisado JM, Gutiérrez-Pérez JL, Torres-Lagares D. Conservative management of dentigerous cysts in children. *J Clin Exp Dent*. 2015; 7(5):e671-4.
7. Asutay F, Atalay Y, Turamanlar O, Horata E, Burdurlu MÇ. Three-Dimensional Volumetric Assessment of the Effect of Decompression on Large Mandibular Odontogenic Cystic Lesions. *J Oral Maxillofac Surg*. 2016; 74(6):1159-66.



8. Allon DM, Allon I, Anavi Y, Kaplan I, Chaushu G. Decompression as a treatment of odontogenic cystic lesions in children. *J Oral Maxillofac Surg.* 2015; 73(4):649-54.
9. Yahara Y, Kubota Y, Yamashiro T, Shirasuna K. Eruption prediction of mandibular premolars associated with dentigerous cysts. *Oral Surg Oral Med Oral Pathol Oral Radiol Endod.* 2009; 108(1):28-31.
10. Song IS, Park HS, Seo BM, Lee JH, Kim MJ. Effect of decompression on cystic lesions of the mandible: 3-dimensional volumetric analysis. *Br J Oral Maxillofac Surg.* 2015; 53(9):841-8.
11. Thomas EH. Cysts of the jaws; saving involved vital teeth by tube drainage. *J Oral Surg (Chic).* 1947; 5(1):1-9.
12. Naclério H, Simões WA, Zindel D, Chilvarquer I, Aparecida TA. Dentigerous cyst associated with an upper permanent central incisor: case report and literature review. *J Clin Pediatr Dent.* 2002; 26(2):187-92.
13. Nakamura N, Mitsuyasu T, Mitsuyasu Y, Taketomi T, Higuchi Y, Ohishi M. Marsupialization for odontogenic keratocysts: Long-term follow-up analysis of the effects and changes in growth characteristics. *Oral Surg Oral Med Oral Pathol Oral Radiol Endod.* 2002; 94(5):543-53.
14. Koca H, Esin A, Aycan K. Outcome of dentigerous cysts treated with marsupialization. *J Clin Pediatr Dent.* 2009; 34(2):165-8.
15. Peterson LJ, Ellis E III, Hupp JR and Tucker MR. *Contemporary Oral and Maxillofacial Surgery.* 3<sup>rd</sup> ed. St Louis: Mosby, 1998. p. 540.
16. Zhao Y, Liu B, Han QB, Wang SP, Wang YN. Changes in bone density and cyst volume after marsupialization of mandibular odontogenic keratocysts (keratocystic odontogenic tumors). *J Oral Maxillofac Surg.* 2011; 69(5):1361-6.
17. Celebi N, Canakci GY, Sakin C, Kurt G, Alkan A. Combined orthodontic and surgical therapy for a deeply impacted third molar related with a dentigerous cyst. *J Maxillofac Oral Surg.* 2015; 14(Suppl 1):93-5.
18. Miyawaki S, Hyomoto M, Tsubouchi J, Kirita T, Sugimura M. Eruption speed and rate of angulation change of a cyst-associated mandibular second premolar after marsupialization of a dentigerous cyst. *Am J Orthod Dentofacial Orthop.* 1999; 116(5):578-84.
19. Hyomoto M, Kawakami M, Inoue M, Kirita T. Clinical conditions for eruption of maxillary canines and mandibular premolars associated with dentigerous cysts. *Am J Orthod Dentofacial Orthop.* 2003; 124(5):515-20.
20. Fujii R, Kawakami M, Hyomoto M, Ishida J, Kirita T. Panoramic findings for predicting eruption of mandibular premolars associated with dentigerous cyst after marsupialization. *J Oral Maxillofac Surg.* 2008; 66(2):272-6.