

## Pharmacological treatment with cabergoline in three cats with acromegaly<sup>□</sup>

*Tratamiento farmacológico con cabergolina en tres gatos con acromegalia*

*Tratamento farmacológico com cabergolina em três gatos com acromegalia*

Elber A Soler Arias\*, MV, Sp; Jorge D García, MV; Víctor A Castillo, MV.

*Unidad de Endocrinología, Área de Clínica Médica de Pequeños Animales, Hospital Escuela, Facultad de Ciencias Veterinarias, Ciudad Autónoma de Buenos Aires, Argentina.*

*(Received: November 10, 2016; accepted: April 22, 2017)*

*doi: 10.17533/udea.rccp.v30n4a07*

### Abstract

**Anamnesis:** Three cats diagnosed with diabetes mellitus (DM) were referred for examination due to the presence of insulin resistance signs, which included polyuria, polydipsia, polyphagia and high fructosamine levels, even with insulin glargine doses greater than 2 U/Kg/application. **Clinical and laboratory findings:** All patients had enlarged facial features along with increased interdental space. The biochemical tests revealed high IGF-1 concentrations. The magnetic resonance imaging displayed enlarged pituitary gland in one of the cats and images compatible with a pituitary macroadenoma in the other two. Acromegaly was the final diagnosis. **Treatment approach:** Oral cabergoline at 10 µg/Kg every 48 h was administered. **Conclusion:** The treatment with cabergoline successfully decreased IGF-1 concentrations and all insulin resistance signs, and it enhanced glycemic control for the DM in the three cats. Our results suggest cabergoline could be used for the treatment of acromegaly in cats.

**Keywords:** *diabetes, dopaminergic agonist, growth hormone, hypersomatotropism, IGF-1, insulin resistance.*

### Resumen

**Anamnesis:** Tres gatos diagnosticados con diabetes mellitus (DM) fueron referidos para ser examinados debido a la presencia de signos de resistencia a la insulina, que incluían poliuria, polidipsia, polifagia, y de

□ To cite this article: Soler EA, García JD, Castillo VA. Pharmacological treatment with cabergoline in three cats with acromegaly. Rev Colomb Cienc Pecu 2017; 30:316-321.

\* Corresponding author: Elber Alberto Soler Arias. Unidad de Endocrinología, Área de Clínica Médica de Pequeños Animales, Facultad de Ciencias Veterinarias, UBA, Av. Chorroarín 280, Ciudad Autónoma de Buenos Aires, Argentina. E-mail: mveterinario@yahoo.es

valores elevados de fructosamina, incluso con dosis de insulina glargina mayor a 2 U/Kg/aplicación. **Hallazgos clínicos y de laboratorio:** Los tres gatos presentaron amplios rasgos faciales con aumento de los espacios interdentes. En la bioquímica sanguínea, la concentración de IGF-1 fue hallada elevada. La imagen por resonancia magnética mostró agrandamiento de la glándula hipófisis en uno de los gatos, e imágenes compatibles con un macroadenoma de hipófisis en los otros dos. El diagnóstico final fue de acromegalia. **Abordaje terapéutico:** Se administraron 10 µg/Kg de cabergolina cada 48 h, via oral. **Conclusión:** El tratamiento con cabergolina logró disminuir las concentraciones de IGF-1 y todos los signos de resistencia a la insulina con mejor control glucémico de la DM en los tres gatos. Los anteriores hallazgos sugieren que la cabergolina es una opción viable para el tratamiento de la acromegalia en gatos.

**Palabras clave:** *agonista dopaminérgico, diabetes, hipersomatotropismo, hormona de crecimiento, IGF-1, insulino resistencia.*

### Resumo

**Anamnese:** Três gatos diagnosticados com diabetes mellitus (DM) foram encaminhados para exame devido à presença de sinais de resistência à insulina, que incluíram poliúria, polidipsia, polifagia e altos níveis de fructosamina, mesmo com doses de insulina glargina superiores a 2 U/Kg/aplicação. **Achados clínicos e de laboratório:** Os três gatos apresentavam mudanças dos rasgos faciais e aumento do espaço interdental. As provas bioquímicas revelaram altas concentrações de IGF-1. A ressonância magnética mostrou incremento do tamanho da glândula pituitária em um dos gatos e imagens compatíveis com um macroadenoma pituitário nos outros dois. Com estes dados chegou-se ao diagnóstico de acromegalia. **Enfoque terapêutico:** Foram dadas 10 µg/Kg de cabergolina a cada 48 h, via oral. **Conclusão:** O tratamento com cabergolina diminuiu com sucesso as concentrações de IGF-1 e todos os sinais de resistência à insulina e aumentou o controle glicêmico para a DM nos três gatos. Conclusões anteriores evidenciam que a cabergolina é uma opção viável para o tratamento da acromegalia em gatos.

**Palavras chave:** *agonista dopaminérgico, diabetes, hipersomatotropismo, hormona de crescimento, IGF-1, resistência à insulina.*

---

### Introduction

Acromegaly (AMG) or hypersomatotropism is a disease generally attributed to a pituitary adenoma—somatotropinoma, which causes hypersecretion of growth hormone (GH; Katznelson *et al.*, 2014). Its diagnosis is usually suspected in cats affected by uncontrolled diabetes mellitus (DM) as a result of GH-induced insulin resistance (IR) or, secondarily, in those with neurological compromise resulting from the expansion of a pituitary tumor, and exceptionally in cats that have only typical AMG features (Scott-Moncrieff, 2010; Fracassi *et al.*, 2016). Treating IR to achieve good glycemic control becomes in most cases an essential goal in the management of AMG in cats (Scott-Moncrieff, 2010). To achieve this goal, procedures such as transsphenoidal surgery, cryohypophysectomy and radiotherapy, as well as pharmacological treatments with somatostatin analogs (octreotide and pasireotide) and selegiline (dopaminergic agonist) have been tried (Reusch,

2015). Although both surgery and radiotherapy have achieved a good outcome as treatment for AMG in cats, these turn out to be invasive methods, requiring not only anesthesia, but also specialized facilities (Reusch, 2015). Both short-acting and long-acting pasireotide have been tested with good response in cats with AMG, but their high cost is a limiting factor (Gostelov *et al.*, 2017).

In human medicine, cabergoline (Cbg), a potent D2 receptor dopamine agonist, used in monotherapy or in association with somatostatin analogs, has achieved normalization of GH and insulin-like growth factor-1 (IGF-1) levels, with tumor shrinkage in 30 and 50% of the patients with AMG (Marazuela *et al.*, 2014).

In veterinary medicine, Cbg was used with satisfactory results in 42.5% of dogs with pituitary-dependent hyperadrenocorticism, reducing ACTH (adrenocorticotrophic hormones) values, urinary cortisol, and size of pituitary tumors (Castillo *et al.*, 2008).

To the best of our knowledge, this is the first report describing the use and response obtained with Cbg for the pharmacological treatment of AMG in cats with DM.

### Anamnesis

Three short-haired doctored house cats, two males and a female, aged 13, 7, and 6, were referred to the endocrine unit presenting DM with difficult glycemic control. The three cats had been receiving an average dose equal to or higher than 2 U/Kg insulin glargine every 12 h (bid) and received a commercial diet for diabetic cats divided into two equal rations with each application of insulin. All of them presented polyuria (PU), polydipsia (PD) and polyphagia (PF), and slight weight loss in Case 1. One of the cats had been diagnosed with hypertrophic cardiomyopathy (Case 2), and none of them had been treated with glucocorticoids or progestagens.

### Clinical and laboratory findings

The main clinical findings are summarized in Table 1. Physical changes are depicted in Figure 1 (A-G).

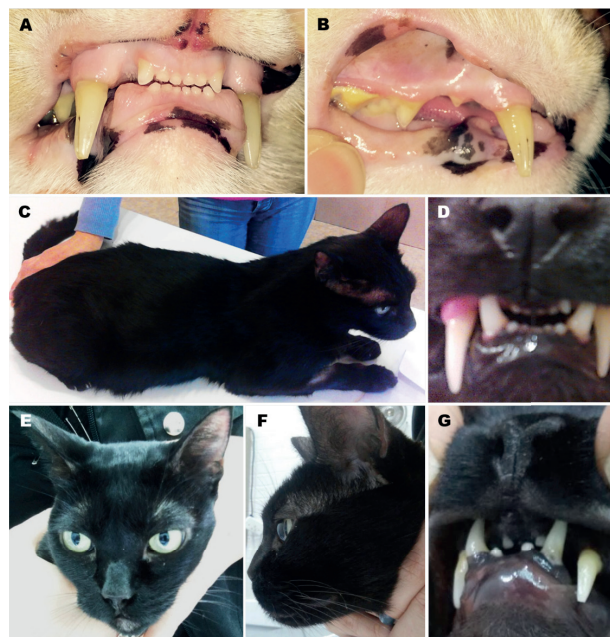Normal results were obtained in hemogram, serum biochemistry and urine culture for the three cats, except for Case 2, where there was evidence of an increase in total protein (8.4 g/L; reference value [RV]: 5-7 g/L), glutamic-pyruvic transaminase (GPT: 342 IU/L, RV: Up to 60 IU/L) and low levels of potassium (2.82 mmol/L, RV: 3.7-5 mmol/L). Infections by virus such as feline immunodeficiency virus (FIV) and feline leukemia virus (FeLV) were ruled out in the three cats using a commercial immunochromatographic assay (Speed DUO FeLV-FIV, Virbac). Other IR causes were also excluded, such as hyperthyroidism and Cushing's syndrome because the cats did not have typical clinical signs and, additionally, the level of total thyroxine, free thyroxine, and urine cortisol: Creatinine ratio (UCCR) were normal. Fructosamine in the three cats was high, confirming poor glycemic control of DM. Biochemical diagnosis of AMG was established by high IGF-1 levels obtained in the three cats (Table 2).

A T1-weighted magnetic resonance imaging (MRI) of the sellar region, following administration of the contrast medium (gadolinium), revealed increased

**Table 1.** Clinical findings in three cats with acromegaly.

Description of cats	Weight (Kg)	Clinical findings	Concurrent disease
Case 1, male, 13-years-old	3.5	"Mild" widening of facial features "Mild" widened of interdental spaces	DM
Case 2, male, 7-years-old	5.8	Enlargement of head and extremities Inferior prognathia Widened interdental spaces	DM, HC
Case 3, female, 6-years-old	4.5	Broad facial features "Severe" inferior prognathia "Severe" widened interdental spaces	DM

DM: Diabetes mellitus; HC: Hypertrophic cardiomyopathy.



**Figure 1.** Cases 1A and 1B: Widened interdental space; Case 2: (C-D): C: Generalized increase in body size, D: Increase in interdental space with lower prognathism; Case 3 (E-G): E: Enlarged face; F: Lower prognathism; G: Widened interdental space with lower prognathism.

pituitary size (5.7 mm width x 4.5 mm height —normal up to 5.0 mm width, and up to 3.3 mm height according to Feldman, 2015) for Case 1 (Figure 2A).

**Table 2.** Biochemical diagnosis and follow-up of acromegaly in three cats with diabetes mellitus treated with 10 µg/Kg Cbg every 48 h.

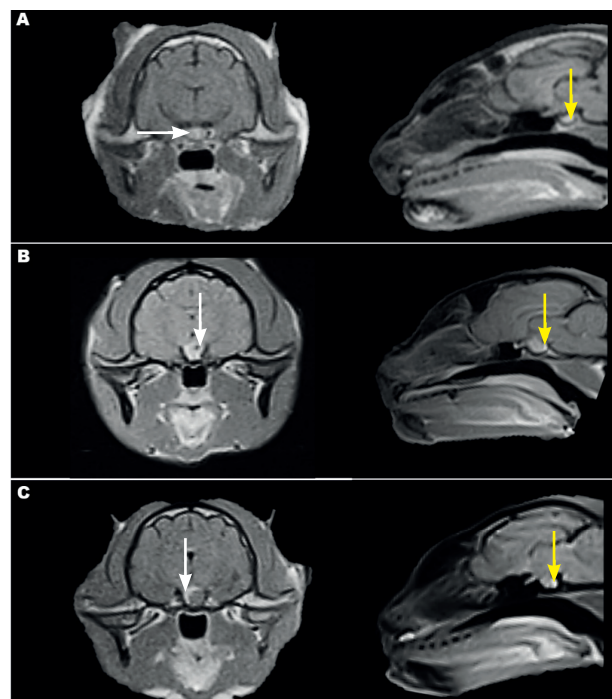
	Case 1	Case 2	Case 3
Weight (Kg)	3.5	5.8	4.5
Thyroxine (µg/dL)	1.6	1.4	1.3
Free thyroxine (ng/dL)	1.1	1.0	0.8
UCCR (x 10 <sup>-6</sup> )	27	23	22
<i>Before cabergoline administration</i>			
IGF-1 (ng/mL)	947	>1500	>1500
Fructosamine (µmol/L)	625	829	963
Insulin (U/cat, bid)	7	14	9
<i>After 3-month cabergoline administration</i>			
IGF-1 (ng/mL)	436	805	728
Fructosamine (µmol/L)	304	302	299
Insulin (U/cat, bid)	Wi	5	4
<i>After 6-month cabergoline administration</i>			
IGF-1(ng/mL)	425	510	492
Fructosamine (µmol/L)	297	318	311
Insulin (U/cat, bid)	Wi	3	2

Thyroxine, reference value (RV): 1-3 µg/dL (Chemiluminiscence-CLM); Free thyroxine, RV: 0.6-1.6 ng/dL (CLM); UCCR: Urine cortisol creatinine ratio, RV: <10 x 10<sup>-6</sup>, nonspecific feline Cushing syndrome (FCS): 10-36 x 10<sup>-6</sup>, diagnosis FCS: >36 x 10<sup>-6</sup> (Feldman, 2015); IGF-1: Insulin-like growth factor 1, RV cats with diabetes mellitus: 208-443 ng/mL, cats with acromegaly >1000 ng/mL (Niessen *et al.*, 2007), CLM; Fructosamine, RV: <322 µmol/L (Niessen *et al.*, 2007) nitroblue tetrazolium colorimetric method; bid: Every 12 h; Wi: Without insulin.

In turn, Case 2 showed a pituitary macroadenoma with suprasellar extension (7.6 mm length x 6.2 mm height), heterogeneous appearance, hyperintense rims and inner cystic hypointense areas (Figure 2B). Case 3 presented a 6.3 mm-diameter pituitary macroadenoma with granular appearance, partially surrounded by a hyperintense rim (Figure 2C). The MRI supplemented and confirmed AMG diagnosis in the three cats, thus defining the cause of IR.

### Treatment approach

In light of AMG confirmation —clinical signs, IGF-1 concentrations and MRI findings, we decided



**Figure 2.** T1-weighted magnetic resonance imaging (MRI) of the sellar region post-gadolinium (A-C). Left-side images in cross section and right-side images in sagittal section. A: Case 1; B; Case 2; C: Case 3. In A, increase in pituitary size, predominantly in width (white arrow) with heterogeneous intensity. In B, 6.2 mm-diameter pituitary macroadenoma with suprasellar extension presenting an inner hypointense area (white arrow). In C, pituitary macroadenoma with a 6.3 mm-suprasellar extension, heterogeneous granular appearance and partially hyperintense rim (white arrow). In A, B, and C: Neurohypophysis (yellow arrow).

that pharmacological therapy should be initiated based on human medicine records. An oral dose of 10 µg/Kg Cbg every 72 h (Wanke *et al.*, 2002) was prescribed, maintaining the same doses of insulin (Case 1: 7 U/cat, Case 2: 14 U/cat, Case 3: 9 U/cat) and their frequency (bid) in each cat. At home, the owners controlled water consumption, appetite, urination, and behavior, and they modified the insulin dose according to glucose values observed before each insulin application using a portable glucometer. Additionally, a complete physical examination was weekly performed on each cat. A partial resolution of clinical signs was observed by week four, with glycemias averaging 15 mmol/L in the three cats, without exceeding 17 mmol/L (IR: 3.8-8.3 mmol/L) using the following bid. Insuline/cat dose: 3.5 U (Case 1, previously 7 U), 8 U (Case 2, previously

14 U) and 5 U (Case 3, previously 9 U). Considering that the effect of Cbg is dose-dependent (Rains *et al.*, 1995), it was initially increased to 15 µg every 72 h in Case 1 (the first one diagnosed), but anorexia and transaminases increases were observed after the second dose (GPT: 194 U/L, RV: Up to 60 IU/L, GOT: 189 IU/L, RV: Up to 60 IU/L). The Cbg was suspended for two weeks until normal determination of transaminases was obtained. Considering this last finding, we chose to maintain a 10-µg dose, increasing the frequency of administration every 48 h, which was well tolerated. Controls of IGF-1 and fructosamine were performed in the third and sixth month of treatment (Table 2), as well as routine blood biochemistry, which was normal in all cats. On the third month, Case 1 reversed DM, maintaining normal, insulin-free fructosamine and IGF-1 values up to even the sixth month. Regarding Cases 2 and 3, bid insulin/cat requirements by the third month were 5 and 4 U (previously 8 and 5 U), and by the sixth month, 3 and 2 U (previously 5 and 4 U). In this way, normal fructosamine values and IGF-1 close to the maximum reference value were achieved.

## Discussion

Three cats with DM and IR resulting from concomitant presence of AMG are described. The IR diagnosis was based on persistence of clinical signs: PU/PD/PF with insulin doses higher than 1.5 U/Kg/application (Scott-Moncrieff, 2010). In AMG, IR arises from the combined action of GH and its mediator, IGF-1. The IGF-1 suppresses insulin secretions from pancreatic β cells, while GH increases production of endogenous glucose with less peripheral muscle uptake and alterations in post-insulin receptor signaling mechanisms (Scott-Moncrieff, 2010). The AMG diagnosis in the three cases was based on clinical signs, IGF-1 levels and abnormal pituitary findings revealed by MRI. Clinical signs, such as widened interdental space, enlargement of facial features and lower prognathism, expressed high IGF-1 concentration levels. The IGF-1 was essential for diagnosing and follow-up of AMG since, in addition to accurately reflecting 24-h GH secretions and being very stable, it offers high specificity (92%) and sensitivity (84%) for AMG diagnosis in cats (Reusch, 2015). Alternatively, GH trial is not readily available for

cats. Furthermore, the pulsatile secretion pattern of this hormone requires performing this trial along with oral glucose tolerance test, which presupposes a disadvantage for cats with DM (Barkan, 2004). These GH pulses can be erroneously interpreted as elevated in non-acromegalic cats (Reusch, 2015).

In Case 1, IGF-1 was slightly below the cut-off value (>1000 ng/mL) established by Niessen *et al.* (2007) for AMG diagnosis in cats, but considerably higher than that in non-acromegalic cats with DM (208-443 ng/mL) according to the same author. This suggests that many cats with AMG are likely to undergo subclinical stages with minor physical manifestation and subtler MRI findings than those presenting truly high IGF-1 levels. This reasoning is based on findings by Niessen *et al.* (2007) and Peterson *et al.* (2007) for acromegalic cats phenotypically indistinguishable from normal cats, without detectable pituitary masses in the MRI, probably due to microadenomas or pituitary hyperplasia (Niessen *et al.*, 2007; Lonser *et al.*, 2010; Khandelwal *et al.*, 2011; Feldman, 2015).

The use of Cbg in cats with AMG was suggested because it is highly available and economical compared to pasireotide. Bromocriptine and Cbg, two dopamine D2 receptor agonist drugs, have been used for treating hyperprolactinemia and acromegaly in humans (Rains *et al.*, 1995). However, Cbg has shown better results, fewer adverse effects and greater tolerability relative to bromocriptine in both humans and dogs (Wanke *et al.*, 2002; Castillo *et al.*, 2008; Marazuela *et al.*, 2014). Another advantage offered by Cbg is the longer interval between doses —only 3 times/week. It must be emphasized that Cbg has not been used to treat cats with acromegaly, and adverse effects and optimal doses are unknown. Increase of transaminases and anorexia were observed with 15 µg of Cbg every 72 h in Case 1; however, data are insufficient to state it as typical adverse effects of Cbg in cats with AMG.

After Cbg treatment, all three cats showed reduction of IGF-1, fructosamine and insulin requirements along with resolution of clinical signs by the third and sixth months. These results are similar to those by Gostelow *et al.* (2017) with short-action and long-acting pasireotide injection and, apparently, are more promising than those

obtained with radiotherapy (the most commonly used treatment for cats with acromegaly), where no such improvement in IGF-1 levels has been observed despite improving clinical signs with reduction of insulin requirements (Reusch, 2015).

Future studies should evaluate pituitary size in acromegalic cats after Cbg treatment, given the known antiproliferative and proapoptotic effects of Cbg on corticotropinoma, somatotropinoma and prolactinoma neoplastic cells, both in humans and dogs (Castillo *et al.*, 2008; Marazuela *et al.*, 2014). Due to the absence of neurological signs and given the enhanced glycemic control achieved with Cbg treatment, none of the owners agreed to perform MRI follow-ups.

### Conclusion

Despite the small number of cases, the apparent effect on IGF-1 reduction, IR reversal and improved glycemic control suggest that Cbg may hold promise for the treatment of feline AMG. This drug should be studied in a larger number of cases and during longer follow-ups to reach definitive conclusions.

The AMG may evolve in cats presenting minimal physical symptoms. Consequently, the use of IGF-1 in cats with insulin-resistant diabetes mellitus is recommended given that early diagnosis and Cbg treatment would enhance DM control in those cases.

### Conflict of interest

The authors declare they have no conflicts of interest with regard to the work presented in this report.

### References

Barkan AL. Biochemical markers of acromegaly: GH vs. IGF-I. *Growth Hormone & IGF. Research* 2004; 14: 97-100.

Castillo VA, Gomez NV, Lalia JC, Blatter MC, Garcia JD. Cushing's disease in dogs: Cabergoline treatment. *Res Vet Sci* 2008; 85(1):26-34.

Feldman EC. Hyperadrenocorticism in cats. In: Feldman EC, Nelson RW, Reusch CE, Scott-Moncrieff JCR, Behrend EN. *Canine & Feline Endocrinology*. 4<sup>th</sup> ed. Elsevier, 2015. p. 452-484.

Fracassi F, Salsi M, Sammartano F, Bo S, Kooistra HS. Acromegaly in a non-diabetic cat. *JFMS Reports* 2016; 2:1-4.

Gostelow R, Scudder C, Keyte S, Forcada Y, Fowkes RC, Schmid HA, Church DB, Niessen SJ. Pasireotide long-acting release treatment for diabetic cats with underlying hypersomatotropism. *J Vet Intern Med* 2017; 31(2):355-364.

Katznelson L, Laws ER, Melmed S, Molitch ME, Murad MH, Utz A, Wass JA. Acromegaly: An endocrine society clinical practice guideline. *J Clin Endocrinol Metab* 2014; 99: 3933-3951.

Khandelwal D, Khadgawat R, Mukund A, Suri A. Acromegaly with no pituitary adenoma and no evidence of ectopic source. *Indian J Endocrinol Metab* 2011; 15(3):250-252.

Lonser RR, Kindzelski BA, Mehta GU, Jane JA, Oldfield EH. Acromegaly without imaging: Evidence of pituitary adenoma. *J Clin Endocrinol Metab* 2010; 95(9):4192-4196.

Marazuela M, Ramos AL, Núñez MS, Bernabeu I. Cabergoline treatment in acromegaly: Pros. *Endocrine* 2014; 46:215-219.

Niessen SJ, Petrie G, Gaudiano F, Khalid M, Smyth JB, Mahoney P, Church DB. Feline acromegaly: An underdiagnosed endocrinopathy? *J Vet Intern Med* 2007; 21:899-905.

Peterson ME. Acromegaly in cats: Are we only diagnosing the tip of the iceberg? *J Vet Intern Med* 2007; 21:889-891.

Rains CP, Bryson HM, Fitton A. A review of its pharmacological properties and therapeutic potential in the treatment of hyperprolactinaemia and inhibition of lactation. *Drugs* 1995; 49:255.

Reusch CE. Disorders of growth hormone. In: Feldman EC, Nelson RW, Reusch CE, Scott-Moncrieff JCR and Behrend EN. *Canine & Feline Endocrinology*. 4<sup>th</sup> ed. Elsevier, 2015. p. 37-76.

Scott-Moncrieff JC. Insulin resistance in cats. *Vet Clin North Am Small Anim Pract* 2010; 40(2):241-257.

Wanke MM, Romagnoli S, Verstegen J, Concannon PW. Pharmacological approaches to pregnancy termination in dogs and cats including the use of prostaglandins, dopamine agonists, and dexamethasone. *Recent Advances in Small Animal Reproduction*. International Veterinary Information Services. 2002.