

Trypanosoma cruzi discrete typing units in Chagas disease patients with HIV co-infection

Margarita Bisio¹, Carolina Cura¹, Tomás Duffy¹, Jaime Altcheh², Salvador Óscar Giganti³, Sandra Begher⁴, Pablo Gustavo Scapellato⁵, Juan Miguel Burgos¹, Mariano Jorge Levin¹, Ricardo Schreck³, Héctor Freilij², and Alejandro Gabriel Schijman¹

¹ Laboratorio de Biología Molecular de la Enfermedad de Chagas, Instituto de Investigaciones en Ingeniería Genética y Biología Molecular (INGEBI-CONICET), Buenos Aires, Argentina. ² Laboratorio de Parasitología y Enfermedad de Chagas, Hospital de Niños Ricardo Gutiérrez, Buenos Aires, Argentina. ³ Servicios de Neurocirugía y Clínica Médica, HIGA Eva Perón, San Martín, Provincia de Buenos Aires, Buenos Aires, Argentina. ⁴ Unidad 2 Clínica Médica e Infectología, Hospital Ignacio Pirovano, Buenos Aires, Argentina. ⁵ Hospital de Agudos, Donación Francisco Santojanni, Buenos Aires, Argentina

ABSTRACT

Background. Natural populations of *T. cruzi* have been classified into six phylogenetic lineages or discrete typing units, *T. cruzi* I, IIa, IIb, IIc, IId, and IIe, believed to play a role in tissue tropism and disease pathogenesis. The impact of HIV infection in the *T. cruzi* genetic diversity in coinfecting patients is a scarcely explored field of parasitology.

Objective. To characterize parasitic lineages in clinical samples from patients co-infected with *T. cruzi* and HIV

Materials and Methods. We analyzed blood and lesions samples from 25 patients residing in Argentina, namely 8 infants born to 7 HIV - *T. cruzi* co-infected mothers, 3 indeterminate adult chagasic patients with HIV co-infection and 7 presenting cerebral Chagas due to AIDS. Molecular diagnosis and monitoring of etiological treatment was carried out by PCR targeted to kinetoplastid (kDNA) and/or satellite sequences. *T. cruzi* lineages were identified by means of PCR targeted to the intergenic spacer of miniexon gene and 24s ribosomal ARN genes. To characterize the infra-lineage diversity, restriction fragment length polymorphism (RFLP) of kDNA amplicons was carried out.

Results. Out of the 7 co-infected mothers, two transmitted both HIV and *T. cruzi* to their siblings, four transmitted only *T. cruzi*. The remaining case was a pregnant woman with cerebral Chagas disease who entered into a coma being treated with benznidazole; she did not transmit congenital Chagas disease nor HIV to her newborn.

Most bloodstream populations belonged to *T. cruzi* IId, with unique minicircle signatures for each patient's strain, but identical signatures between strains from mothers and their congenitally infected infants. Mixtures of lineages *T. cruzi* I and *T. cruzi* IId were also detected. Differential tissue tropism of *T. cruzi* IIb and *T. cruzi* I was found in patients with cerebral chagas. Minicircle signatures showed complex patterns suggestive of polyclonal populations.

Conclusions. The higher proportion of PCR positive samples suggests higher parasite loads that in chagasic population without HIV. The higher prevalence of *T. cruzi* IId in bloodstream is in agreement with previous findings in this region. The association of rare lineages at sites of encephalitis suggests differential tropism. The direct characterization of parasite lineages in

Solicitud de sobretiros: Alejandro G. Schijman, PhD, Vuelta de Obligado 2490, 2nd floor, zip 1428, Buenos Aires, Argentina. Phone: 05411- 4783-2871. E-mail: schijman@dna.uba.ar

Recibido: el 17 de junio de 2009. **Aceptado para publicación:** el 15 de diciembre de 2009

Este artículo está disponible en <http://www.revbiomed.uady.mx/pdf/rb092033.pdf>

Bisio *et al.*

clinical samples allowed identification of a higher prevalence of mixed infections, than previously assumed, from studies based on culture isolates.

Keywords: *Trypanosoma cruzi*, Chagas disease reactivation, kinetoplastid DNA, parasite lineage, tissue tropism, HIV, AIDS

RESUMEN

Linajes de *Trypanosoma cruzi* en pacientes con enfermedad de Chagas y coinfección por VIH

Introducción. Las poblaciones naturales de *T. cruzi* han sido clasificadas en seis linajes filogenéticos o unidades de tipificación discreta: *T. cruzi* I, IIa, IIb, IIc, IId y IIe, que pueden jugar un rol en el tropismo tisular y patogénesis de la enfermedad de Chagas. El impacto de la infección por VIH en la diversidad genética de *T. cruzi* en pacientes coinfectados es un campo poco explorado en parasitología.

Objetivo. Caracterizar linajes de poblaciones parasitarias naturales en muestras clínicas de pacientes coinfectados por *T. cruzi* y VIH.

Materiales y Métodos. Se analizaron muestras de sangre y/o lesiones de 25 pacientes residentes en Argentina: 8 pediátricos nacidos de 7 madres coinfectadas, 3 adultos con Chagas indeterminado y VIH y 7 con encefalitis chagásica por SIDA. El diagnóstico molecular y seguimiento de tratamiento etiológico se realizó por PCR hacia secuencias del minicírculo y/o satélite. Los linajes de *T. cruzi* fueron identificados por PCR para fragmentos de genes para miniexón y ARN ribosomal 24s. La diversidad infra-linaje fue caracterizada por polimorfismo de fragmentos de restricción de las regiones variables del minicírculo.

Resultados. De las 7 madres coinfectadas, 2 transmitieron tanto VIH como *T. cruzi* a sus hijos y 4 sólo transmitieron *T. cruzi*. El otro caso fue una mujer embarazada que al entrar en coma por presentar un cuadro de Chagas cerebral fue tratada con Benznidazol y no transmitió ni Chagas ni VIH a su hija. En los casos tratados se observó la negativización de la PCR. La mayoría de las

poblaciones parasitarias sanguíneas fueron *T. cruzi* IId, con perfiles de minicírculos particulares de cada paciente, excepto en pares madre-niño infectados, en que resultaron idénticas. Se hallaron poblaciones mixtas con *T. cruzi* I-IIId. En pacientes con reactivación chagásica se encontró tropismo diferencial de *T. cruzi* IIb y *T. cruzi* I en lesiones. En estos pacientes los perfiles de minicírculos mostraron patrones complejos sugiriendo poblaciones policlonales.

Conclusiones. La elevada proporción de muestras PCR positivas es indicativa de cargas parasitarias más elevadas que en población chagásica sin VIH. Esta exacerbación estaría también implicada en la alta tasa de transmisión vertical. La prevalencia de linaje IId en sangre periférica concuerda con lo hallado en población chagásica en la región. La asociación de linajes infrecuentes en lesiones asociadas a encefalitis chagásica sugiere tropismo diferencial. El análisis directo de linajes parasitarios en muestras clínicas permitió detectar una mayor prevalencia de infecciones mixtas que la detectada a partir de aislamientos en cultivo.

INTRODUCTION

Chagas disease is a serious, potentially life-threatening illness caused by a protozoan parasite called *T. cruzi*. It occurs mainly in Latin America where, during the 1980s, over 20 million people were thought to be infected. Since then, Latin American countries have made enormous efforts to control the infection, such that current estimates suggest that less than 8 million people remain infected (1). Due to social and economical restrictions in endemic countries, individuals from rural endemic areas have migrated to urban centers, leading to the urbanization of Chagas disease. More recently, cases have been identified in non-endemic countries in Europe, and in Canada and the United States. In urban areas the pandemics of acquired immunodeficiency syndrome (AIDS) is more prevalent and has opened the appearance of Chagas disease reactivation in individuals seriously immunocompromised by the human

immunodeficiency virus (HIV) and co-infected with *T. cruzi* (2-7). During reactivation, *T. cruzi* is persistent in the blood and it invades most frequently the central nervous system and the heart (2-4, 8-12). Cerebral chagomas show focal necrotic lesions indistinguishable from those caused by *Toxoplasma gondii*, so are frequently treated as cerebral toxoplasmosis (13).

The impact of HIV infection in the progression and severity of a previous *T. cruzi* infection is a poorly explored field of clinical parasitology. Natural populations of *T. cruzi* are composed of multiple clones, most of which are distributed into six phylogenetic lineages or discrete typing units (DTUs), designated as *T. cruzi* I, IIa, IIb, IIc, IId and IIe (14, 15) and recently renamed as *T. cruzi* I, IV, II, III, V and VI, respectively (16). *T. cruzi* I has a very large geographical distribution from North to South America, predominating in the Amazonian basin northwards, where domestic and sylvatic triatomines are involved in transmission in several endemic regions from Venezuela, Colombia, Central America and Mexico (17, 18). In these countries, *T. cruzi* I infects patients and different pathological forms have been observed (19-22).

However, information regarding the clinical relevance of this parasite lineage in the southern cone of America is scarce. Recent molecular evidence based on microsatellite typing allowed mapping the high heterogeneity of *T. cruzi* I populations and attempts to classify them based on nuclear genes are currently undergone (23-25). In contrast, *T. cruzi* IIb, IId and IIe populations are known to circulate predominantly in the southern cone of America, causing vectorial and congenital Chagas disease (26, 27).

In the present study, we aimed to characterize the main parasitic DTUs detectable in blood from indeterminate Chagas disease patients with HIV co-infection, and in both blood and tissue lesions in those presenting clinical reactivation due to AIDS.

MATERIALS AND METHODS

Patients

Patients were admitted for diagnosis, treatment and follow-up at diverse health centers in the metropolitan area of Buenos Aires city, not endemic for Chagas disease, namely Hospital Ignacio Pirovano, Hospital Eva Perón, Hospital Francisco Santojanni, Hospital Carlos Durand, Hospital Ricardo Gutiérrez and Hospital Juan A. Fernández.

Clinical samples were referred to LabMECh at INGEPI for molecular diagnosis and typing of *T. cruzi* populations.

This study fulfilled all criteria required by the Medical Code of Ethics and the Helsinki II statement and was approved by the Review Boards of the participating Institutions. Written informed consents were obtained directly from the patients.

Laboratory diagnoses

Routine serological assays for *T. cruzi* and Toxoplasmosis, histopathological studies, Microhematocrite, Strout tests and direct observation of trypomastigotes or amastigotes were performed in each health center taking care of each patient, following their current diagnostic practices (18). T1 and T2 weighted magnetic resonance imaging and cerebral Computerized Axial Tomography (CAT) scan with contrast were done at each center taking care of those patients with suspicion of cerebral reactivation disease.

Molecular characterization of natural parasite populations

The natural populations of *T. cruzi* detected in peripheral blood and tissue samples were characterized using different molecular approaches.

All blood and some cerebrospinal fluid samples were mixed with an equal volume of Guanidinium 0.6 M - EDTA 0.2 M pH 8.00 buffer, let stand at room temperature overnight and boiled for 15 minutes prior to DNA extraction with

phenol-chlorophorm, followed by isopropanol precipitation, as detailed in previous studies of blood samples (27).

Some cerebrospinal fluid samples, fresh, or paraffin-embedded brain biopsy samples were processed using the QiAMP mini kits for fluids or tissues (Qiagen, USA), as described before (28,29).

Amplification of repetitive sequences for molecular detection of *T. cruzi* DNA

PCR targeted to the high variable region of the multicopy minicircles (kDNA) was done using primers 121 and 122 and Taq Platinum polymerase (Invitrogen, USA) for hot start-PCR as reported elsewhere (27).

PCR targeted to the tandemly repeated nuclear satellite sequence was done as a confirmatory test in some cases, using primers *cruzi* 1 and *cruzi* 2 (30) by Real Time PCR. Briefly, the mixture contained Taq Platinum buffer 1x, MgCl₂ 3 mM, dNTPs 0.25 mM, oligonucleotides *cruzi* 1 (5'-ASTCGGCTGATCGTTTTTCGA-3') and *cruzi* 2 (5'-AATTCCTCCAAGCAGCGGATA-3') 0.5 μM each, Sybr Green 0.5 x, Taq DNA polymerase platinum 5 U/ μl (Invitrogen, USA) 0.5 Units in a final volume of 20 μl. Cycling conditions were 94°C during 5 min, and then 40 cycles of 94 °C 10 seconds, 58 °C 10 seconds and 72 °C 10 seconds in a Rotor-Gene™ Real Time Thermocycler (Corbett Life Science's, Australia). The fluorescence was read at the end of each cycle at 80 °C. Negative kDNA or sat-DNA findings were confirmed by amplification of apolipoprotein B human gene fragment (ApoB) in order to discard loss of material or carry over of PCR inhibitors. This was done by Real time PCR, using primers ApoB Fw (5'-TGGCAACACCAGCACAGACCATTTTCAGC-3') and ApoB Rv (5'-GTAGGAAAGCAGGTCAACCACAGAGTCAG-3') at a final concentration of 1 μM, with the remaining PCR reagents and cycling conditions as for *T. cruzi* real-time-PCR except that the temperature of annealing was 65 °C.

PCR based identification of discrete typing units

Trypanosoma cruzi DTUs were investigated in all kDNA or Satellite DNA positive clinical samples using lineage-specific nuclear genomic markers, including the intergenic region of the spliced leader genes (SL-IR), the D7 domain of the 24s alpha ribosomal RNA genes (24S rDNA) and the A10 fragment, using heminested hot-start conventional PCR or Real time PCR as described elsewhere (27). In order to confirm the identity of unusual DTUs in our study patients, the SL-IR and/or 24s rDNA fragments from the corresponding amplicons were purified in Qiagen columns and sequenced. Alignment with homologous sequences from reference *T. cruzi* stocks representing the different DTUs was done using Mega Software. Genbank accession numbers were AS FJ713356 and GQ303145.

Profiling of minicircle signatures

Two micrograms of kDNA-PCR products, purified from preparative agarose gels, were subjected to restriction fragment length polymorphism (RFLP) PCR, using 5 units of *MspI* plus *RsaI* or *AluI* plus *HinfI* during 3 hours at 37°C, as previously described (27). The digestion products were analysed by electrophoresis in 10% polyacrylamide gel stained with silver nitrate or Sybr green dye.

RESULTS

Chagas disease mothers co-infected with HIV and transmission of congenital Chagas disease

Seven HIV positive Argentinean mothers with *T. cruzi* infection and their 8 children were included in the study; their epidemiological data are shown in **Table 1**. Case one was studied during pregnancy and at delivery, case 2 was studied at delivery and the remaining ones were studied when their infants were referred to Hospital Ricardo Gutierrez for diagnosis of congenital infection (**Table 1**). Cases 2 and 5 transmitted HIV and *T.*

cruzi to their siblings, cases 3, 4, 6 and 7 transmitted only *T. cruzi* congenital infection whereas case 1 did not transmit any of both pathogens. Interestingly, case 1 was a pregnant woman vectorially infected at a highly endemic locality of Argentina, who developed chagasic encephalitis at her 31^d week of pregnancy and consequently was treated with benznidazole (5 mg/kg/day) for 90 days followed by prophylaxis (5 mg/kg/day thrice a week) with favorable outcome. PCR for *T. cruzi* k DNA was positive in pre-treatment blood samples and became negative in samples tested seven weeks after treatment initiation, persisting PCR negative during post-treatment prophylaxis. Furthermore, seroconversion to negative was identified from serum samples collected 16 weeks after treatment initiation. Serological analysis of a cerebral spinal fluid (CSF) sample taken two months after treatment initiation also gave negative results (data not shown). It is noteworthy that her newborn was not infected by *T. cruzi* as diagnosed by means of Microhematocrite and PCR at delivery and at 4 weeks of age, and did not acquire HIV infection. Negative serology against *T. cruzi* at 12 months of age allowed discarding congenital infection (**Table 1**).

Trypanosoma cruzi and HIV co-infections by syringe-mediated drug sharing among injective drug users

Two patients (cases 8 and 9, **Table 2**) were detected as seropositive for *T. cruzi* among 87 IDU individuals co-infected with HIV, who were diagnosed at the Service of Hospital Santojanni among 328 HIV positive individuals screened between January 2000 and October 2005. Both cases were men born and living in Buenos Aires city, who did not have any contact with triatomine bugs, nor received blood transfusions and in one of them the seronegativity of her mother was investigated, allowing discard congenital infection. However, both patients shared syringes. PCR for kDNA and Sat-DNA were positive in blood samples and *T. cruzi* IId was identified in both

cases (**Table 2**). Follow-up of these patients was not accomplished because they did not go back to the health center.

Cerebral Chagas reactivation in AIDS patients

Eight HIV positive patients were referred for molecular diagnosis of chagasic infection or for differential diagnosis of Chagas reactivation because of encephalitis and brain tumor masses in order to initiate their etiological treatment with benznidazole (Cases 10 to 17, **Table 2**, example in **Figure 1**). Cases 10 to 12 were reactive or nearly the cut-off line for anti-Toxoplasmosis serological analysis and also seropositive for Chagas disease; hence they were initially treated for cerebral toxoplasmosis. Anatomic-pathological observation of cerebral biopsy samples, microscopic observation of cerebrospinal fluid and/or Strout tested on their peripheral blood failed to give a precise diagnosis of *T. cruzi* infections in all these cases, except in case 12, who was Strout positive. Thus, final diagnosis of chagasic reactivation was assessed with the aid of k DNA and/or Real Time Sat-DNA PCR findings from brain biopsy or cerebrospinal fluid samples (example for case 12 in **Figure 2**), allowing initiation of their parasitocidal treatment with benznidazole.

Direct identification of *T. cruzi* DTUs in clinical specimens of HIV positive patients

Trypanosoma cruzi DTUs were investigated in kDNA or Sat-DNA PCR positive clinical samples using PCR procedures. Their findings are depicted in **Tables 1** and **2**. The parasite DTUs were identified in most samples. *T. cruzi* IId was found in all positive blood samples, except in two that presented mixtures with *T. cruzi* I; one of them belonged to a newborn from an HIV positive mother (case 5_p, **Table 1**) and the other one to a 41 year-old bolivian immigrant with AIDS reactivation (case 11, **Table 2**). In the latter case, the cerebrospinal fluid sample amplified only *T. cruzi* I (**Table 2**). It is noteworthy that in case 10, brain

Table 1: Description of *T.cruzi* - HIV coinfecting mothers and their infants and molecular identification of DTUs directly from clinical specimens

<i>T.cruzi</i> and HIV coinfecting Mothers					Infant						
Case	Argentinean locality of precedence	Clinical findings	k DNA PCR	<i>T.cruzi</i> DTU	Case	HIV status	Congenital Chagas Infection	Age at diagnosis	k DNA PCR	<i>T.cruzi</i> DTU	Outcome
1 _M	Santiago del Estero (EA)	Encephalitis Treated with benznidazole and seroconverted	Po (pre-tmt) Ng (post-tmt)	Tc IIb/d/e	1 _I	Ng	No	17 d	Ng	Nd	Not treated
2 _M	Chaco (EA)	Indeterminate Chagas disease	Po	Tc II d	2 _I	Po	Yes	2 d	Po	Tc II d	Died 72 hs pd
3 _M	Buenos Aires (nEA)	Indeterminate Chagas disease	Nd	Nd	3 _I	Ng	Yes	1 y	Po	Nd	Treated loss of follow-up
4 _M	Chaco (EA)	Indeterminate Chagas disease	Po	Tc II d	4 _{I1}	Ng	Yes	4 m	Po	Tc II d	Treated and cured Tw
					4 _{I2}	Ng	Yes	4 m	Po	Tc II d	
5 _M	Uk	Indeterminate Chagas disease	Nd	Nd	5 _I	Po	Yes	40 d	Po	Tc I + Tc II d	Treated loss of follow-up
6 _M	Buenos Aires (nEA)	IDU	Nd	Nd	6 _I	Ng	Yes	45 d	Po	Tc II d	Treated and cured
		Indeterminate Chagas disease									
7 _M	Uk	Indeterminate Chagas disease	Nd	Nd	7 _I	Ng	Yes	3 m	Po	Tc II d	Treated and cured

EA, endemic area; nEA, not endemic area; IDU, injecting drug user; Pd, post-delivery; Po, positive; Ng, negative; Uk, unknown; Nd, not done; tmt, Treatment; Tw, Twin brother and sister; d, day; m, month; y, year.

Table 2: Description of *T. cruzi* and HIV coinfecting patients with clinical manifestations of reactivation and molecular identification of DTUs directly from clinical specimens

Case	Age	Gender	Born	Clinical findings	Tested sample	PCR diagnosis (kDNA or Satellite)	<i>T. cruzi</i> DTU	Outcome
8	Adult	M	BA	Indeterminate Chagas disease #	blood	Po	Tc II d	alive
9	Adult	M	BA	Indeterminate Chagas disease #	blood	Po	Tc II d	alive
10	29	M	BA	Encephalitis ## **	blood Brain biopsy	Po Po	Tc II d Tc II b	alive
11	41	M	Bolivia	Encephalitis **	blood CSF	Po Po	Tc I + Tc II d Tc I	died
12	39	M	Argentina	Encephalitis	blood Brain necropsy	Po Po	Not detectable Tc II d	died
13	Adult	F	Uk	Uk	blood	Po	Tc II d	Uk
14	Adult	M	Uk	Encephalitis	blood CSF	Po Po	Tc II d Not detectable	Uk
15	36	M	Uk	Encephalitis	CSF	Po	Tc II b/d/e*	Uk
16	22	F	Uk	Cerebral tumor mass	blood	Po	Not detectable	Uk
17	54	M	Uk	Cerebral tumor mass	blood	Po	Tc II d	Uk

M, masculine; F, feminine; IDU, injecting drug user; BA, Buenos Aires ; Uk, unknown ; Po, positive; CSF, cerebral spinal fluid.

* Only PCR for intergenic region of miniexon genes was positive and hence *T. cruzi* IIb/d/e DTUs could not be differentiated.

**CD4 T-cell count at time of reactivation: case 10: 22 cell/mm³; case 11: 61 cell/mm³ # IDU ## Congenitally infected

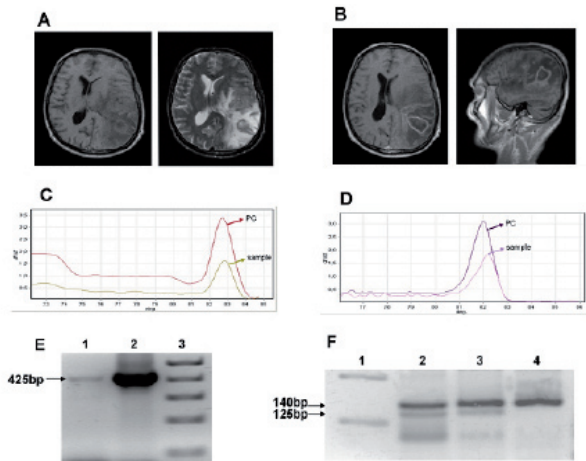


Figure 1. Report of case 13 with Chagasic encephalitis. **A.** T1-weighted MRI (left) showing hypotense lesion with perilesional edema in T2 sequence (right). **B.** T1-weighted MRI with gadolinium showing cystic like hypotense lesion with peripheric annular enhancement. **C.** Dissociation peaks of SybrGreen-fluorescent amplified DNAs from *T. cruzi* satellite sequence (C, 82.4°C) and **D.** Apolipoprotein-B human gene (D, 82.2°C) obtained after Real Time PCR from brain biopsy sample. Patient's samples appear as the lower peaks and positive controls (PC) (C: *T. cruzi* II CL-Brenner DNA, D: DNA from Jurkat cells) as the higher peaks. **E** and **F:** Agarose gel electrophoresis showing (E) the 425 bp product from the intergenic region of *T. cruzi* lineage II minicircle genes (Burgos *et al.*, 2007): Lane 1, patient's cerebral tissue sample; lane 2, *T. cruzi* II reference stock; lane 3, 1 Kbp DNA molecular weight marker and (F) 140 bp and 125 bp fragments from the 24S α rDNA D7 domain: Lane 1, 100 bp DNA molecular weight marker; lane 2, patient's cerebral tissue sample; lane 3, *T. cruzi* II d reference stock; lane 4, *T. cruzi* II b reference stock

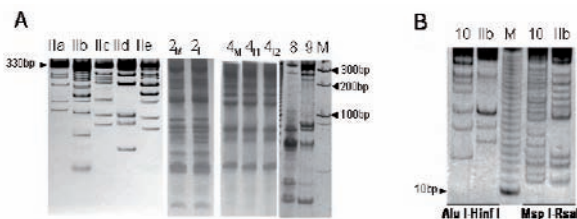


Figure 2. **A)** Comparison of RFLP-PCR based minicircle signatures, after double digestion of the 330 bp kDNA amplicon with Msp I-Rsa I from *T. cruzi* II d bloodstream parasite populations from cases 2 and 4 (Table 1) and 8 and 9 (Table 2) as well as reference clones for *T. cruzi* II DTUs, namely Tc IIa (CAN III), Tc IIb: (Tu 18); Tc IIc: (M5631), Tc II d (MnCl2) and Tc II e (Cl-Brenner). M; Molecular weight marker. **B)** Comparison of RFLP-PCR based minicircle signatures digested by Alu I-Hinf I and Msp I-Rsa I from *T. cruzi* II b parasite populations of cerebral chagoma from case 10 (lanes 10) and *T. cruzi* II b (lanes IIb) reference clone Tu 18 cl2. M, 10 bp DNA ladder

biopsy samples amplified *T. cruzi* II b populations and not the bloodstream *T. cruzi* II d, suggesting differential tissue tropism. These unusual DTUs were further confirmed by sequencing of the 24s alpha rDNA fragment from brain tissue of case 10 and of the SL-IR fragment from the amplicon obtained from the CSF sample of case 11.

In the other patients with encephalitis in which the parasites DTUs could be assessed, they belonged to *T. cruzi* II b/d/e or *T. cruzi* II d populations (example in **Table 2** for case 12).

Fingerprinting of minicircle signatures of parasitic populations

Characterisation of parasite genetic diversity at the infra-lineage level was also done from k DNA PCR positive samples obtained from these patients. The minicircle signatures were unique for each case, even among those ones infected with the same parasite lineage (**Figure 2A**), but were almost identical between maternal and neonatal populations in those cases with congenital transmission of *T. cruzi* (cases 2 and 4 of **Table 1**, **Figure 2**).

Comparison of minicircle signatures from the tested patients' samples with those from reference parasite clones from the corresponding DTUs allowed observation of a larger number of restriction fragments in populations from the HIV positive patients, indicating that patients' populations were more complex, suggesting polyclonality (**Figure 2**).

DISCUSSION

HIV and vertical transmission

Several authors have reported the vertical *T. cruzi* transmission rates ranging from 2% to 10.4% (31, 32). Previous studies suggested that *T. cruzi* parasitemia during pregnancy correlates with the risk of vertical transmission (27, 33, 34). Accordingly, HIV and *T. cruzi* co-infected mothers would present a higher risk of vertical transmission of *T. cruzi* (35). There is scarce information regarding vertical transmission of *T. cruzi* from

HIV positive pregnant women at the indeterminate or chronic phases of *T. cruzi* infection (36, 37). In this study HIV positive women were all kDNA-PCR positive, whereas the same PCR procedure allowed detection of 64.5 % of aged-matched non-HIV women at the indeterminate phase of Chagas disease (27). It is remarkable that the only HIV and *T. cruzi* co-infected mother who delivered a non-infected newborn was treated with benznidazole during gestation due to encephalitis (case 1, **Table 1**).

Chagas disease and drug abuse mediated transmission

Both cases 8 and 9 were detected among HIV infected patients with antecedents of injecting drug use and seropositivity for anti-*T. cruzi* antibodies at Hospital Santojanni. In that health center, the prevalence of seropositivity for *T. cruzi* was only one out of 247 among non-IDU patients with HIV infection screened individuals, but three among 87 IDU screened cases with HIV infection [$p=0,048$; $RR=9,15$ ($0,96 < RR < 86,73$) (Scapellato P, personal communication). The higher prevalence of HIV-*T. cruzi* co-infection among IDU individuals has recently been reported in other cohort from Argentina (38). Transmission of parasitic diseases through IDU also has been demonstrated in parasite diseases such as Malaria and Leishmaniosis (39), but not in Chagas disease. Transmission of Chagas disease by inoculation of low quantities of infected fluids, such as in laboratory accidents has been reported (40). Given that a proportion of indeterminate Chagas disease patients harbor patent parasitemia and that transfusional transmission from indeterminate Chagas disease patients occurs (40, 41), it is tempting to speculate that sharing needles could be another plausible route of transmission. Sartori *et al.* (42) found higher parasitemias in chagasic patients with HIV that in non-HIV carriers. All together, these data suggest that Chagas disease could be transmitted among IDU patients with HIV co-infection.

Cerebral Chagas reactivation in AIDS patients

The first published case of cerebral Chagas disease is dated in 1990 and consisted of an occupying cerebral mass, designated as cerebral chagoma in an immunosuppressed hemophylic patient (43). Cerebral Chagomas may present intralésion bleeding (44) and amastigote nests in glial and endothelial cells (45). Rapid specific diagnosis leading to prompt specific treatment and surgical evacuation of cerebral lesions may aid to a better evolution of these patients (3, 46-52). Although in the majority of the patients so far reported with cerebral reactivation, there are no data regarding their immunologic status, but it is possible to presume that Chagas reactivation tends to occur, similarly to what is seen with other opportunistic infections in AIDS, when the T-CD4 lymphocyte count is below 200 cells/mm³. In fact, in 10 previously reported cases where this information was available (3), the number of T CD4 lymphocyte number varied from 35 to 382 cells/mm³, and in seven of them the levels were below 200 cells/mm³. A recent study of 15 patients, Cordova *et al* (12) reported a median CD4 T-cell count at time of reactivation of 64 cells/ μ l (range 1-240) with 77% of patients presenting <100 CD4 T- cells/ μ l, as was the case for patients 10 and 11 of our study, from whom this information was available (**Table 2**).

Differential Diagnosis of Cerebral Chagas disease

Concurrent cerebral Chagas disease and Toxoplasmosis was reported in a patient with AIDS (47). However in some cases, specific parasite forms are difficult to be recognized by conventional histopathological analysis. Thus, PCR targeted to kDNA or satellite sequences, which are highly repetitive and therefore allow detection of low parasitic numbers, have shown their usefulness for differential diagnosis of Chagasic encephalitis (**Table 2**, 29, 46). In our more recently analysed cases, a novel Real time PCR approach targeting

the satellite DNA sequence was implemented, which has the advantage of not requiring post-PCR gel electrophoresis for product visualization, thus reducing amplicon carry-over contamination in the laboratory (**Figure 1**). Moreover, it can provide a quantitative measurement of the parasitic load in the tested sample (53, 54). It is expected that, once standardized, this Real Time PCR may become a useful diagnostic tool to resolve further clinical cases of difficult diagnosis. Future research towards the simultaneous molecular detection of *T. cruzi*, *T. gondii* and Epstein Barr virus (EBV) sequences in a single Real Time Multiplex PCR reaction should provide a useful tool for prompt resolution of these cases.

Moreover, the application of Quantitative Real Time PCR strategies may be used to follow-up patients under treatment with benznidazole (54) or novel parasitocidal drugs as well as to aid physicians in the management of patients under prophylaxis and in establishing criteria of cure.

T. cruzi DTUs in HIV positive patients

Previous reports that compared zymodemes of parasite stocks obtained from HIV positive patients with *T. cruzi* co-infection did not reveal significant differences regarding the tissue tropism or repartition of the strains (55). In our cohort, all patients showed *T. cruzi* II_d populations in bloodstream, except two cases, 5₁ and 11 that presented co-infections by *T. cruzi* II_d and *T. cruzi* I. *T. cruzi* II_d is the most frequently found lineage in blood samples of indeterminate Chagas disease patients from the southern cone of America (27). Cases 10 and 11 correspond to patients with a differential distribution of *T. cruzi* populations associated to reactivation. Consequently, their parasitic populations were further characterized using additional molecular tools, such as microsatellite typing and polymorphism of the kDNA (**Figure 2 B**, 29, 46).

Moreover, the presence of *T. cruzi* II_b populations in case 10, as identified by means of 24S α rDNA and A10 based amplification strategies (27,

56) was confirmed by sequencing of the 24S α rDNA amplicon. The characterization of *T. cruzi* nuclear DNA sequences from clinical specimens provides a starting point to determine the genomic structure of the parasite populations linked to human tissue tropism and disease.

This report also illustrates that *T. cruzi* I infections are found in patients of the southern cone of America, suggesting that this lineage is more prevalent than previously assumed in these countries (57). This DTU was confirmed by sequencing analysis of the SL-IR amplicon obtained from the CSF sample from case 11. The very low prevalence of *T. cruzi* I in the general population of southern America suggests that their strains would display lower levels of parasitic loads than *T. cruzi* II strains, at least at the indeterminate or chronic phases of Chagas disease. Indeed, the study of HIV positive patients together with the direct molecular analysis of blood and tissue samples linked to clinical reactivation brought to light the occurrence of mixed infections including *T. cruzi* I genotypes that caused severe disease (29).

Fingerprinting of minicircle signatures of parasitic populations

The analysis of the minicircle signatures using double digestion of kDNA amplicons provided evidence of the heterogeneity of populations belonging to a same DTU (cases 2, 4, 8 and 9) which were particular of each patient, except for those present in mothers and their congenitally infected siblings that depicted nearly identical populations, as was extensively discussed in a previous work (26). Comparing with minicircle signatures of reference *T. cruzi* clones, the patients' populations showed a larger number of minicircle fragments that reflect different minicircle subclasses indicative of polyclonal populations. Indeed, some of these patients' populations were subjected to analysis of polymorphism of microsatellite loci (58) and in most of them more than two microsatellite alleles were detected for different loci, which is

indicative of polyclonal strains (29, 46, 58). These findings suggest that the immunological status plays a role in the constraint of circulating sub-populations in bloodstream, giving rise to atypical variants and in some cases to unusual tissue locations in immunosuppressed patients. This was also observed in HIV positive patients co-infected with other protozoan organisms, such as *Leishmania* sp. and lower trypanosomatids (59, 60).

Finally, this report illustrates the usefulness of molecular strategies for diagnosis of Chagas reactivation in AIDS patients, as well as for epidemiological studies of *T. cruzi* and HIV co-infections.

ACKNOWLEDGEMENTS

This study fulfilled all criteria required by the Medical Code of Ethics and the Helsinki II statement and was approved by Ethical Committee. Written informed consent was obtained from the patient. We are grateful to R. Teijeiro, H. Lopez Alcoba, J. Levalle and F. Deccarlina of Hospital Pirovano for management and follow-up of the patient and to Bioq G Ballering, Dr H. Freilij and J. Altchek of the Laboratory of Chagas of Hospital Ricardo Gutiérrez for serological confirmation of *T. cruzi* infection.

This project received major support by WHO-TDR ID 20285, Bunge & Born Foundation, CONICET (PIP 5469), PICT 33955 from the National Agency of Science and Technology to AGS and CNPq/FAPEMIG.

AGS and MJL are members of CONICET Researcher's Career. JMB, CC, TD and MB are Research fellows of CONICET and HMSV of CAPES. HLF and JA are members of Consejo de investigación, GCBA Researcher's Career.

REFERENCES

- World Health Organization.** Reporte del grupo de trabajo científico sobre la enfermedad de Chagas TDR/GTC/06. 2005
- Gluckstein D, Ciferri F, Ruskin J.** Chagas' disease: another cause of cerebral mass in the acquired immunodeficiency syndrome. *Am J Med* 1992; 92:429-32.
- Ferreira MS, Nishioka S de A, Silvestre MT, Borges AS, Nunes-Araujo FR, Rocha A.** Reactivation of Chagas' disease in patients with AIDS: report of three new cases and review of the literature. *Clin Infect Dis* 1997; 25:1397-400.
- Sartori AM, Lopes MH, Caramelli B, Duarte MI, Pinto PL, Neto V, et al.** Simultaneous occurrence of acute myocarditis and reactivated Chagas' disease in a patient with AIDS. *Clin Infect Dis* 1995; 21:1297-9
- Sartori AM, Lopes MH, Benvenuti LA, Caramelli B, di Pietro A, Nunes EV, et al.** Reactivation of Chagas' disease in a human immunodeficiency virus-infected patient leading to severe heart disease with a late positive direct microscopic examination of the blood. *Am J Trop Med Hyg* 1998; 59:784-6.
- Sartori AM, Ibrahim KY, Nunes Westphalen EV, Braz LM, Oliveira OC Jr, Gakiya E, et al.** Manifestations of Chagas disease (American trypanosomiasis) in patients with HIV/AIDS. *Ann Trop Med Parasitol* 2007; 101:31-50.
- Corti M.** AIDS and Chagas' disease [Review]. *AIDS Patient Care STDs* 2000; 14:581-8.
- Ferreira MS, Nishioka SA, Rocha A, Silva AM, Ferreira RG, Olivier W, et al.** Acute fatal *Trypanosoma cruzi* meningoencephalitis in a human immunodeficiency virus-positive hemophiliac patient. *Am J Trop Med Hyg* 1991; 45:723-7.
- Rocha A, Ferreira MS, Nishioka SA, Silva AM, Burgarelli MK, Silva M, et al.** *Trypanosoma cruzi* meningoencephalitis and myocarditis in a patient with acquired immunodeficiency syndrome. *Rev Inst Med Trop Sao Paulo* 1993; 35:205-8.
- Rocha A, de Meneses AC, da Silva AM, Ferreira MS, Nishioka SA, Burgarelli MK, et al.** Pathology of patients with Chagas' disease and acquired immunodeficiency syndrome. *Am J Trop Med Hyg* 1994; 50:261-268.
- Pacheco RS, Ferreira MS, Machado MI, Brito CM, Pires MQ, Da-Cruz AM, et al.** Chagas' disease and HIV co-infection: genotypic characterization of the *Trypanosoma cruzi* strain. *Mem I Oswaldo Cruz* 1998; 93:165-9.
- Cordova E, Boschi A, Ambrosioni J, Cudos C, Corti M.** Reactivation of Chagas disease with central nervous system involvement in HIV-infected patients in Argentina, 1992-2007. *Int J Infect Dis* 2008; 12:587-92
- Corti M.** Enfermedad de Chagas y síndrome de inmunodeficiencia adquirida. *Enf Emerg* 2003; 5:13-7.
- Anonymous.** Recommendations from a satellite meeting. *Mem I Oswaldo Cruz* 1999; 94 (Suppl 1): 429-32.
- Brisse S, Barnabe C, Tibayrenc M.** Identification of six *Trypanosoma cruzi* phylogenetic lineages by random amplified polymorphic DNA and multilocus enzyme electrophoresis. *Int J Parasitol* 2000; 30:35-44.
- Zingales B, Andrade S, Briones M, Campbell D, Chiari E, Fernandes O, et al.** A new consensus for *Trypanosoma cruzi* intraspecific nomenclature: second revision meeting recommends TcI to TcVI. *Mem Inst Oswaldo Cruz* 2009, in press.

17. **Bosseno MF, Barnabé C, Magallón-Gastélum E, Lozano-Kasten F, Ramsey J, Espinoza B *et al.*** Predominance of *Trypanosoma cruzi* Lineage I in Mexico. *J Clin Microbiol* 2002; 40:627-32.
18. **World Health Organization.** Control of Chagas disease. Second Report of the WHO Expert Committee. WHO Tech rep ser 2002; 905:1-109.
19. **Monteón-Padilla VM, Vargas-Alarcón G, Vallejo-Allende M, Reyes PA.** Specific dilated cardiomyopathy. Chronic chagasic cardiopathy at the National Institute of Cardiology Ignacio Chávez. *Arch Cardiol Mex* 2002; 72 (Suppl 1):S148-52.
20. **Añez N, Carrasco H, Parada H, Crisante G, Rojas A, Fuenmayor C, *et al.*** Myocardial parasite persistence in chronic chagasic patients. *Am J Trop Med Hyg* 1999; 60:726-32.
21. **Añez N, Crisante G, da Silva FM, Rojas A, Carrasco H, Umezawa ES, *et al.*** Predominance of lineage I among *Trypanosoma cruzi* isolates from Venezuelan patients with different clinical profiles of acute Chagas' disease. *Trop Med Int Health* 2004; 9:1319-26.
22. **Sousa OE, Samudio F, de Junca C, Calzada JE.** Molecular characterization of human *Trypanosoma cruzi* isolates from endemic areas in Panama. *Mem I Oswaldo Cruz* 2006; 101:455-7.
23. **Herrera C, Bargues MD, Fajardo A, Montilla M, Triana O, Vallejo GA, *et al.*** Identifying four *Trypanosoma cruzi* I isolate haplotypes from different geographic regions in Colombia. *Infect Genet Evol* 2007; 7:535-9.
24. **Falla A, Herrera C, Fajardo A, Montilla M, Vallejo GA, Guhl F.** Haplotype identification within *Trypanosoma cruzi* I in Colombian isolates from several reservoirs, vectors and humans. *Acta Trop* 2009; 110:15-21.
25. **Llewellyn MS, Miles MA, Carrasco HJ, Lewis MD, Yeo M, Vargas J, *et al.*** Genome-scale multilocus microsatellite typing of *Trypanosoma cruzi* discrete typing unit I reveals phylogeographic structure and specific genotypes linked to human infection. *PLoS Pathog* 2009; 5:e1000410.
26. **Virreira M, Truyens C, Alonso-Vega C, Brutus L, Jijena J, Torrico F, *et al.*** Comparison of *Trypanosoma cruzi* lineages and levels of parasitic DNA in infected mothers and their newborns. *Am J Trop Med Hyg* 2007; 77:102-6.
27. **Burgos JM, Altchek J, Bisio M, Duffy T, Valadares HM, Seidenstein ME, *et al.*** Direct molecular profiling of minicircle signatures and lineages of *Trypanosoma cruzi* bloodstream populations causing congenital Chagas disease. *Int J Parasitol* 2007; 37:1319-27.
28. **Schijman AG, Vigliano CA, Viotti RJ, Burgos JM, Brandariz S, Lococo BE, *et al.*** *Trypanosoma cruzi* DNA in cardiac lesions of Argentinean patients with end-stage chronic chagas heart disease. *Am J Trop Med Hyg* 2004; 70:210-20.
29. **Burgos JM, Begher S, Silva HM, Bisio M, Duffy T, Levin MJ, *et al.*** Molecular identification of *Trypanosoma cruzi* I tropism for central nervous system in Chagas reactivation due to AIDS. *Am J Trop Med Hyg* 2008; 78:294-7.
30. **Piron M, Fisa R, Casamitjana N, López-Chejade P, Puig L, Vergés M, *et al.*** Development of a real-time PCR assay for *Trypanosoma cruzi* detection in blood samples. *Acta Trop* 2007; 103:195-200.
31. **Bittencourt AL, Mota E, Ribeiro Filho R, Fernandes LG, de Almeida PR, Sherlock I, *et al.*** Incidence of congenital Chagas disease in Bahia, Brazil. *J Trop Pediatr* 1985; 31:242-8.
32. **Freilij H, Altchek J, Storino R.** Chagas congénito. In: Storino R, Milei J, editores. *Enfermedad de Chagas*. Buenos Aires: Mosby-Doyma Argentina; 1994. p. 267-78.
33. **Hermann E, Truyens C, Alonso-Vega C, Rodriguez P, Berthe A, Torrico F, *et al.*** Congenital transmission of *Trypanosoma cruzi* is associated with maternal enhanced parasitemia and decreased production of interferon gamma in response to parasite antigens. *J Infect Dis* 2004; 189:1274-81
34. **Moretti E, Basso B, Castro I, Carrizo Paez M, Chaul M, Barbieri G, *et al.*** Chagas' disease: study of congenital transmission in cases of acute maternal infection. *Rev Soc Bras Med Trop* 2005; 38:53-5.
35. **Scapellato PG, Bottaro EG, Rodriguez-Brieschke MT.** Mother-child transmission of Chagas disease: could co-infection with human immunodeficiency virus increase the risk? *Rev Soc Bras Med Trop* 2009; 42:107-9.
36. **Freilij H, Altchek J, Muchinik G.** Perinatal immunodeficiency virus infection and congenital Chagas disease. *Pediatr Infect Dis J* 1995; 14:161-2.
37. **Freilij H, Altchek J.** Congenital Chagas' disease: diagnostic and clinical aspects. *Clin Infect Dis* 1995; 21:551-5.
38. **Dolcini G, Ambrosioni J, Andreani G, Pando MA, Martínez Peralta L, Benetucci J.** Prevalence of human immunodeficiency virus (HIV)- *Trypanosoma cruzi* co-infection and injectable-drugs abuse in a Buenos Aires health center. *Rev Argent Microbiol* 2008; 40:164-6.
39. **Pineda JA, Gallardo JA, Macías J, Delgado J, Regordán C, Morillas F, *et al.*** Prevalence of and factors associated with visceral leishmaniasis in human immunodeficiency virus type 1-infected patients in southern Spain. *J Clin Microbiol* 1998; 36:2419-22.
40. **Hernández-Becerril N, Mejía AM, Ballinas-Verdugo**

Trypanosoma cruzi lineages and HIV co-infection

- MA, Garza-Murillo V, Manilla-Toquero E, López R, *et al.* Blood transfusion and iatrogenic risks in Mexico City. *Anti-Trypanosoma cruzi* seroprevalence in 43,048 blood donors, evaluation of parasitemia, and electrocardiogram findings in seropositive. *Mem I Oswaldo Cruz* 2005; 100:111-6.
41. Amato Neto V, Molinari HE, Siquiera AF, Lucas RS. Analise por meio da fixação do complemento do risco de aquisição da doença de Chagas a través de hemoterapia, por parte de pacientes politransfundidos. *Rev Goiana Med* 1975; 21:1.
 42. Sartori AM, Neto JE, Nunes EV, Braz LM, Caiaffa-Filho HH, Oliveira Oda C Jr, *et al.* *Trypanosoma cruzi* parasitemia in chronic Chagas disease: comparison between Human Immunodeficiency Virus (HIV)-positive and HIV-negative patients. *J Infect Dis* 2002; 186:872-5.
 43. Del Castillo M, Mendoza G, Oviedo J, Bianco RP, Anselmo AE, Silva M. AIDS and Chagas disease with central nervous system tumor-like lesion. *Am J Med* 1990; 88:693-4.
 44. Lazo JE, Meneses AC, Rocha A, Frenkel JK, Marquez JO, Chapadeiro E, *et al.* Toxoplasmic and chagasic meningoencephalitis in patients with human immunodeficiency virus infection: Anatomopathologic and tomographic differential diagnosis. *Rev Soc Bras Med Trop* 1998; 3:163-71.
 45. Lury KM, Castillo M. Chagas' disease involving the brain and spinal cord: MRI findings. *AJR Am J Roentgenol* 2005; 185:550-2.
 46. Burgos JM, Begher SB, Freitas JM, Bisio M, Duffy T, Altcheh J, *et al.* Molecular diagnosis and typing of *Trypanosoma cruzi* populations and lineages in cerebral Chagas disease in a patient with AIDS. *Am J Trop Med Hyg* 2005; 73:1016-8.
 47. Yoo TW, Mlikotic A, Cornford ME, Beck CK. Concurrent cerebral American trypanosomiasis and toxoplasmosis in a patient with AIDS. *Clin Infect Dis* 2004; 39:30-4.
 48. Nijjar SS, Del Bigio MR. Cerebral trypanosomiasis in an incarcerated man. *CMAJ* 2007; 176:448.
 49. Valerga M, Bases O, Martín M, Papucci T. Multifocal encephalitis in an AIDS patient. *Enferm Infecc Microbiol Clin* 2005; 23:569-70.
 50. Montero A, Cohen JE, Martinez DP, Giovannoni AG. Empirical anti-toxoplasma therapy in cerebral AIDS and Chagas disease. Presentation of 2 cases, review of the literature and proposal of an algorithm. *Medicina (B Aires)* 1998; 58:504-6.
 51. Pimentel PC, Handfas BW, Carmignani M. *Trypanosoma cruzi* meningoencephalitis in AIDS mimicking cerebral metastases: case report. *Arq Neuropsiquiatr* 1996; 54:102-6.
 52. De Queiroz AC. Tumor-like lesion of the brain caused by *Trypanosoma cruzi*. *Am J Trop Med Hyg* 1973; 22:473-6.
 53. Zago MP, Barrio AB, Cardozo RM, Duffy T, Schijman AG, Basombrío MA. Impairment of infectivity and immunoprotective effect of a LYT1 null mutant of *Trypanosoma cruzi*. *Infect Immun* 2008; 76:443-51.
 54. Duffy T, Bisio M, Altcheh J, Burgos JM, Diez M, Levin MJ, *et al.* Accurate real-time PCR strategy for monitoring bloodstream parasitic loads in chagas disease patients. *PLoS Negl Trop Dis* 2009; 3:e419.
 55. Perez-Ramirez L, Barnabé C, Sartori AM, Ferreira MS, Tolezano JE, Nunes EV, *et al.* Clinical analysis and parasite genetic diversity in human immunodeficiency virus/Chagas' disease coinfections in Brazil. *Am J Trop Med Hyg* 1999; 61:198-206.
 56. Brisse S, Verhoef J, Tibayrenc M. Characterisation of large and small subunit rRNA and mini-exon genes further supports the distinction of six *Trypanosoma cruzi* lineages. *Int J Parasitol* 2001; 31:1218-26.
 57. Di Noia JM, Buscaglia CA, De Marchi CR, Almeida IC, Frasch AC. A *Trypanosoma cruzi* small surface molecule provides the first immunological evidence that Chagas' disease is due to a single parasite lineage. *J Exp Med* 2002; 195:401-13.
 58. Valadares HM, Pimenta JR, de Freitas JM, Duffy T, Bartholomeu DC, Oliveira Rde P, *et al.* Genetic profiling of *Trypanosoma cruzi* directly in infected tissues using nested PCR of polymorphic microsatellites. *Int J Parasitol* 2008; 38:839-50.
 59. Chicharro C, Alvar J. Lower trypanosomatids in HIV/AIDS patients. *Ann Trop Med Parasitol* 2003; 97 (Suppl 1):75-8.
 60. Alvar J, Aparicio P, Aseffa A, Den Boer M, Cañavate C, Dedet JP, *et al.* The relationship between leishmaniasis and AIDS: the second 10 years. *Clin Microbiol Rev* 2008; 21:334-59.