

Aortic Valve-Sparing Operation with Reimplantation Technique

Cirugía de preservación de la válvula aórtica con técnica de reimplante

MARÍA C. ESCARAIN[†], MARÍA P. DUCZYNSKI, GERARDO E. BOZOVICH, ROBERTO R. FAVALORO^{MTSAC}

ABSTRACT

Introduction: The aortic valve-sparing operation offers the unique possibility of preserving the native valve in patients who need surgical treatment for aortic root disease.

Objective: The aim of this study was to assess the long term outcome of the aortic valve-sparing operation with reimplantation technique at the Hospital Universitario Fundación Favaloro.

Methods: A total of 66 patients underwent aortic valve-sparing operation from June 1998 to December 2011. Fifty three patients operated on with the aortic valve reimplantation technique were included in the study and 13 patients operated with the remodeling technique were excluded. Clinical and echocardiographic follow-up was performed. Aortic insufficiency was graded as 0: absent; 1+: mild; 2+: moderate; 3+: moderate-severe, and 4+: severe. Survival and freedom from aortic insufficiency >2+ and reoperation were analyzed using the Kaplan Meier method.

Results: Mean age was 45±17 years, 79% of patients were men and 36% had Marfan syndrome. In-hospital and late mortality was 3.8%. Survival at 8 years was 91% (95% CI: 78-97%). Freedom from aortic insufficiency > 2+ and reoperation at 8 years was 84% (95% CI: 66-92%) and 90% (95% CI: 74-96%), respectively. Preoperative aortic insufficiency >2+ was not associated with aortic insufficiency >2+ (RR 1.45; p=0.16) or reoperation (RR 1.96; p=0.4) during follow-up.

Conclusions: In our experience, the aortic valve-sparing operation with reimplantation technique in patients with aortic root disease shows comparable results to other published international series. This surgical technique is a valid option for eligible patients duly informed about the different surgical techniques, and should be performed in experienced centers.

Key words: Aneurysm - Aorta - Aortic insufficiency - Cardiac surgery.

RESUMEN

Introducción: La cirugía de preservación de la válvula aórtica ofrece la única oportunidad de conservar la válvula en pacientes que requieren una intervención quirúrgica por enfermedad de la raíz aórtica.

Objetivo: Analizar los resultados a largo plazo de la cirugía de preservación de la válvula aórtica con técnica de reimplante en el Hospital Universitario Fundación Favaloro.

Material y métodos: Desde junio de 1998 a diciembre de 2011 se intervinieron 66 pacientes con cirugía de preservación de la válvula aórtica. Se incluyeron 53 pacientes operados con técnica de reimplante y se excluyeron 13 pacientes intervenidos con técnica de remodelación. Se realizó seguimiento clínico y ecocardiográfico. La insuficiencia aórtica se clasificó en: 0: ausente; 1+: leve; 2+: moderada; 3+: moderada-grave; 4+: grave. La supervivencia y la ausencia de insuficiencia aórtica > 2+ y de reoperación se analizaron con el método de Kaplan-Meier.

Resultados: La edad media de los pacientes fue de 45 ± 17 años, el 79% eran de sexo masculino, el 36% con síndrome de Marfan. La mortalidad hospitalaria y tardía fue del 3,8%. La supervivencia global a los 8 años fue del 91% (IC 95% 78-97%). La ausencia de insuficiencia aórtica > 2+ y de reoperación a los 8 años fue del 84% (IC 95% 66-92%) y del 90% (IC 95% 74-96%), respectivamente. La insuficiencia aórtica preoperatoria > 2+ no se asoció con insuficiencia aórtica > 2+ (RR 1,45; p = 0,16) ni con reoperación (RR 1,96; p = 0,4) durante el seguimiento.

Conclusiones: En nuestra experiencia, la cirugía de preservación de la válvula aórtica con técnica de reimplante en pacientes con patología de la raíz aórtica muestra resultados comparables a los de otras series internacionales publicadas. Esta técnica quirúrgica es una opción válida para pacientes seleccionados, correctamente informados sobre las diferentes técnicas quirúrgicas, y debe realizarse en centros con experiencia.

Palabras clave: Aneurisma - Aorta - Insuficiencia aórtica - Cirugía cardíaca.

REV ARGENT CARDIOL 2014;82:285-291. <http://dx.doi.org/10.7775/rac.v82.i4.2276>

Received: 06/13/2013 Accepted: 09/04/2013

Address for reprints: Dr. Roberto René Favaloro - Avenida Belgrano 1746 - (C1093ASS) CABA, Argentina - Tel. + 54 11 4383-9081
Fax: + 54 11 4378-1245 - e-mail: rfavaloro@ffavaloro.org - www.fundacionfavaloro.org

Department of Thoracic and Cardiovascular Surgery, Hospital Universitario Fundación Favaloro. Buenos Aires, Argentina.

^{MTSAC} Full Member of the Argentine Society of Cardiology

[†] To apply as Full Member of the Argentine Society of Cardiology

INTRODUCTION

The term "aortic valve-sparing operation" was first introduced at the early 1990s to describe procedures aiming to preserve the native aortic valve in patients with aortic root aneurysm with or without associated aortic insufficiency. (1-3)

Most patients with aortic root aneurysm require surgery mainly on account of the diameters at the aortic sinus level rather than for the aortic insufficiency. (4) In those patients with structurally normal aortic valve, the aortic valve-sparing operation offers the only possibility of preserving the native valve, removing during the same procedure the diseased aortic root tissue. Patients affected with Marfan syndrome benefit mostly from this surgical technique. (5)

The aortic valve-sparing operation captured the interest of surgeons and cardiologists due to the known limitations of prosthetic valves. (4) On the one hand, mechanical prostheses require lifelong anticoagulation and present associated thromboembolic and hemorrhagic morbidity. On the other hand, biological prostheses are likely to require future reoperations. (5)

The main aim of the aortic valve-sparing operation has been the demonstration of a lower rate of major associated valve events compared with the Bentall De Bono surgery, which is the procedure of choice for the surgical treatment of the aortic root. (6)

There are two techniques to preserve the aortic valve. The first is the remodeling technique described by Yacoub et al. (7), where the aortic root is replaced with a Dacron graft starting at the supra-annular level, without involving the aortic annulus. The second is the reimplantation technique described by David and Feindel (1) which replaces the aortic root with a Dacron graft starting at the subannular level, thus involving the aortic annulus. (8, 9) During long-term follow-up, the reimplantation technique has shown greater stability of the aortic valve function than the remodeling technique, especially in patients with dilation of the aortic annulus. The main reason for failure of the remodeling technique is the progressive dilation of the aortic root and annulus. Therefore, the remodeling technique is recommended only in elderly patients with aortic root aneurysm and normal aortic annulus. (4, 10)

The aim of our study was to analyze the 13-year experience in aortic valve-sparing operation with reimplantation technique at the Hospital Universitario Fundación Favaloro.

METHODS

Patients

Sixty-six patients underwent consecutive aortic valve-sparing operation at our institution from July 1998 to December 2011. The study included 53 patients who underwent the reimplantation technique operation and excluded 13 patients operated on with the remodeling technique.

Preoperative and operative echocardiographic evaluation

Prior to surgery, cardiac color Doppler transthoracic echo-

cardiography was performed, using 1500, 2500, 5500 and 7500 (Hewlett Packard), Vivid 7 (General Electric) and IE33 (Philips) ultrasound machines, to assess aortic root, ascending aorta and aortic arch dimensions, and evaluate aortic valve morphology and function. Aortic insufficiency was graded as 0: absent; 1+: mild; 2+: moderate; 3+: moderate-severe, and 4+: severe. (11, 12) Biventricular function and morphology and function of the other cardiac valves were also analyzed.

In addition, angiotomography was performed to all patients to assess aortic root, ascending aorta and aortic arch dimensions, and cinecoronariography or coronary multislice computed tomography to evaluate the coronary anatomy.

In the operating room, patients were evaluated with cardiac color Doppler transthoracic echocardiography after aortic valve-sparing operation to assess aortic valve function, valve coaptation surface, neo-aortic root dimensions (aortic annulus, sinusoidal level, sinotubular junction and tubular level), and biventricular function.

Surgical technique

Surgery was performed by median sternotomy with extracorporeal circulation using membrane oxygenators and moderate hypothermia. Myocardial protection was achieved by cold antegrade and retrograde blood cardioplegia. Deep hypothermia was used only in case of circulatory arrest for aortic arch replacement.

The reimplantation technique was used in the 53 patients included in this study, with 3 different variations: Tirone David I (16 patients) which uses a Dacron graft 2-4 mm larger than the aortic annulus internal diameter; Tirone David V (28 patients) which employs a Dacron graft 6-8 mm larger than the aortic annulus internal diameter, matching the annulus size with that corresponding to the patient's body surface area, followed by creation of Valsalva pseudosinuses with diameter similar to that of the aortic annulus; and Tirone David V with Stanford modification (9 patients), in which another 22-24 mm Dacron graft is used distal to the sinotubular junction of the Dacron graft (1, 9, 13-15). Prolapse of one or more cusps was verified in 6 patients after aortic root reconstruction and corrected with plication.

Clinical and echocardiographic follow-up

Clinical and echocardiographic follow-up was managed by in-office or telephone visits between the third and sixth postoperative month and henceforth, annually. Echocardiographic evaluation included a detailed morphological and functional analysis of the aortic valve. The severity of regurgitation was classified as previously described

Statistical analysis

Continuous variables are expressed as mean \pm standard deviation or median. Dichotomous variables are presented as integers or percentages.

Survival, freedom from aortic insufficiency > 2+ and freedom from reoperation were estimated with the Kaplan-Meier method and strength of association between exposures and events was estimated by means of the raw risk ratio (RR) and its 95% confidence interval (CI). A multivariate logistic regression model with retrograde elimination was designed to establish independent predictors of late events. A two-tailed p value < 0.05 was considered as statistically significant.

Ethics

All patients signed an informed consent form to carry out

the surgical procedure.

The present study was approved by the Teaching and Research Department of the Hospital Universitario Fundación Favaloro.

RESULTS

Population characteristics

Mean age was 45 ± 17 years and 79% of patients were men. Thirty-six percent of patients had diagnosis of Marfan syndrome, 17% of aortic dissection and 8% had bicuspid aortic valve. Grade 3+ and 4+ aortic insufficiency was observed in 43% of cases (Table 1).

Aortic valve-sparing operation

Aortic cross-clamping time was 158 ± 32 min (range: 64-220 min) and extracorporeal circulation time was 186 ± 35 min (range: 116-260 min). Surgery was performed under moderate hypothermia (mean temperature: 28 ± 2 °C) in all cases except in 16 patients who required circulatory arrest (mean time: 28 ± 7 min, range: 18-37 min and mean temperature: 14 ± 2 °C, range 12-18 °C). The preoperative aortic annulus measured in the surgical room was 29 ± 2 mm and the postoperative annulus was 24 ± 1 mm. Median Dacron graft size was 32 mm. Intraoperative transesophageal echocardiography revealed grade 0 aortic insufficiency in 68% of cases and grade 1 + in the remaining 32%.

Aortic valve-sparing operation was performed as combined procedure in 45% of patients (Table 2).

In-hospital outcome

The following complications were observed during the postoperative period: reoperation for bleeding in 7 patients (4 with combination procedure and 2 with deep hypothermia and circulatory arrest) and for cardiac tamponade in 3 patients (2 with combination procedures and 1 with deep hypothermia and circulatory arrest), low cardiac output syndrome requiring intra-aortic balloon pump counterpulsation in 2 patients, acute renal failure in 3 patients with need for dialysis in one patient, mediastinitis in 1 patient, and definitive pacemaker implantation in 2 patients.

In-hospital mortality was 3.8% (2 patients): one patient died due to intestinal necrosis in the third postoperative day and the other patient due to septic shock during the late postoperative interval (day 50):

Long-term follow-up

Mean follow-up interval was 4.7 ± 2.8 years and was complete in 98% of the study population.

Overall survival at 8-years was 91% (95% CI: 78-97%) (Figure 1). Late mortality was 3.8% (2 patients), both for non-cardiac causes: one patient died due to renal cancer three years after the aortic-valve sparing operation and the other patient due to pneumonia four years after surgery.

During echocardiographic follow-up, aortic insufficiency > 2+ was observed in 7 patients, 6 of which

Table 1. Population characteristics

	n (%) or mean \pm SD (range)
Number of patients	53
Age, years	45 ± 17 (17-77)
Male gender	42 (79)
Cardiovascular risk factors:	
- Hypertension	23 (43)
- Diabetes	2 (4)
- Dyslipidemia.	9 (17)
- Current smoking	4 (8)
Marfan syndrome	19 (36)
Bicuspid aortic valve	4 (8)
Aortic dissection:	9 (17)
- Acute	4 (8)
- Chronic	5 (9)
NYHA functional class:	
- I	12 (23)
- II	11 (21)
- III	3 (6)
- IV	2 (4)
Coronary disease	8 (15)
Reoperation	2 (4)
Left ventricular ejection fraction	57 ± 9 (28-79)
- > 55%	41 (77)
- 45-55%	6 (11)
- 35-45%	4 (8)
- < 35%	2 (4)
Aortic insufficiency, grades:	
- Absent, grade 0.	10 (19)
- Mild, grade 1+.	13 (25)
- Moderate, grade 2+.	7 (13)
- Moderate – Severe, grade 3+.	6 (11)
- Severe, grade 4+.	17 (32)
Aortic root diameters:	
- Aortic annulus	24 ± 4 (17 -32)
- Valsalva sinuses	48 ± 9 (24 -75)
- Sinotubular junction	44 ± 10 (27 - 74)
- Tubular ascending aorta	44 ± 13 (22 - 81)
Aortic arch diameters	30 ± 10 (18 - 46)
Urgencies / Emergencies	2 (4) - 3 (6)
EuroSCORE	6.17 ± 1.73 (5 - 12)

SD: Standard deviation. NYHA: New York Heart Association.

required reoperation: aortic valve replacement with mechanical prosthesis in 4 patients, Bentall De Bono surgery in 1 patient and cardio-renal transplantation in 1 patient for associated valve cardiomyopathy and chronic renal failure.

Freedom from aortic insufficiency > 2+ and freedom from reoperation at 8 years were 84% (95% CI: 66-92%) (Figure 2) and 90% (95% CI: 74-96%) (Figure 3), respectively.

In our series, presence of preoperative aortic insufficiency > 2+ was neither associated with the development of aortic insufficiency > 2+ (RR 1.45, p = 0.16) nor with the need for reoperation (RR 1.96, p = 0.4) during the long-term follow-up.

A multivariate logistic regression model with retrograde elimination was designed for the composite of all-cause mortality and aortic insufficiency > 2+ at follow-up, revealing non-significant strength of as-

sociation with age ≥ 60 years (OR 3.71, p = 0.12) and urgent or emergency surgeries (OR 4.6, p = 0.14) (Table 3).

No thromboembolic events, bleeding episodes or infectious myocarditis were observed during the long-term follow-up.

DISCUSSION

The development of the aortic valve-sparing operation represents a progress in the treatment of aortic root disease. The most significant benefit of this type of

Table 2. Combined procedures

Procedure	n (%)
Aortic arch replacement	5 (9)
Aortic arch replacement + Elephant trunk	5 (9)
Myocardial revascularization surgery	5 (9)
Mitral valve repair + Patent foramen ovale closure	3 (6)
Aortic arch replacement + Myocardial revascularization surgery	1 (2)
Aortic arch replacement + Myocardial revascularization surgery + Mitral valve repair	1 (2)
Aortic arch replacement + Elephant trunk + Myocardial revascularization surgery	1 (2)
Mitral valve replacement	1 (2)
Mitral valve repair + Left atrial appendage exclusion	1 (2)
Closure of interatrial communication	1 (2)

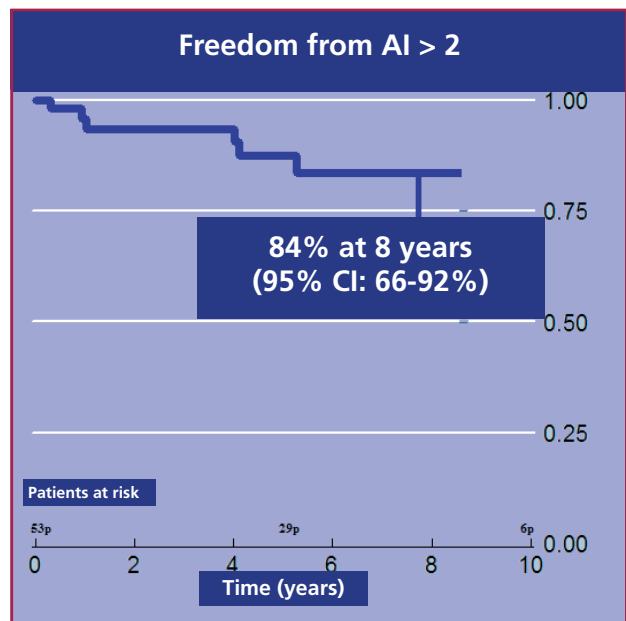


Fig. 2. Freedom from aortic insufficiency (AI) > 2+

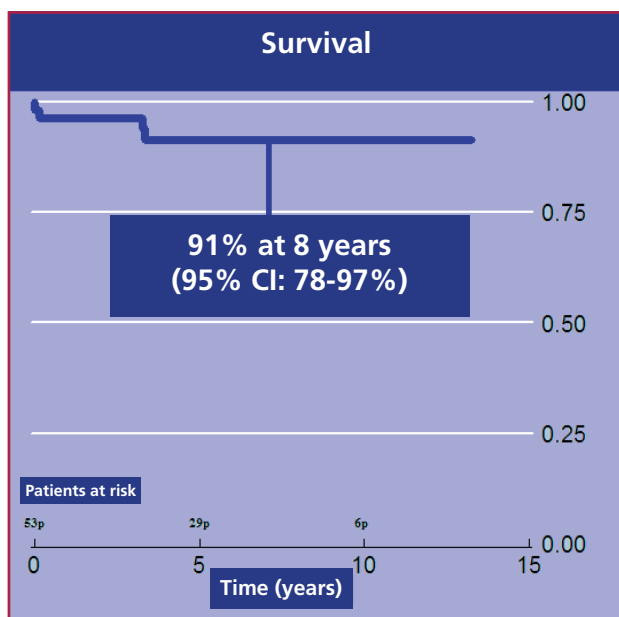


Fig. 1. Overall survival

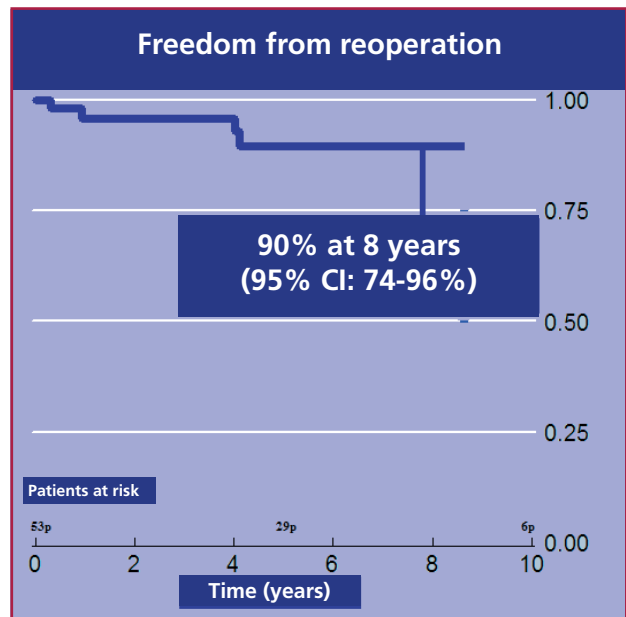


Fig. 3. Freedom from reoperation.

surgery is the prevention of problems associated with valvular prostheses. (5, 6) Franke et al. demonstrated the superiority of the aortic valve-sparing operation in patient quality of life, compared with the Bentall De Bono surgery. (16)

Many authors have reported low in-hospital mortality rates for the aortic valve-sparing operation and excellent long-term survival. (10, 17-20) In the David et al. series, long-term overall survival following the aortic valve-sparing operation was $93 \pm 4.4\%$ at 10 years. (4, 20) Similar to these results, overall survival reported in our study was 91% at 8 years (95% CI: 78-97%).

Essentially, the most important point to establish is the durability of this surgical technique. Freedom from reoperation is low in most reports. (4, 10, 20-23) The David et al. series showed excellent results in this respect, with $98 \pm 5.3\%$ freedom from aortic valve reoperation at 10 years. (20) In the present study, freedom from reoperation at 8 years was 90% (95% CI: 74-96%), similar to the meta-analysis of Benedetto and Takkenberg (24) who observed an aortic valve reintervention rate of 1.3%/year and to the Hanover series who reported 87% freedom from reintervention at 8 years. (25) In our experience, results are superior with the aortic valve-sparing operation compared with the durability reported for biological aortic prostheses. (26-31)

However, as aortic insufficiency is well tolerated, the reoperation rate could underestimate the surgical technique failure rate. (4) As demonstration of the durability of this surgical approach, we reported 84% (95% CI: 66-92%) freedom from aortic insufficiency $> 2+$ at 8 years, while Davis et al. found $93 \pm 6.5\%$ freedom from moderate or severe aortic insufficiency at 10 years in their series of patients. (20)

The meta-analysis published by Benedetto and Takkenberg (24) comparing the Bentall De Bono surgery versus the aortic valve-sparing operation results in Marfan syndrome patients established that the rate of thromboembolic events was significantly greater in the Bentall De Bono surgery group. Conversely, the aortic valve-sparing operation group showed greater need for reoperation during follow-up, though no significant differences were found in the rate of associated valve events between both groups. The authors concluded that the aortic valve-sparing operation represents a valid option for Marfan syndrome patients with aortic root aneurysm. However, this technique should be used with caution in patients with at risk valve characteristics, due to lower durability of the technique. Therefore, it is vital to correctly select patients who will most benefit from this surgical approach.

As shown in different studies (1, 24, 32) and established by David et al., this surgical procedure is demanding, needs an important learning curve and should only be performed by surgeons with ample experience in aortic surgery. (4)

“The Aortic Valve Operative Outcomes in Marfan Patients Study Group” published early results comparing the aortic valve-sparing operation and the Bentall De Bono surgery (32), and concluded that despite the need for more prolonged aortic cross-clamping and extracorporeal circulation times in the aortic valve-sparing operation, there were no significant differences in postoperative complications between both groups. Thus, the greater technical complexity of the aortic valve-sparing operation did not translate into any demonstrable early adverse result. The same group recently published the results at one year, (33) without significant differences in survival and major valve-

Table 3. Univariate and multivariate analyses

A. Univariate analysis

Preoperative variables	Overall mortality		Aortic insufficiency ≥ 2		Composite of overall mortality / aortic insufficiency ≥ 2	
	OR	p	OR	p	OR	p
Age > 60 years	5.12	0.09	1.90	0.48	3.42	0.09
Aortic dissection	6.00	0.06	0.83	0.19	1.11	0.90
FC III-IV dyspnea	3.75	0.28	1.75	0.63	2.88	0.26
EF < 45%	0.83	0.50	1.75	0.63	0.95	0.96
Urgency / Emergency	15.3	0.03	0.85	0.35	2.88	0.26
Combined surgery	1.33	0.78	0.97	0.97	1.11	0.87
ECC time > 200 min	1.02	0.98	1.27	0.78	1.2	0.81

OR: Odds ratio. FC: Functional class. EF: Ejection fraction. ECC: Extracorporeal circulation.

A. Univariate analysis

Variables	Composite of overall mortality / aortic insufficiency ≥ 2		
	OR	p	p
Age > 60 years	3.71	0.12	0.69 - 19.7
Urgency / Emergency	4.60	0.14	0.60 - 35.0
FC III-IV dyspnea	1.99	0.53	0.23 - 17.1

OR: Odds ratio. CI: Confidence interval. FC: Functional class.

associated events between both groups of patients. However, the aortic valve-sparing operation group increased the development of aortic insufficiency $> 2+$, not observed in the Bentall De Bono surgery group. Based on the international literature and in our experience, we currently consider that ideal candidates for this procedure are patients under 55 years of age, with EF $> 50\%$, mild or negligible aortic insufficiency, and without need for any other associated procedure. The final decision is taken in the operating room, after cusp examination, and at this point, patients with freedom from multiple, central or large fenestrations and freedom from calcification are selected. However, in patients with adequate cusps and higher than mild aortic insufficiency either of a tricuspid or bicuspid valve, we have performed the procedure successfully. Finally, in acute type A dissection, this procedure is feasible in correctly selected cases

Limitations

As in most retrospective studies, the present work has some limitations. The first limitation is that, since many patients live in the interior of the country, we have been able to contact 98% of the population. The second limitation is that, for the same reason, many patients have been evaluated by their personal cardiologist during follow-up and our analysis has been based on their reports, which could involve an interobserver bias. Considering both limitations, some late events may not have been taken into account in the final analysis. Finally, considering the sample size, there is a limitation to detect outcome predictors.

CONCLUSIONS

In our experience, the aortic valve-sparing operation with reimplantation technique in patients with aortic root disease shows results comparable to other international published series. This surgical technique is a valid option for selected patients, duly informed about the different surgical techniques and should be performed in experienced centers.

Conflicts of interest

None declared.

Acknowledgement

To the Echocardiography Division: Dr. C. Rodríguez Correa, Dr. E. Guevara, Dr. F. Salmo, Dr. G. Ganum y Dr. M. Cerda.

REFERENCES

- David TE, Feindel CM. An aortic valve-sparing operation for patients with aortic incompetence and aneurysm of the ascending aorta. *J Thorac Cardiovasc Surg* 1992;103:617-21.
- David TE, Feindel CM, Bos J. Repair of the aortic valve in patients with aortic insufficiency and aortic root aneurysm. *J Thorac Cardiovasc Surg* 1995;109:345-52. <http://doi.org/fjsbcj>
- Fazel SS, David TE. Aortic valve-sparing operations for aortic root and ascending aortic aneurysms. *Curr Opin Cardiol* 2007;22:497-503. <http://doi.org/dmhwwz>
- David TE, Feindel CM, Webb GD, Colman JM, Armstrong S, Maganti M. Long-term results of aortic valve-sparing operations for aortic root aneurysm. *J Thorac Cardiovasc Surg* 2006;132:347-54. <http://doi.org/bxqdx4>
- Feindel CM, David TE. Aortic valve-sparing operations: basic concepts. *Int J Cardiol* 2004;97:61-6. <http://doi.org/ct6dcr>
- Miller C. Valve-sparing aortic root replacement: Current state of the art and where are we headed? *Ann Thorac Surg* 2007;83:S736-9. <http://doi.org/cjpfvc>
- Fagan A, Pillai R, Radley-Smith R, Yacoub MH. Results of new valve conserving operation for treatment of aneurysms or acute dissection of aortic root. *Br Heart J* 1983;49:302.
- Erasmí AW, Sievers HH, Bechtel JFM, Hanke T, Stierle U, Misfield M. Remodeling or reimplantation for valve-sparing aortic root surgery? *Ann Thorac Surg* 2007;83:S752-6. <http://doi.org/dxd67x>
- David TE. The aortic valve-sparing operation. *J Thorac Cardiovasc Surg* 2011;141:613-5. <http://doi.org/b8p8m8h>
- David TE, Armstrong S, Maganti M. Aortic root aneurysm: principles of repair and long-term follow up. *J Thorac Cardiovasc Surg* 2010;140:S14-9. <http://doi.org/ckgms9>
- Zoghbi WA, Enriquez-Sarano M, Foster E. Recommendations for evaluation of the severity of native valvular regurgitation with two-dimensional and Doppler echocardiography. *J Am Soc Echocardiogr* 2003;16:777-802. <http://doi.org/bvj6vj>
- Gomez CB, Stutzbach PG, Guevara E, Favaloro RR. Does intraoperative transesophageal echocardiography predict pulmonary valve dysfunction during the Ross procedure? *J Cardiothorac Vasc Anesth* 2002;16:437-40. <http://doi.org/bzkfcx>
- Miller DC. Valve-sparing aortic root replacement in patients with Marfan syndrome. *J Thorac Cardiovasc Surg* 2003;125:773-8. <http://doi.org/b5q43c>
- de Oliveira NC, David TE, Ivanov J, Armstrong S, Eriksson MJ, Rakowski H, et al. Results for surgery for aortic root aneurysm in patients with Marfan syndrome. *J Thorac Cardiovasc Surg* 2002;125:796-8.
- Demers P, Miller DC. Simple modification of "T. David-V" valve-sparing aortic root replacement to create graft pseudo-sinuses. *Ann Thorac Surg* 2004;78:479-81. <http://doi.org/db6kbc>
- Franke UF, Isecke A, Nagib R, Breuer M, Wippermann J, Tigges-Limmer K, et al. Quality of life after aortic root surgery: reimplantation technique versus composite replacement. *Ann Thorac Surg* 2010;90:1869-75. <http://doi.org/dpf2wb>
- David TE, Ivanov J, Armstrong S, Feindel CM, Webb GD. Aortic valve-sparing operations in patients with aneurysms of the aortic root or ascending aorta. *Ann Thorac Surg* 2002;74:S1758-61. <http://doi.org/fh5twb>
- Erasmí AW, Stierle U, Bechtel JF, Schmidtke C, Sievers HH, Kraatz EG. Up to 7 years' experience with valve-sparing aortic root remodeling/reimplantation for acute type A dissection. *Ann Thorac Surg* 2003;76:99-104. <http://doi.org/cpbrqt>
- Leyh RG, Schmidtke C, Bartels C, Sievers HH. Valve-sparing aortic root replacement (remodeling/reimplantation) in acute type A dissection. *Ann Thorac Surg* 2000;70:21-4. <http://doi.org/dhvjvs>
- David TE. Lecture at the Aortic Symposium, American Association for Thoracic Surgery. 26-27 April 2012, New York City. Available at <http://webcast.aats.org/2012-Aortic-Symposium/>
- Bethea BT, Fitton TP, Alejo DE, Barreiro CJ, Cattaneo SM, Dietz HC, et al. Results of aortic valve-sparing operations: experience with remodeling and reimplantation procedures in 65 patients. *Ann Thorac Surg*. 2004;78:767-72. <http://doi.org/dmp6vd>
- Yacoub MH, Gehle P, Chandrasekaran V, Birks EJ, Child A, Radley-Smith R. Late results of a valve-preserving operation in patients with aneurysms of the ascending aorta and root. *J Thorac Cardiovasc Surg* 1998;115:1080-90. <http://doi.org/b2vt3z>
- Aicher D, Langer F, Kissinger A, Lausber H, Fries R, Schafers HJ. Valve-sparing aortic root replacement in bicuspid aortic valves: a reasonable option? *J Thorac Cardiovasc Surg* 2004;128:662-8. <http://doi.org/fsx3t5>
- Benedetto U, Melina G, Takkenberg JJM, Roscitano A, Angeolai E, Sinatra R. Surgical management of aortic root disease in

- Marfan syndrome: a systematic review and meta-analysis. *Heart* 2011;97:955-8. <http://doi.org/b5xdx9>
25. Shrestha M, Baraki H, Maeding I, Fitzner S, SariKouch, Khaladj N, et al. Long-term results after aortic valve-sparing operation (David I). *Eur J Cardiothorac Surg* 2012;41:56-61.
26. Chan V, Mala T, Lapierre H, Boodwhani M, Lam B-K, Rubens Fraser D, et al. Reoperation of left heart valve bioprostheses according to age at implantation. *Circulation* 2011;124:S75-S80. <http://doi.org/dj7jf8>
27. Jamieson WR, Riess FC, Raudkivi PJ, Metras J, Busse EF, Goldstein J, et al. Medtronic Mosaic porcine bioprosthesis: assessment of 12-year performance. *J Thorac Cardiovasc Surg* 2011;142:302-7. <http://doi.org/ct28jh>
28. Mykén PS. Seventeen-year experience with the St. Jude medical bicor porcine bioprosthesis. *J Heart Valve Dis* 2005;14:486-92.
29. Jamieson WR, Burr LH, Munro AI, Miyagishima RT. Carpentier-Edwards standard porcine bioprosthesis: a 21-year experience. *Ann Thorac Surg* 1998;66:S40-3. <http://doi.org/brgqqg>
30. Bach DS, Metras J, Doty JR, Yun KL, Dumesnil JG, Kon ND. Freedom from structural valve deterioration among patients aged < or = 60 years undergoing Freestyle stentless aortic valve replacement. *J Heart Valve Dis* 2007;16:649-56.
31. Takkenberg JJ, Klieverik LM, Bekkers JA, Kappetein AP, Roos JW, Eijkemans MJ, Bogers AJ. Allografts for aortic valve or root replacement: insights from an 18-year single-center prospective follow-up study. *Eur J Cardiothorac Surg* 2007;31:851-9. <http://doi.org/c47m88>
32. Volguina IV, Miller DC, LeMaire SA, Palmero LC, Wang XL, Connolly HM, et al and Aortic Valve Operative Outcomes in Marfan Patients study group. Valve-sparing and valve-replacing techniques for aortic root replacement in patients with Marfan syndrome: Analysis of early outcome. *J Thorac Cardiovasc Surg* 2009;137:1124-32. <http://doi.org/crdhfb>
33. Coselli JS, Volguina IV, LeMaire SA, Sundt Thoralf M, Stephens EH, Vricella LA, et al. Early and One-Year Outcomes of Aortic Root Surgery in Marfan Syndrome Patients: A Prospective Multi-Center Comparative Study presented at AATS Annual Meeting 2013 Minneapolis