

artículo original

Adjuvant Hyperbaric Oxygen and ozone therapy in the treatment of chronic leg and foot ulcers (pilot clinical study)

Ahmed M. Fathi

General and Peripheral Vascular Surgeon, Oxytherapist , Egyptian Naval Medical Services,
(Alexandria, Egypt.)

M.Nabil.Mawsouf

Professor of Pain Management, Head of Ozone Therapy Unit, National Cancer Institute,
Cairo University,
(Cairo, Egypt)

Keywords

Hyperbaric oxygen therapy
Ozone therapy
Leg ulcers
Foot ulcers

Abstract

This pilot study describes the clinical effects of Adjunctive Hyperbaric Oxygen Therapy (HBOT) and Ozone Therapy in the treatment of chronic ulcers most of which did not respond to standard wound care and conventional methods of therapy and the patients were threatened by amputation. HBO and Ozone Therapy increased the healing rate of these ulcers, and avoided amputation. Adjuvant HBO and Ozone Therapy showed effective adjunctive therapy and we recommend a Randomized Controlled Trial to prove that effect.

Sugerencia sobre cómo citar este artículo: Ahmed M. Fathi, M.Nabil.Mawsouf(2011).

Adjuvant Hyperbaric Oxigen and ozone therapy in the treatment of chonic leg and foot ulcers. *Revista Española de Ozonoterapia*. Vol.1, nº 1, pp. 44-53.

Introduction

Leg ulcers are a common problem thought to affect about 1% of the population at some point in their lives and about 1.5 per 1000 people at any one time. Leg ulcers are more common in women than men, and the prevalence increases with age. Venous disease is present in the majority of cases; peripheral vascular disease may coexist or may be the main cause of an ulcer. Other disease processes may also be involved, such as diabetes or rheumatoid disease. Leg ulceration is chronic, and an ulcer may be present for months or years without healing. After healing, recurrence rates are high. There are many approaches to management, with large variations in practice at local and international levels. ⁽¹⁾

Hyperbaric Medicine is the fascinating use of barometric pressure for delivering increased oxygen dissolved in plasma to body tissues. Hyperbaric oxygen therapy (HBOT) is a form of treatment in which a patient breathes 100% oxygen at higher than normal atmospheric pressure that is greater than 1 atmosphere absolute (ATA). Therapy is given in special therapeutic chambers, which were earlier used primarily to treat illnesses of deep sea divers. ^(2, 3, 4)

Ozone (O₃) is a strong antioxidant.⁽⁵⁾ Ozone can exert protective effects by oxidative preconditioning, stimulating and/or preserving the endogenous antioxidant systems and by blocking the xanthine / xanthine oxidase pathway for reactive oxygen species generation, as demonstrated in studies of the damage induced by carbontetrachloride (CCL₄) or by hepatic and renal ischemia-reperfusion. ^(6, 7, 8, 9)

Ozone has been used with good results in the treatment of patients with diabetic foot, because of its germicidal properties and its influence on the processes of oxygen metabolism, and other effects. ⁽¹⁰⁾

Aim of the Work

The present pilot study aims to clinically evaluate the effectiveness of two different modalities of Oxy-Therapy; Hyperbaric Oxygen and Ozone Therapy in the treatment of chronic ulcers.

Patients and Methods

Patients:

This pilot study represents experience in the management of 15 cases, who had clinically diagnosed leg or foot ulcer, treated throughout the period between 2007 and 2008.

Patients were grouped into three different groups according to the severity of the case and treatment modality; Hyperbaric Oxygen Therapy; 5 patients; Ozone Therapy; 5 patients; and Combined Modality Therapy, 5 patients

Methods:

Diagnosis/Assessment; medical history, physical examination, ulcer examination, clinical investigations, ankle brachial pressure index (ABPI), investigations to exclude other causes, wound measurement, identifying hard-to-heal ulcers.

Management of wounds: the general rules to treat wounds include the accurate diagnosis and classification of the Wound, the vascular Status (ABPI), good control of blood glucose, correction of underlying cause, correction of malnutrition, treatment of Infection, debridement: of necrotic tissue and underlying osteomyelitis, obliteration of dead space as a result of debridement, off-loading, wound care, and finally adjuvant therapy ⁽¹¹⁾.

Hyperbaric Oxygen Therapy: Following the protocol adapted by Jain KK ⁽¹²⁾, sessions was done in the Multiplace Baramed 6/2/6 Hyperbaric Chambers, ETC Inc., USA. Oxygen was inhaled from a helmet or a mask at a pressure of: 2- 2.5 ATA (atmospheric pressure, equals 10 - 15 meters under Sea Surface).

Sessions were initially done on daily basis (6 sessions/ week). Intermittent, each session will be 90- 120 minutes, with rest every 20 sessions. The first clinical evaluation was done after 5 sessions.

Ozone Therapy: Following the protocol adapted by Renate Viebahn-Hänsler (2007) ⁽¹³⁾, patients to be treated daily with ozone (generated by an ozone generator, Ozonosan Alpha 1, Germany), by rectal insufflation as systemic therapy (with an ozone concentration up to 35 µg), and local treatment by covering the lesion by a plastic bag, filled with ozone at a concentration of 60 µg, decreased up to 20). The first clinical evaluation was done after 5 sessions. With improvement, the frequency of sessions was decreased gradually.

Combined: The combined modality was achieved by systemic HBOT and Local O₃ as described above. For local treatment; Standard wound care, topical application of ozonated olive oil and wound dressing.

Results

Ten patients (66.7%) had type 2 diabetes mellitus of them 8 (53.3%) were IDDM. The mean age was 53.3 ± 9.86 years (37- 68 years). The sex distribution was 10 males (66.7%) and 5 females (33.3%), with a ratio of 2:1. In addition, 10 patients (66.7%) were threatened by amputation. The main data of the studied patients is shown in table 1.

Table (1): Clinical Data of the Studied Patients

Modality	Age	Sex	Diabetes	Diagnosis	Threat of Amputation
HBOT					
Case 1	66	Male	IDDM	Rt Arterial Leg Ulcer	Yes
Case 2	52	Female	IDDM	Lt Neuropathic Foot Ulcer	Yes
Case 3	38	Male	No DM	Lt Recurrent Venous Ulcer	No
Case 4	50	Female	IDDM	Rt Neuropathic Foot Ulcer	Yes
Case 5	46	Male	No DM	Lt Venous Ulcer	No
O₃					
Case 1	65	Male	IDDM	Rt Neuropathic Foot Ulcer-Diabetic gangrene	Yes
Case 2	55	Male	IDDM	Rt Neuropathic Foot Ulcer	Yes
Case 3	37	Male	No DM	Lt Recurrent Venous Ulcer	No
Case 4	54	Male	No DM	Bilateral Venous-Traumatic Ulcers	No
Case 5	60	Female	NIDDM	Rt Neuropathic Foot Ulcer	No
HBOT: O₃					
Case 1	62	Male	IDDM	Neuropathic Foot Ulcer-Diabetic gangrene	Yes
Case 2	41	Male	No DM	Bilateral Venous-Traumatic Ulcers	Yes
Case 3	55	Female	IDDM	Lt Arterial Ulcer Heel	Yes
Case 4	68	Male	NIDDM	Lt Arterial Ulcer Heel	Yes
Case 5	51	Female	IDDM	Neuropathic Foot Ulcer-Diabetic gangrene	Yes

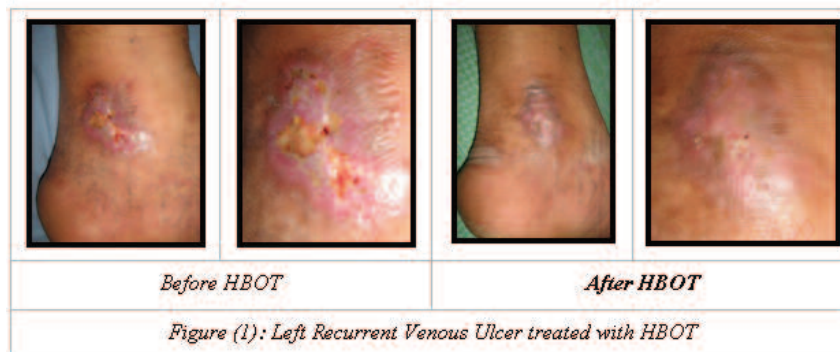Outcome

Successful results were achieved in 11 (73.3%) out of the studied 15 patients. The most effective modalities were combined modality 4 out of 5 (80%), the ozone therapy 4 out of 5 (80%), the HBOT 3 out of 5 (60%). Considering the severity of cases, combined modality was the most effective but with more selection of cases which suffered more from ischemia, infection and/or edema. Ozone therapy was very effective, easier to apply with less complication and higher patient compliance.

A striking feature was that out of the 10 patients threatened by amputation, seven (70%) patients had their limbs saved.

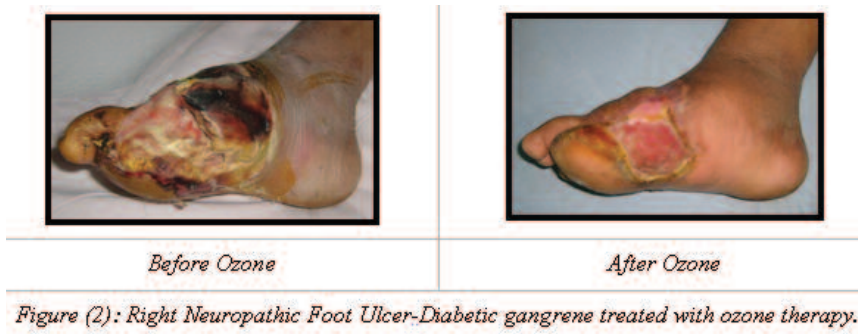Clinical case treated with HBOT:

Male, 38 yrs, smoker not diabetic. complaining of recurrent left leg ulcer since 1 month provoked by Trauma, then infected wound, gradually increased in size. Similar ulcer developed in the same place since 10 years and lasted for 3 Years. (Figure 1)



Clinical case treated with ozone therapy:

A 65 years male IDDM patient was diagnosed as Rt diabetic foot gangrene; Wagner 4 classification. The main problem was diabetic foot, Infection and neuropathy. He was recommended for Right below knee amputation. He was unfit for HBOT because of his heart problem. He received ozone therapy daily (Topical 80→60 $\mu\text{g}/\text{ml}$) and rectal insufflation 15 – 35 $\mu\text{g}/\text{ml}$ 250 – 300 ml for 5 days followed by surgical debridement. Ozone therapy continued 3 sessions / week for seven weeks then twice / week for four weeks and finally once / week for 12 weeks. This was followed by using ozonated olive oil only. The maximum concentration for rectal insufflation was 35 $\mu\text{g}/\text{ml}$ and the volume was 300 ml. Topical ozone concentration dropped gradually from 80 $\mu\text{g}/\text{ml}$ till 20 $\mu\text{g}/\text{ml}$. (Figures 2, 3)



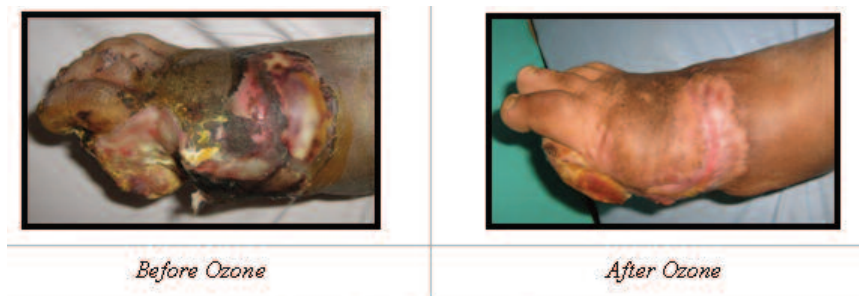


Figure (3): Same case other view.

Clinical cases treated with combined HBOT and ozone therapy:

A 55 years female patient with uncontrolled IDDM and ulcer of the left heel. She was suffering from pains of the left leg and foot. She passed serial debridements and unfit for re-vascularization. She was planned for below knee amputation. There was complete occlusion of tibialis posterior artery and occluded segments of tibialis anterior and superficial safenous arteries. There was left leg ischemia (ABPI 0.65), severe diabetic foot infection, gangrenous arterial Ulcer of the Heel. The surgical decision was to control diabetes, ischemia, and infection. This to be followed by debridement, grafting (plastic surgery) and proper foot wear. The oxy-therapy protocol was to start with HBOT till control of ischemia and infection by 20 sessions daily; 6 days / week. This is to be followed by topical ozone three sessions / week (60 $\mu\text{g}/\text{ml}$) till wound is clean; then three sessions / week (40 \rightarrow 20 $\mu\text{g}/\text{ml}$) to promote healing. The total therapy was 23 sessions HBOT and 37 sessions topical ozone in a four month period. (Figure 4)

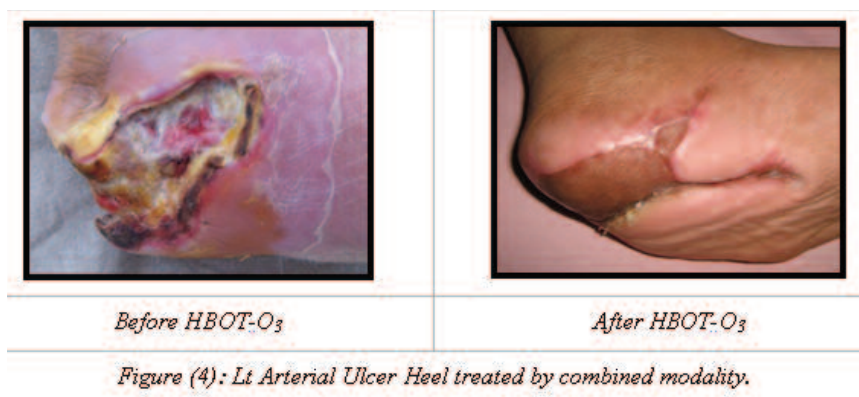
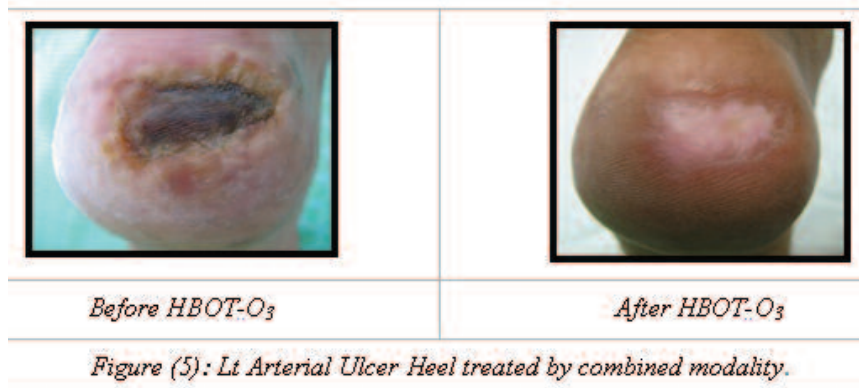


Figure (4): Lt Arterial Ulcer Heel treated by combined modality.

Another case of 68 years male, NIDDM, smoker with severe pains of the left leg and foot. He suffered from intermittent claudications and was unfit for revascularization. There was a pressure ulcer of the left heel and left superficial safenous artery occlusion. (Figure 5)



Discussion

HBO promotes wound healing by counteracting tissue hypoxia and is a valuable adjunct in management of ischemic, infected, and non-healing wounds. ⁽¹²⁾ It is generally accepted that correction of wound-hypoxia is required to provide enough O₂ that would support growth of regenerating tissues. ⁽¹⁴⁾

Rationale of HBO for ulcers based on the hypoxia theory has been a matter of controversy, between authors who do not recommend the use of HBOT in venous ulcers; reporting that the role of HBOT seems very limited, and that reported successful cases would heal without the need for HBO, ⁽¹⁵⁾ or reporting that it is difficult to justify such an expensive, ineffective, complication-prone treatment modality for problem extremity wounds. ⁽¹⁶⁾

Several studies reported favorable results in treating venous ulcers with HBO. ^(17, 18) Specifically, two Double-Blind, Randomized-controlled studies; the first has significantly demonstrated an improvement in venous stasis ulcers that showed no response to standard wound care. ⁽¹⁹⁾ The second concluded that hyperbaric oxygen enhanced the healing of ischemic, non-healing diabetic leg ulcers and may be used as a valuable adjunct to conventional therapy when reconstructive surgery is not possible. ⁽²⁰⁾

On the other hand, authors supporting its use only in extraordinary circumstances as a useful adjunct in the treatment of some life- or limb-threatening situations where it can be cost effective. ⁽²¹⁾ Also, Jain et al, 2004 reported that HBO will remain an important adjunct to wound healing but its role needs to be redefined. ⁽¹²⁾

Clinical comparison

HBO	Ozone
Selected cases (Systemic Only)	Most cases (Topical & Systemic)
Expensive	Less expensive
Less patient compliance	High patient compliance
Claustrophobia	No
Major Side Effects:	Side effects

oxygen toxicity	reversible minor skin irritation IF many high conc. sessions
decompression illness	respiratory irritation IF improper ozone generator is used
Complex	Ease & simple method
Cautious selection of patients	Applicable especially in high risk patients
Numerous contraindications	Less contraindications

Conclusions

Oxy-Therapy is a beneficial adjuvant therapy that:

- Accelerates the rate of wound healing,
- Preserves a functional extremity,
- Reduces the need for Amputation, and
- Increases the rate of complete healing of bad ulcers on long-term therapy

Ozone Therapy:

- Highly effective treatment of bad healing ulcers
- Improves some systemic disorders present in those patients
- Enhances the sense of wellbeing

Hyperbaric Oxygen Therapy:

- Valuable for treating Selected cases of diabetic foot complications and impaired wound-healing. (Hypoxic)

Combined Modality

- More beneficial in Selected cases (Hypoxia, infection, edema)
- Costly

Recommendations

From this pilot study we conclude that Adjuvant HBO and Ozone Therapy increased healing rates of chronic leg ulcers which did not respond to standard wound care and conventional methods of therapy, even in the presence of significant and severe co morbidities and challenges.

We also support many recommendations that the role of HBOT and Ozone Therapy should be redefined by good randomized controlled studies to improve the level of evidence supporting their use in the management of venous ulcers and the cost effectiveness of its use.

References

- 1- Wilkinson EA, Hawke CI. Does Oral Zinc Aid the Healing of Chronic Leg Ulcers? A Systematic Literature Review. *Arch Dermatol* 1998; 134: 1556- 1560.
- 2- Fife Caroline E, Buyukcakir C, Otto GH, et al (2002): The predictive value of transcutaneous oxygen tension measurement in diabetic lower extremity ulcers treated with HBOT. *Wound Repair and Generation* 2002; 10: 198- 207.
- 3- Bakker DJ (2000): Hyperbaric oxygen therapy and the diabetic foot. *Diab Metab Res Rev* 2000; 16: S55- S58.
- 4- Sahni T, Hukku S, Jain M, et al (2004): Recent Advances in Hyperbaric Oxygen Therapy. *Medicine Update* 2004; 14: 632- 639.
- 5- Bocci V (1999): Biological and clinical effects of ozone. Has ozone therapy a future in medicine? *Br J Biomedical Science* 1999; 56: 270- 279.
- 6- Leon OS, Menendez S, Merino N (1998): Ozone oxidative preconditioning: a protection against cellular damage by free radicals. *Mediat Inflamm* 1998; 7: 289- 294.
- 7- Barber Menendez S, Leon OS (1999): Prevention of renal injury after induction of ozone tolerance in rats submitted to warm ischemia. *Mediat Inflamm* 1999; 8: 37- 42.
- 8- Peralta C, Leon OS, Xaus C (1999): Protective effect of ozone treatment on the injury associated with hepatic ischemia-reperfusion: antioxidant-prooxidation balance. *Free Radic Res* 1999; 31: 191- 196.
- 9- Peralta C, Xaus C, Bartrons R (2000): Effect of ozone treatment on reactive oxygen species and adenosine production during hepatic ischemia-perfusion. *Free Radic Res* 2000; 33: 595- 605.
- 10- Martinez-Sanchez G, Al-Dalain SM, Menendez S, et al (2005): Therapeutic efficacy of ozone in patients with diabetic foot. *Eur J Pharmacology* 2005; 523: 151- 161.
- 11- Fathi AM, Mawsouf MN: Adjuvant HBO and ozone in diabetic foot and badly healing wounds. In proceedings European Cooperation of Medical Ozone Societies Congress, Baden Baden, Germany, November 2008.
- 12- Jain KK (ed). HBO Therapy in wound healing, plastic surgery, and dermatology. In: *Textbook of Hyperbaric Medicine*. Hogrefe & Huber Germany. 2004: 147- 166.
- 13- Renate Viebahn-Hänsler (ed.): *The use of ozone in medicine*. 5th English edition, Karl F. Hang Publishers, Heidelberg, Germany, 2007: 44, 60.
- 14- Gordillo GM, Sen CK. Revisiting the essential role of oxygen in wound healing. *The American Journal of Surgery* 2003; 186: 259– 263
- 15- Mathieu D, Linke JC, Wattel F. Non-Healing wounds. In: Mathieu D (ed): *Handbook on Hyperbaric Medicine*. Springer, The Netherlands. 2006: 400- 427.

- 16- Ciaravino ME, Friedell ML, Kammerlocher TC. Is Hyperbaric Oxygen a Useful Adjunct in the Management of Problem Lower Extremity Wounds?. *Annals of Vascular Surgery* 1996; 10: 558-562.
- 17- Perrins JD., Barr PO. Hyperbaric oxygenation and wound healing. In Schmutz J. (ed). *Proceedings of the 1st Swiss symposium on HBO*. Foundation for Hyperbaric Medicine, Basel. 1986 : 119-132.
- 18- Fischer BH. Treatment of ulcers on the legs with hyperbaric oxygen. *J Dermatol Surg.* 1975 ; 1 : 55-58.
- 19- Hammerlund C., Sundberg T. Hyperbaric oxygen reduced size of chronic leg ulcers: a randomized double-blind study. *Plast Reconstr Surg.* 1994 ; 93 : 829-833.
- 20- A. Abidia, G. Laden, G. Kuhan, et al. The Role of Hyperbaric Oxygen Therapy in Ischaemic Diabetic Lower Extremity Ulcers: a Double-blind Randomised-controlled Trial. *Eur J Vasc Endovasc Surg* 2003; 25: 513-518.
- 21- Roth RN and Weiss LD. Hyperbaric oxygen and wound healing. *Clinics in Dermatology* 1994; 12: 141-156.