

## Case report

---

# Ozone therapy for neuralgia-inducing cavitation osteonecrosis: case report

## Ozonoterapia para la inducción de osteonecrosis neuralgia: reporte de caso

**João Antonino Dias Gomes**

Esthetic Smile-Health Care Lda Morada, Melgaço, Portugal

**Ana Carolina de Carvalho Maciel**

Department of Endodontics, Fluminense Federal University, Niteroi, Rio de Janeiro, Brazil

**Ana Paula Anzolin**

Brazilian Society of Medical Ozone Therapy (SOBOM), São Paulo, Brazil

---

### Keywords

Ozone Therapy;  
Osteonecrosis; NICO;  
Neuropathic pain;  
Orofacial pain;  
Neuralgia induced by  
osteonecrotic  
cavitation..

---

### Abstract

---

*Introduction: Neuralgia-induced cavitation osteonecrosis of the jaw (NICO) is defined as a chronic pain syndrome, similar to trigeminal neuralgia. For the treatment of NICO, a curettage of the affected bone tissue is performed and, in this procedure, local infiltrations with antimicrobials and/or use of oral anticoagulants can be used, however, a pain reduction of only 50% of these observed conditions will be modified in patients. The present study aims to report a clinical case of NICO in the jaw and the benefits of using Ozone Therapy.*

*Methods: A 74-year-old male patient with neuropathic trigeminal pain and presenting areas of necrosis in the jaw. On the day of the curettage surgery, complete debridement and local irrigation with ozone was performed in the 4th quadrant region.*

*Result Discussion: The patient also received Ozone-induced Growth Factor Concentrates and finally a resorbable intraoral dressing was placed. On the day of surgery, the patient presented pain between 7 and 8 points, according to the visual pain scale (VPS). On the 4th postoperative day he was well, with 4 to 5 points on the VPS scale. The patient was asymptomatic after 30 days of follow-up and received an implant placement 90 days after the procedure for NICO. It is hypothesized that Ozone Therapy presents, as its possible mechanisms of action, tissue stimulation and oxygenation of the affected area, release of growth factors, and antimicrobial action. Therefore, Ozone Therapy has been considered beneficial and may become a possibility of adjuvant treatment for patients with NICO.*

---

## Palabras clave

Ozonoterapia;  
osteonecrosis;  
NICO; Dolor  
neuropático; dolor  
orofacial; Neuralgia  
inducida por  
cavitación  
osteonecrótica.

---

## Resumen

**Introducción:** La osteonecrosis cavitacional mandibular inducida por neuralgia (NICO) se define como un síndrome de dolor crónico, similar a la neuralgia del trigémino. Para el tratamiento de NICO se realiza un curetaje del tejido óseo afectado y, en este procedimiento, se pueden utilizar infiltraciones locales con antimicrobianos y/o uso de anticoagulantes orales, sin embargo, se logrará una reducción del dolor de solo el 50% de estas condiciones observadas. modificarse en los pacientes. El presente estudio tiene como objetivo reportar un caso clínico de NICO en la mandíbula y los beneficios del uso de la ozonoterapia.

**Métodos:** Paciente masculino de 74 años con dolor neuropático del trigémino y que presenta áreas de necrosis en la mandíbula. El día de la cirugía de curetaje se realizó desbridamiento completo e irrigación local con ozono en la región del 4° cuadrante.

**Resultados. Discusión:** El paciente también recibió concentrados de factores de crecimiento inducidos con ozono y finalmente se colocó un apósito intraoral reabsorbible. El día de la cirugía la paciente presentaba dolor entre 7 y 8 puntos, según la escala visual de dolor (EVD). Al 4° día postoperatorio se encuentra bien, con 4 a 5 puntos en la escala EVD. El paciente se encontraba asintomático a los 30 días de seguimiento y la colocación del implante a los 90 días del procedimiento de NICO. Se planteó la hipótesis de que la ozonoterapia, dado que sus posibles mecanismos de acción son la estimulación y oxigenación tisular del área afectada, liberación de factores de crecimiento y acción antimicrobiana, ha sido beneficiosa y puede convertirse en una posibilidad de tratamiento adyuvante para pacientes con NICO...

### Suggestion on how to quote this paper:

Dias Gomes, João Antonino et. al. (2023). Ozone therapy for neuralgia-inducing cavitation osteonecrosis: case report. *Ozone Therapy Global Journal* Vol. 13, nº 1, pp 117-133

## Introduction

Cavitation neuralgia-inducing osteonecrosis (NICO) of the mandible is defined as a neuralgia-like chronic pain syndrome, analogous to trigeminal neuralgia (Sekundo *et al.*, 2022).<sup>1</sup> The term NICO began to be described in 1979 by Ratner *et al.* (Ratner, Person, Kleinman, Shklar, & Socransky, 1979),<sup>2</sup> however, it was from 1992 onwards that the term was incorporated and used more frequently (J. E. Bouquot, Roberts, Person, & Christian, 1992).<sup>3</sup> Its prevalence is still unknown, but a higher incidence is observed in females and in an age group between 40 and 60 years old (Yadav, Verma, Tiwari, & Article, 2019.<sup>4</sup>; Zuniga, 2000.<sup>5</sup> The etiopathology of this disease was considered infectious (injuries caused by microorganisms in the region of lesions in the alveolar bone and, consequently, osteomyelitis and bone necrosis) (Sardella, Demarosi, Barbieri, & Lodi, 2009).<sup>6</sup> However, with the advancement and modernization of diagnoses, some authors (Adams, Spolnik, & Bouquot, 1999;<sup>7</sup> J. E. Bouquot *et al.*, 2000.<sup>8</sup>) suggest two theories for the etiopathogenesis of NICO: 1) infectious, which considers bacterial agents as the main causes of the disease; 2) ischemic, whose main cause is bone tissue infarction due to lack of blood supply. These changes are caused by pathological changes in the alveolar bone, such as tooth extraction, endodontics and secondary alveolar hemorrhage, or even an infectious process (Adams *et al.*, 1999;<sup>7</sup> Ratner, Langer, & Mathew, 1986.<sup>9</sup>)

Treatment for NICO is based on clinical, histological and imaging examination where surgery is performed for complete cleaning/curettage of the bone tissue affected and originating the pain (J. E. Bouquot *et al.*, 1992).<sup>3</sup> In this procedure, local infiltration with antimicrobials can be used, with results of 90% improvement in the condition, lasting from two months to nine years (Ratner *et al.*, 1986, 1979).<sup>2</sup> The use of anticoagulants (warfarin, stanazolol) can also be used, however, a reduction of only 50% in pain was observed in these patients (Glueck *et al.*, 1998).<sup>10</sup> In dental practice, the application of ozone is used for washing in endodontics (Zahed *et al.*, 2013)<sup>11</sup>, primary root caries lesions (Baysan, Whiley, & Lynch, 2000)<sup>12</sup> and in the healing process of the oral cavity (Filippi, 2011).<sup>13</sup>

Ozone, from the Greek *ozein*, has been used for several purposes. Among these, the application known as Ozone Therapy stands out, which is the therapeutic administration of medicinal ozone for the treatment of several pathologies (V Bocci, 1996).<sup>14</sup> It has been used as a therapy since World War I, but it was in 1958 that Hansler developed the first generator capable of producing medicinal ozone concentrations, thus obtaining greater safety for its application (Velio Bocci and Carlo Aldinucci, 2006).<sup>15</sup> Ozone Therapy is currently available in several countries such as: Germany, Italy, Russia, China, Portugal, Spain, Turkey, Greece, Egypt, Cuba, Honduras and several countries in Eastern Europe. It can be administered by different routes according to its

therapeutic purpose, for example: topical route; rectal insufflation; application of gas around and within peripheral joints and spine; large and small autohemotherapy with medicinal ozone; ingestion of ozonized water, among others. Ozone Therapy is considered a safe practice as long as guidelines and protocols developed from therapeutic experiences and more recently from knowledge based on scientific evidence are followed (Velio Bocci, 2011).<sup>16</sup> A survey carried out by the German Medical Society for Ozone Therapy in 1980 documented 40 cases of side effects in 5,579,238 treatments performed on 384,775 patients, which means a risk of 0.0007%. Several studies in the scientific literature have already shown the benefits of Ozone Therapy for wounds (Kim *et al.*, 2009;<sup>17</sup> Patel *et al.*, 2012.<sup>18</sup>) osteoarthritis (Duymus *et al.*, 2017;<sup>19</sup> Mishra *et al.*, 2011.<sup>20</sup>) dental use (Indurkar & Verma, 2016),<sup>21</sup> arterial and venous vascular disorders (Martinez-Sanchez, Delgado-Roche, Diaz-Batista, Perez-Davison, & Re, 2012),<sup>22</sup> herniated disc (Niu *et al.*, 2018),<sup>23</sup> low back pain in general and chronic hepatitis B and C (NERONOV, 2009).<sup>24</sup>

One of the possible causes of NICO is a vascular osteonecrosis, which results in a chronic low-grade infection and susceptibility to thrombosis. Thus, Ozone Therapy may reduce erythrocyte aggregation and systemic oxidative stress (Shinriki *et al.*, 1998),<sup>25</sup> interrupt the integrity of the cell membrane through the oxidation of phospholipids and lipoproteins, with consequent improvement in bacterial infection (Bialoszewski *et al.*, 2010;<sup>26</sup> Burgassi, Zanardi, Travagli, Montomoli, & Bocci, 2009).<sup>27</sup> It may also stimulate tissue repair and oxygenation in the affected area, as well as favor platelet aggregation in the injured tissue. Hence, it may increase the endogenous production and release of these growth factors (Jing Zhang, Meiping Guan, Cuihua Xie, Xiangrong Luo, Qian Zhang, 2014;<sup>28</sup> Wang, 2018.<sup>29</sup>) To our knowledge, no controlled clinical trials studies of NICO and Ozone Therapy have been reported. Therefore, at least as far as the authors are concerned, this is the first report using Ozone Therapy in a patient with NICO showing benefits.

## 2. Case report

We report the case of a 74-year-old man, who came to us looking for pain relief from trigeminal neuropathy due to disc compression, disc displacement with reduction and overload of the masticatory muscles due to muscle fatigue and alteration of the motor and sensory innervation of the trigeminal due to condylar compression and sinusitis (figure 1). The patient presented supposed alterations, suggestive of areas of necrosis in the mandible (red circles figure 2). To confirm the diagnosis, Computed Haz Computed Tomography, Cone Beam (CBCT) i-CAT™ (CAT) was performed. To evaluate the bone density measurements in order to locate the osteonecrosis, we used a fundamental parameter described in Hounsfield units (HU) (figure 3). On clinical examination, pain was observed on palpation of the 4th quadrant (increased peripheral sensitization induced by an inflammatory mediator of the osteonecrosis) (Figure 4) and trigeminal neuralgia (characterized by recurrent episodes of very severe, brief, electric shock-like facial pain).

The patient had mouth breathing and consequently fatigue and muscle spasms, bruxism, snoring and disc displacement with mandibular reduction and deviation to the left and deviation to the third quadrant. He also had muscle overload and intra-articular space and consequently compression of the trigeminal nerve, where it triggers sensory stimuli erratically.

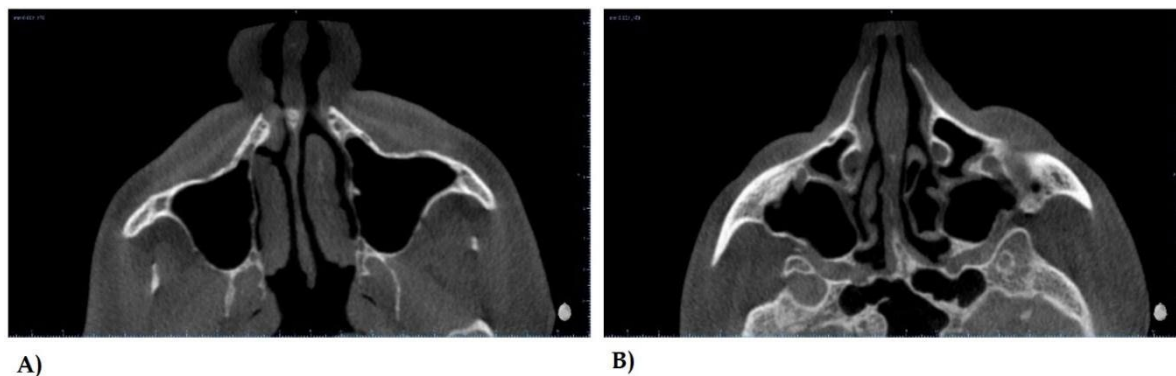


Figure 1. Conical Haz Computed Tomography observing nasal turbinate hypertrophy (A) and hypertrophy of the nasal septum (B)

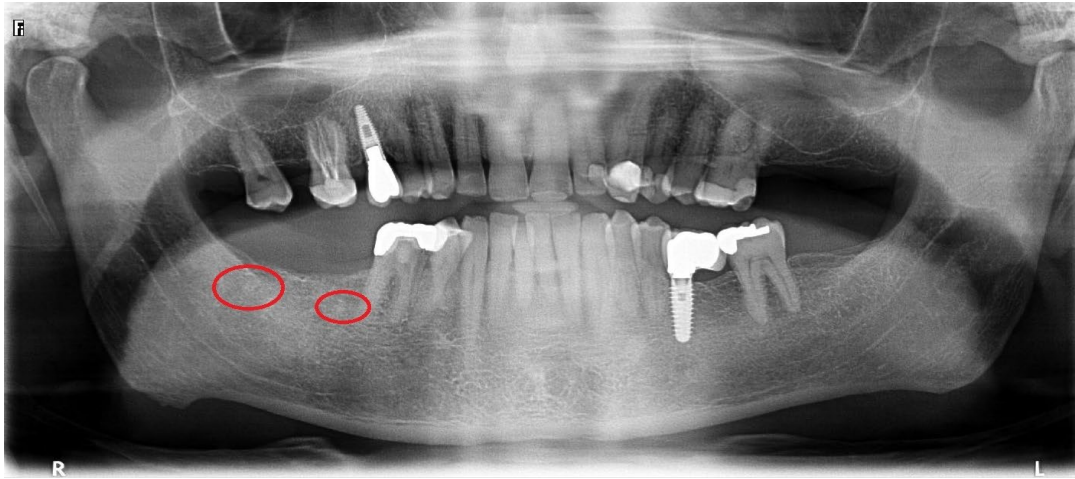


Figure 2. Pre-procedure orthopantomography

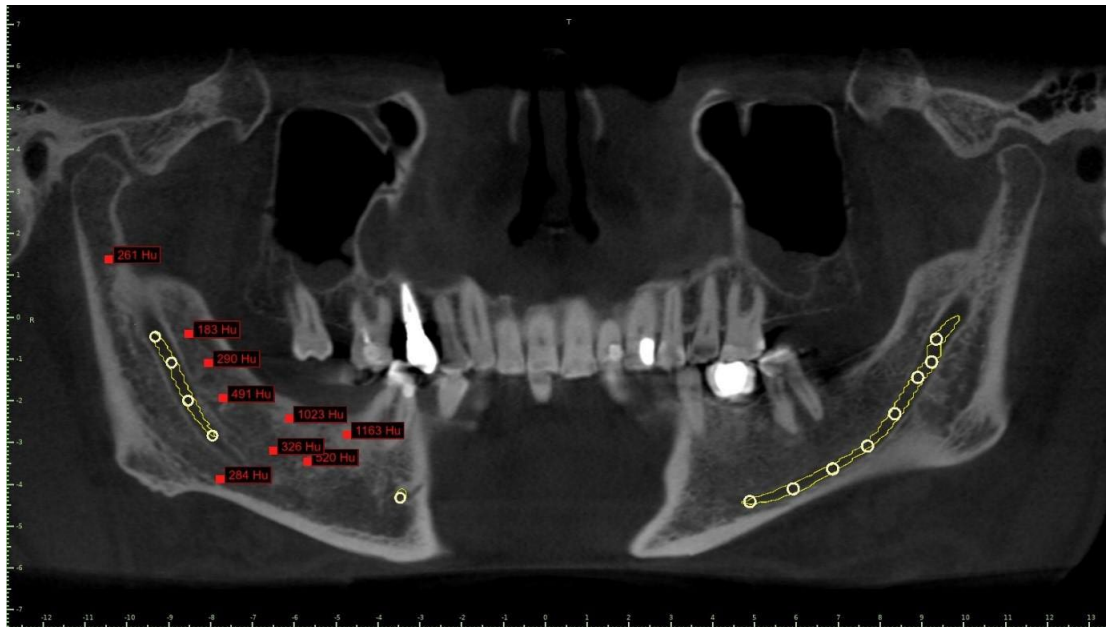


Figure 3. Conical Haz Computed Tomography for evaluation of bone density in HU

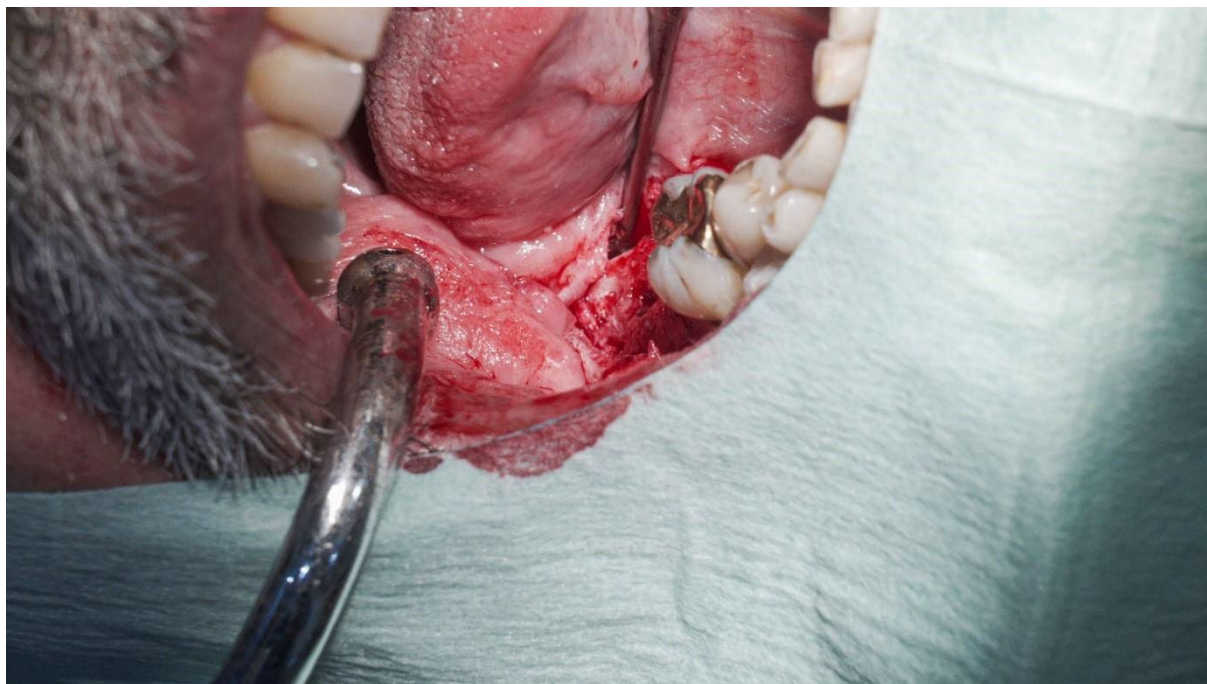

Figure 4. Pre-procedure view observing local inflammation

The patient was monitored (saturation and heart rates) and a nasal dilator was used to facilitate airway clearance, as the patient had nasal respiratory resistance due to hypertrophy of the septum of the nasal turbinate mucosa, which are bulky, for better breathing. Local anesthesia was used (Articaine 40 mg/mL plus adrenaline 10 micrograms/ml), visible laser (18 Jules) and ozonized saline solution (20 $\mu$ g/mL) (figure 5). The dental arch was scanned and the lower mold was made (with scanner) (figure 6), and it was performed irrigation with ozonized saline solution (first method described in the Declaration of Madrid, three needles: constant ozone bubbling to ensure that the solution is constantly saturated with ozone gas, with concentration of ozone dissolved in saline solution = 80  $\mu$ g/200 mL = 20  $\mu$ g/mL) (Isco3. Madrid Declaration. Adriana Schwartz *et al*, 2020).<sup>30</sup>

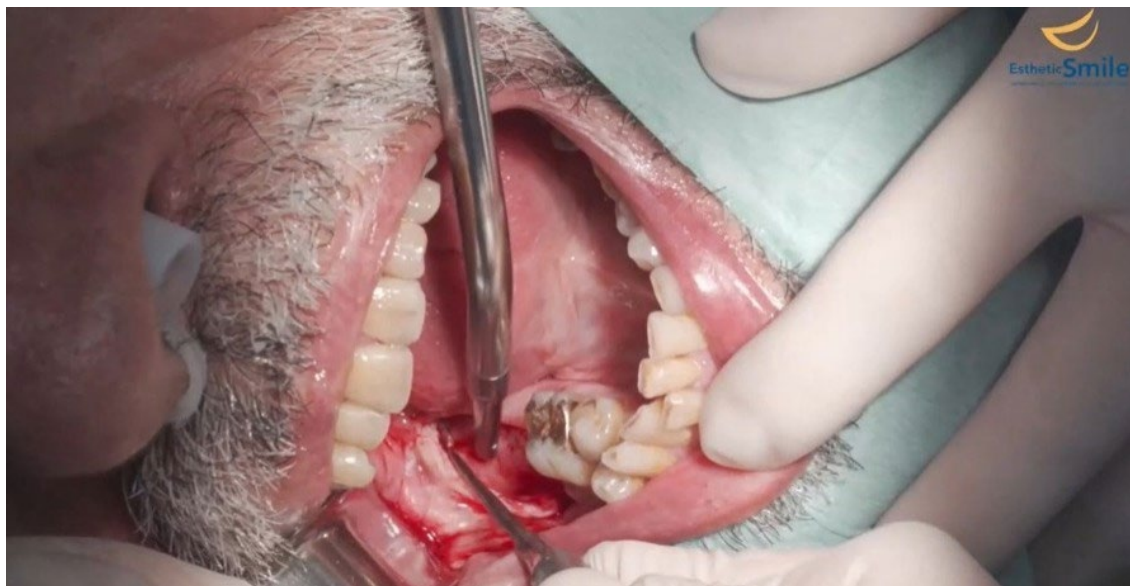

Figure 5. Pre-procedure view observing residual root and bone different from the bone base

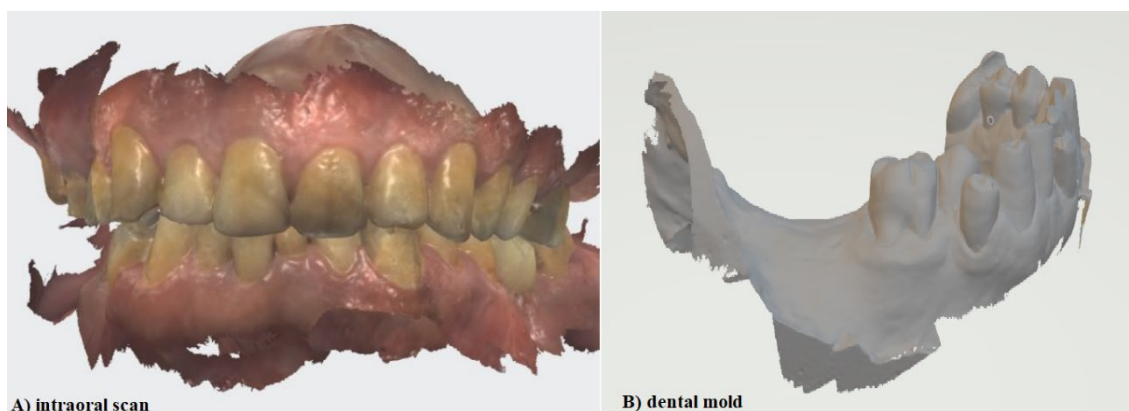


Figure 6. Buccal scanner

The patient was instructed to perform a 30-second preoperative rinse with reverse osmosis water. On the day of the curettage surgery in the 4th quadrant region, the site was anesthetized (articaine + adrenaline 08 ampoules) to block the inferior alveolar nerves. An envelope-type incision was made with a relaxing incision and an adaptable drilling guide was used (figures 7 and 8). Afterwards, complete debridement was performed and the site was irrigated with ozone-saturated saline solution (80  $\mu\text{g}/\text{mL}$ ) Madrid Declaration. Isco3. Adriana Schwartz *et al.* 2020),<sup>30</sup> Factores de crecimiento derivados de plaquetas y sus aplicaciones en medicina regenerativa. Potencialidades del uso del ozono como activador. (40  $\mu\text{g}/\text{mL}$ ) (Adriana Schwartz *et al.* 2011),<sup>31</sup> and, finally, bone graft cement was placed (biphasic calcium sulfates -Augma Shield™) (figure 9).



The closure was made with polyglycolic acid thread, size 3/0. A visual pain scale (VPS) was applied to the patient, with pain ranging from 7 to 8 points and the patient started using the following medications: amoxicillin 875 mg with potassium clavulanate 125 mg; metronidazole (250 mg), deflazacort (30 mg) and ibuprofen (600 mg), for a total of 6-8 days.

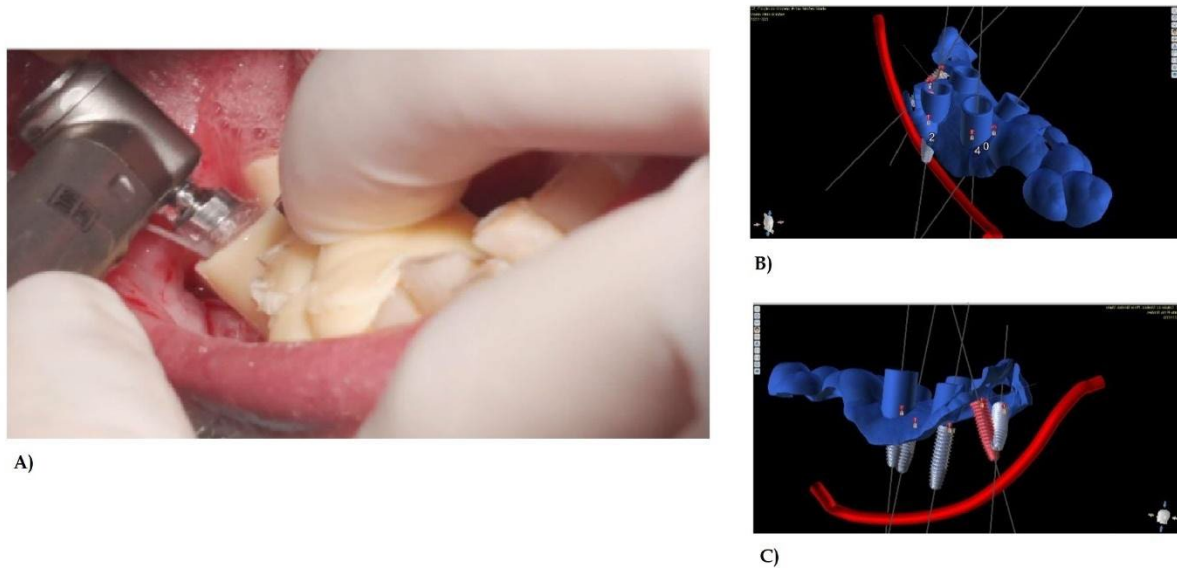


Figure 7. Minimally invasive surgical procedure (figure A), using an adaptable drilling guide HarzLabs DENTAL CLEAR Resin Guide (Harz Labs Latvia) for surgical guides and surgical guides planned by BlueSkyPlan software (BlueSkyBio EE. UU.) (figures B and C)

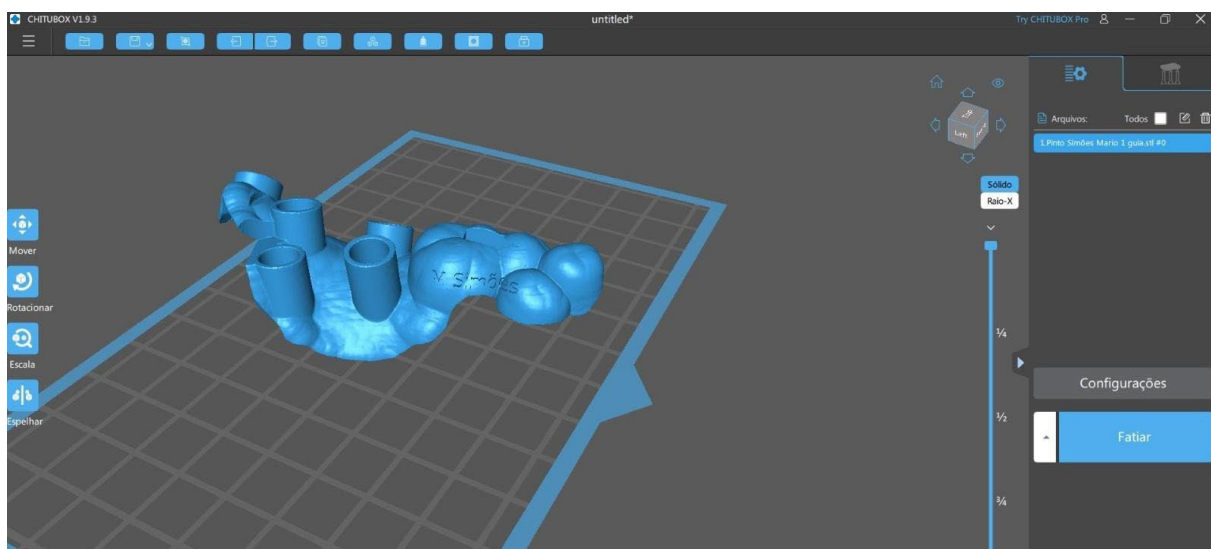


Figure 8. CHITUBOX rapid cutting software (CBD Technology Ltd Guangdong China) with HarzLabs DENTAL CLEAR resin (Harz Labs Latvia) for surgical guides

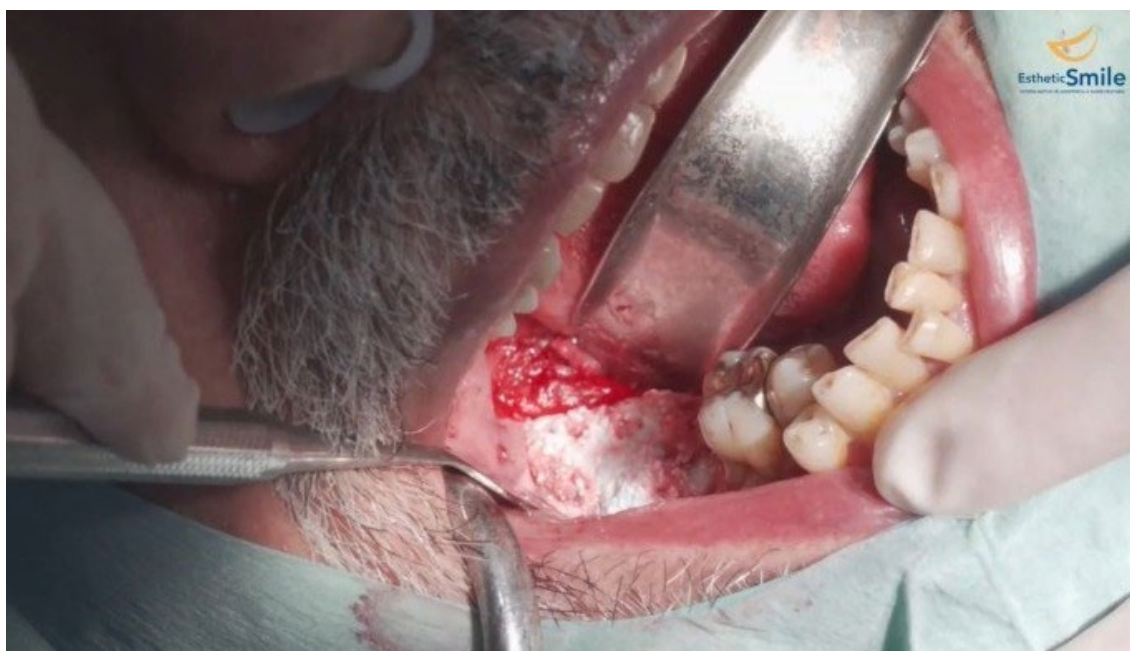

Figure 9. Post-procedure view and placement of Biphasic Calcium Sulfate (bone inducer)

The patient was reviewed on the 4th postoperative day and was doing well (4 to 5 points on the VPS scale), when transcutaneous electrical stimulation (intensity 8) in the 4th quadrant region, neural therapy 20% (2mL of procaine + 8mL saline) were applied (figure 10).

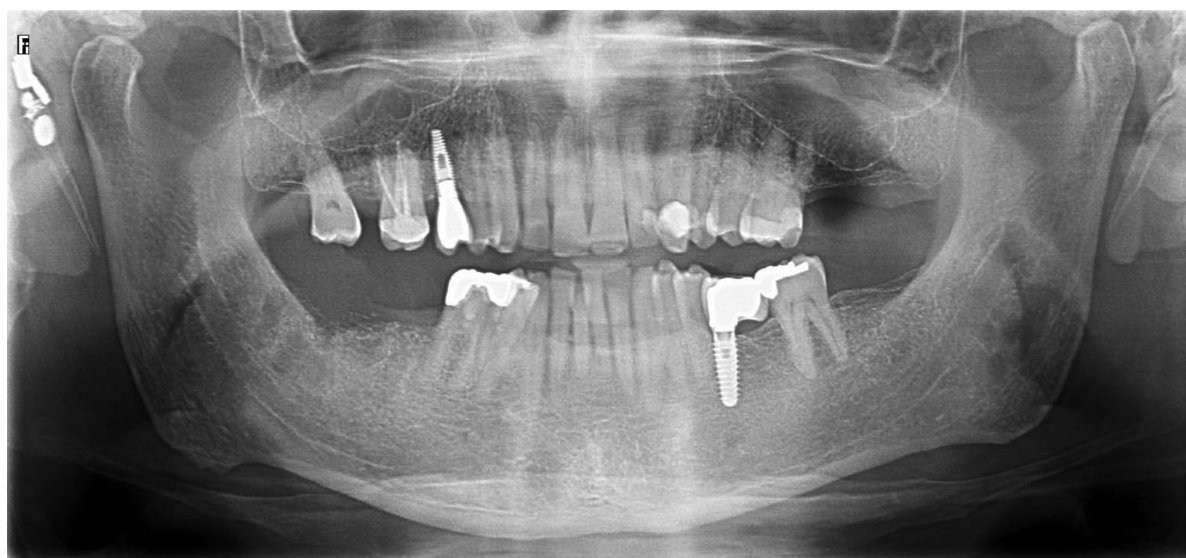


Figure 10. Orthopantomography after 4 days of procedure

After 30 days of the curettage procedure, the patient presented complete improvement of the pain in the NICO region, improvement of breathing with the use of intranasal dilator and nasal wash. After 90 days of the curettage procedure, the implants were placed (Figure 11).

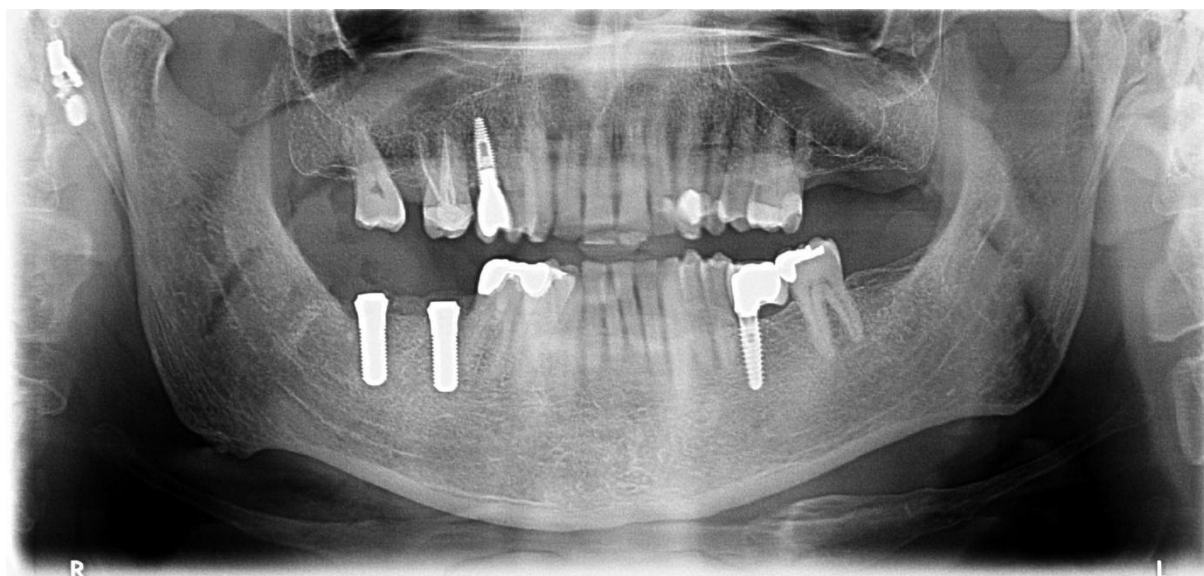


Figure 11. Radiograph with implant placement, after 3 months of procedure for NICO

### 3. Discussion

After almost 30 years of its introduction, the parameters for the diagnosis and treatment of NICO remain controversial. In most of the studies published to date, all patients included have been treated surgically and the results of treatment and pain relief have varied widely.

It is observed that patients with NICO may have concomitant pulpal or periodontal infections, may have undergone tooth extractions, endodontic procedures or periodontal surgeries, or even trauma to the facial region. Therefore, the osteonecrosis that occurs in NICO disease is the result of systemic and local events that can lead to bone ischemia and infarction. Thus, this results corroborate the literature, the proposed mechanisms of action of Ozone Therapy in promoting the stimulation of oxygen metabolism, modulation of the immune system, antimicrobial action, tissue repair, hemorheological improvement (Serra *et al.*, 2023)<sup>32</sup> and, consequently, the improvement of the general health state of the patient.

The benefits of Ozone Therapy in the treatment of different types of pain have already been demonstrated (Anzolin & Bertol, 2018;<sup>33</sup> Hidalgo-Tallón, *et al.*, 2022.<sup>34</sup>), being indicated as an adjuvant treatment for diseases related to disturbances in cellular redox balance or tissue oxygenation. Thus, systemic Ozone Therapy can help patients with chronic pain, including those with facial neuralgia, through the mechanism of the role of reactive oxygen species in hyperalgesia via activation of N-methyl-D-aspartate (NMDA) receptors (Hidalgo-Tallón *et al.*, 2022).<sup>34</sup>

In dentistry, Edward Frisch was the first to use ozonized water, using it as an antiseptic in oral surgery. In 2008, Azarpazhooh and Limeback also applied aqueous ozone to decontaminate the surfaces of dental implants (Azarpazhooh & Limeback, 2008).<sup>35</sup> In a recent systematic review, the authors have evaluated the effectiveness of the use of adjuvant Ozone Therapy in the healing process of wounds, resulting from periodontal and peri-implant surgical procedures. Of 107 potentially eligible registries, seven studies were included, 4 addressed gingival grafts, 2 implant sites, and 1 gingivectomy and gingivoplasty. In total, 225 patients were evaluated in the included studies and it was observed that Ozone Therapy had a positive effect on the results, directly or indirectly related to the healing of the periodontal/peri-implant surgical wound, also increasing the stability of immediate load single implants, installed in the posterior mandible (Palma, Luiz Felipe, Joia, Cristiano, & Chambrone, Leandro, [s.d.]<sup>36</sup>

In osteonecrosis of the mandible, the use of Ozone Therapy is also described, the most common procedures being gas insufflation and local application, where promising results were observed (El-Rabbany, Sgro, Lam, Shah, & Azarpazhooh, 2017;<sup>37</sup> Ripamonti, Cislighi, Mariani, & Maniezzo, 2011.<sup>38</sup>) Research in animal models has verified that the use of ozone can be an effective therapeutic option, since it helps in the repair of bone tissue (Buyuk, Ramoglu, & Sonmez, 2016;<sup>39</sup> Erdemci *et al.*, 2014.<sup>40</sup>) In studies involving repair of post-extraction sockets and the use of Ozone Therapy, positive responses were observed regarding bone repair (increase in the formation of bone trabeculae in the groups treated with ozone compared to the control groups), improvement in cell proliferation (greater number of fibroblasts), repair of soft tissues and acceleration of the healing period (antimicrobial effect of ozone) (Ozdemir, Toker, Balci, & Ozer, 2013;<sup>41</sup> Toker, 2017.<sup>42</sup>) The use of Ozone Therapy in femoral head osteonecrosis has also been recently described. The authors performed a non-randomized clinical trial with 71 patients (107 hip joints) in stages I, II, III and IV of osteonecrosis. Patients received intra-articular injections of Ozone Therapy in the hip with ozonized autohemotherapy (Ozone Therapy group, n = 39, 58 hip joints) or protected weight-bearing (control group, n = 32, 49 hip joints). Ozone Therapy was observed to effectively improve the VPS for pain intensity, it also showed a significant resolution of femoral head bone marrow edema compared to the control group ( $P < 0.001$ ). Thirteen of 49 hips (26.53%) in the control group underwent total hip arthroplasty (THA), while only 6 hips (10.34%) in the Ozone Therapy group required THA during a 30-month follow-up ( $P = 0.041$ ). Therefore, Ozone Therapy can be associated with significant pain relief, improvement in hip function and resolution of bone marrow edema (An *et al.*, 2022).<sup>43</sup>

In a study combining local curettage and antimicrobial use, it was observed that ozone exerted a beneficial effect through oxidative preconditioning, stimulating endogenous antioxidant systems and blocking the xanthine/xanthine oxidase pathway for the generation of oxidative stress. The authors also observed benefits in blood circulation, increasing the concentration of red blood cells and the level of antioxidants in hemoglobin, which have a biological effect on the germicidal properties of the metabolism of oxygen, calcium, phosphorus and iron (Agrillo *et al.*, 2006).<sup>44</sup> In osteonecrosis of the mandible caused by bisphosphonates, the use of Ozone Therapy was reported in a patient, female, 53 years old and with painful symptoms in the mandible and maxilla. In an attempt to reduce the symptoms and to prevent the progression of the lesions, the treatment of Ozone Therapy with low-intensity laser therapy (LLLT) was recommended, which showed regression of the osteonecrosis lesions and a decrease in the patient's pain (Moraes *et al.*, 2016).<sup>45</sup>

In this case, it was used a combination of Ozone Therapy and low-intensity laser. A recent article (Özalp *et al.*, 2022)<sup>46</sup> compared the effectiveness of Ozone Therapy and LLLT in healing oral mucosal wounds in rats through histological evaluation. Thirty rats were used in this study. After a 5 mm surgical wound was created in the buccal mucosa, the rats were randomly assigned to 3 groups of 10: (1) ozone group (treated with topical ozone gas), (2) laser group (treated with LLLT), and (3) control group (did not receive treatment). After 21 days, the rats were sacrificed and samples of the buccal mucosa were taken. It was observed that the ozone and laser groups demonstrated reduced acute inflammation scores compared to the control group and in the histological evaluation the ozone and laser groups had higher tissue repair histological scores than the control group, and no difference was found between the ozone and laser groups ( $p = 0.76$ ). Therefore, the study demonstrated that in an animal model, both adjuvant Ozone Therapy and LLLT provided significant improvement in the parameters of acute inflammation and tissue repair in surgical wounds of the oral mucosa in rats. In the area of implant dentistry, the benefits of the combination of Ozone Therapy + LLLT have also been observed. In 25 patients, a total number of 100 implants were applied, where they were divided into four treatment groups (Group 1: LLLT therapy group, Group 2: Ozone Therapy group, Group 3: protocol different from the Ozone Therapy group, and Group 4: control group). It was shown that the overall implant survival rate was 92% after an observation period of 6 months. Implant stability quotient values were significantly higher in Group 1 (LLLT group) and Group 3 (different protocol than Ozone Therapy group) than in the other groups ( $P < 0.05$ ).

## **4. Conclusion**

In conclusion, our experiences show the benefits of Ozone Therapy in the treatment of NICO. One of the possible mechanisms of action is tissue stimulation and oxygenation in the affected area, release of growth factors and antimicrobial action. The use of Ozone Therapy is mainly motivated by its quick benefits, ease of using and low cost in both equipment and human resources. Therefore, the use of Ozone Therapy seems to be an effective possibility in patients with NICO and future research, specifically to understand the mechanism of action, will be very important to design preventive strategies and to confirm the effectiveness of Ozone Therapy.

## **Funding**

No funding was received for this work.

## **Conflicts of interest**

Authors declare having no conflict of interest.

## **Ethical statement**

The patient has signed a written informed consent for publication of this report and has granted permission for his photographs to be published.

## References

1. Sekundo, C., Wiltfang, J., Schliephake, H., Al-Nawas, B., Rückschloß, T., Moratin, J., Ristow, O. (2022). Neuralgia-inducing cavitation osteonecrosis – A systematic review. *Oral Diseases*, 28(6), 1448–1467. doi: 10.1111/odi.13886
2. Ratner, E. J., Person, P., Kleinman, D. J., Shklar, G., & Socransky, S. S. (1979). Jawbone cavities and trigeminal and atypical facial neuralgias. *Oral Surgery, Oral Medicine, Oral Pathology*, 48(1), 3–20. doi: 10.1016/0030-4220(79)90229-9
3. Bouquot, J. E., Roberts, A. M., Person, P., & Christian, J. (1992). Neuralgia-inducing cavitation osteonecrosis (NICO). Osteomyelitis in 224 jawbone samples from patients with facial neuralgia. *Oral Surgery, Oral Medicine, Oral Pathology*, 73(3), 307–319. doi: 10.1016/0030-4220(92)90127-C
4. Yadav, R., Verma, U., Tiwari, R., & Article, O. (2019). Neuralgia-inducing cavitation osteonecrosis – Fact or myth, the debate persists. *National Journal of Maxillofacial Surgery*, 10(1), 3–7. doi: 10.4103/njms.NJMS
5. Zuniga, J. R. (2000). Challenging the neuralgia-inducing cavitation osteonecrosis concept. *Journal of Oral and Maxillofacial Surgery*, 58(9), 1021–1028. doi: 10.1053/joms.2000.8745.
6. Sardella, A., Demarosi, F., Barbieri, C., & Lodi, G. (2009). An up-to-date view on persistent idiopathic facial pain. *Minerva stomatologica*, 58(6), 289–299.
7. Adams, W. R., Spolnik, K. J., & Bouquot, J. E. (1999). Maxillofacial osteonecrosis in a patient with multiple “idiopathic” facial pains. *Journal of Oral Pathology and Medicine*, 28(9), 423–432. doi: 10.1111/j.1600-0714.1999.tb02115.x
8. Bouquot, Jerry E., & McMahan, R. E. (2000). Neuropathic pain in maxillofacial osteonecrosis. *Journal of Oral and Maxillofacial Surgery*, 58(9), 1003–1020. doi: 10.1053/joms.2000.8744.
9. Ratner, E. J., Langer, B., & Mathew, L. (1986). Alveolar Cavitation Osteopathosis. *J. Periodontol.* Sekundo, C., Wiltfang, J., Schliephake, H., Al-Nawas, B., Rückschloß, T., Moratin, J., ... Ristow, O. (2022). Neuralgia-inducing cavitation osteonecrosis – A systematic review. *Oral Diseases*, 28(6), 1448–1467. doi: 10.1111/odi.13886.
10. Glueck, C. J., McMahan, R. E., Bouquot, J. E., Tracy, T., Sieve-Smith, L., & Wang, P. (1998). A preliminary pilot study of treatment of thrombophilia and hypofibrinolysis and amelioration of the pain of osteonecrosis of the jaws. *Oral Surgery, Oral Medicine, Oral Pathology, Oral Radiology, and Endodontics*, 85(1), 64–73. doi: 10.1016/S1079-2104(98)90400-0.
11. Zahed M, Sousan S, Mohammad KS, Saeed A. A Review of the Properties and Applications of Ozone in Endodontics: An Update. *Iranian Endodontic Journal* 2013;8:40–3.
12. Baysan, A., Whiley, R. A., & Lynch, E. (2000). Antimicrobial Effect of a Novel Ozone-Generating Device on Micro-Organisms Associated with Primary Root Carious Lesions in vitro. *Caries Research*, 34(6), 498–501. doi: 10.1159/000016630.
13. Filippi, A. (2011). The Influence Of Ozonised Water On The Epithelial Wound Healing Process In The Oral Cavity. *Clinic of Oral Surgery, Radiology and Oral Medicine*, University of Basel, Switzerland, 1(14).
14. Bocci, V. (1996). Does ozone therapy normalize the cellular redox balance? Implications for therapy of human immunodeficiency virus infection and several other diseases. *Medical Hypotheses*, 46(2), 150–154. doi: 10.1016/s0306-9877(96)90016-x
15. Velio Bocci and Carlo Aldinucci. (2006). Biochemical Modifications Induced in Human Blood by Oxygenation-Ozonation. *Journal of biochemical molecular toxicology*, 20(3), 133–138.
16. Bocci, Velio. (2011). Ozone: A new medical drug. *Ozone: A New Medical Drug*, 1–315. doi: 10.1007/978-90-481-9234-2
17. Kim, H. S., Noh, S. U., Han, Y. W., Kim, K. M., Kang, H., Kim, H. O., & Park, Y. M. (2009).

- Therapeutic effects of topical application of ozone on acute cutaneous wound healing. *Journal of Korean Medical Science*, 24(3), 368–374. doi: 10.3346/jkms.2009.24.3.368.
18. Patel, P. V., Kumar, S., Vidya, G. D., Patel, A., Holmes, J. C., & Kumar, V. (2012). Cytological assessment of healing palatal donor site wounds and grafted gingival wounds after application of ozonated oil: An eighteen-month randomized controlled clinical trial. *Acta Cytologica*, 56(3), 277–284. doi: 10.1159/000336889
  19. Duymus, T. M., Mutlu, S., Dernek, B., Komur, B., Aydogmus, S., & Kesiktas, F. N. (2017). Choice of intra-articular injection in treatment of knee osteoarthritis: Platelet-rich plasma, hyaluronic acid or ozone options. *Knee Surgery, Sports Traumatology, Arthroscopy*, 25(2), 485–492. doi: 10.1007/s00167-016-4110-5
  20. Mishra, S. K., Pramanik, R., Das, P., Das, P. P., Palit, A. K., Roy, J., & Halder, R. N. (2011). Role of intra-articular ozone in osteo-arthritis of knee for functional and symptomatic improvement. *Ind J Phys Med Rehabil*, 22(2), 65–69.
  21. Indurkar, M. S., & Verma, R. (2016). Effect of ozonated oil and chlorhexidine gel on plaque induced gingivitis: A randomized control clinical trial. *Journal of Indian Society of Periodontology*, 20(1), 32–35. doi: 10.4103/0972-124X.170806.
  22. Martinez-Sanchez, G., Delgado-Roche, L., Diaz-Batista, A., Perez-Davison, G., & Re, L. (2012). Effects of ozone therapy on haemostatic and oxidative stress index in coronary artery disease. *European Journal of Pharmacology*, 691(1–3), 156–162. doi: 10.1016/j.ejphar.2012.07.010
  23. Niu, T., Lv, C., Yi, G., Tang, H., Gong, C., & Niu, S. (2018). Therapeutic Effect of Medical Ozone on Lumbar Disc Herniation. *Medical Science Monitor: International Medical Journal of Experimental and Clinical Research*, 24, 1962–1969. doi: 10.12659/msm.903243
  24. NERONOV, V. A. (2009). Experience with the use of ozone for the treatment of chronic viral hepatitis. *Vopr Kurortol Fizioter Lech Fiz Kult*, 14–17.
  25. Shinriki, N., Suzuki, T., Takama, K., Fukunaga, K., Ohgiya, S., Kubota, K., & Miura, T. (1998). Susceptibilities of plasma antioxidants and erythrocyte constituents to low levels of ozone. *Haematologia*, 29(3), 229–239.
  26. Bialoszewski, D., Bocian, E., Bukowska, B., Czajkowska, M., Sokol-Leszczynska, B., & Tyski, S. (2010). Antimicrobial activity of ozonated water. *Medical Science Monitor: International Medical Journal of Experimental and Clinical Research*, 16(9), MT71-5.
  27. Burgassi, S., Zanardi, I., Travagli, V., Montomoli, E., & Bocci, V. (2009). How much ozone bactericidal activity is compromised by plasma components? *Journal of Applied Microbiology*, 106(5), 1715–1721. doi: 10.1111/j.1365-2672.2008.04141.x
  28. Jing Zhang, Meiping Guan, Cuihua Xie, Xiangrong Luo, Qian Zhang, Y. X. (2014). Increased growth factors play a role in wound healing promoted by noninvasive oxygen-ozone therapy in diabetic patients with foot ulcers. *Oxidative Medicine and Cellular Longevity*, 2014, 273475. doi: 10.1155/2014/273475.
  29. Wang, X. (2018). Emerging roles of ozone in skin diseases. *Zhong Nan Da Xue Xue Bao. Yi Xue Ban = Journal of Central South University. Medical Sciences*, 43(2), 114–123. doi: 10.11817/j.issn.1672-7347.2018.02.002.
  30. Madrid Declaration on Ozone Therapy (3rd edition, 2020 ISCO3). A. Schwartz *et al.*
  31. Schwartz, A. Martínez- Sánchez, G. Re, L. (2011). Factores de crecimiento derivados de plaquetas y sus aplicaciones en medicina regenerativa. Potencialidades del uso del ozono como activador. *Revista Española de Ozonoterapia*. Vol.1, nº 1, pp. 54-73.
  32. Serra, M. E. G., Baeza-Noci, J., Mendes Abdala, C. V., Luvisotto, M. M., Bertol, C. D., & Anzolin, A. P. (2023). The role of ozone treatment as integrative medicine. An evidence and gap map. *Frontiers in Public Health*, 10, 1112296. doi: 10.3389/fpubh.2022.1112296.
  33. Anzolin, A. P., & Bertol, C. D. (2018). Ozone therapy as an integrating therapeutic in osteoartrosis treatment: A systematic review. *Brazilian Journal Of Pain*, 1(2). doi: 10.5935/2595-0118.20180033.
  34. Hidalgo-Tallón, F. J., Torres-Morera, L. M., Baeza-Noci, J., Carrillo-Izquierdo, M. D., & Pinto-Bonilla, R. (2022). Updated Review on Ozone Therapy in Pain Medicine. *Frontiers in Physiology*, 13, 840623. doi: 10.3389/fphys.2022.840623.



35. Azarpazhooh, A., & Limeback, H. (2008). The application of ozone in dentistry: A systematic review of literature. *Journal of Dentistry*, 36(2), 104–116. doi: 10.1016/j.jdent.2007.11.008.
36. Palma, Luiz Felipe, Joia, Cristiano, & Chambrone, Leandro. ([s.d.]). Effects of ozone therapy on periodontal and peri-implant surgical wound healing: A systematic review. *Quintessence International*, (Pre-print), 1–21. doi: 10.3290/j.qi.b3512007.
37. El-Rabbany, M., Sgro, A., Lam, D. K., Shah, P. S., & Azarpazhooh, A. (2017). Effectiveness of treatments for medication-related osteonecrosis of the jaw. *The Journal of the American Dental Association*, 148(8), 584-594.e2. doi: 10.1016/j.adaj.2017.04.002.
38. Ripamonti, C. I., Cislighi, E., Mariani, L., & Maniezzo, M. (2011). Efficacy and safety of medical ozone (O<sub>3</sub>) delivered in oil suspension applications for the treatment of osteonecrosis of the jaw in patients with bone metastases treated with bisphosphonates: Preliminary results of a phase I–II study. *Oral Oncology*, 47(3), 185–190. doi: 10.1016/j.oraloncology.2011.01.002.
39. Buyuk, S. K., Ramoglu, S. I., & Sonmez, M. F. (2016). The effect of different concentrations of topical ozone administration on bone formation in orthopedically expanded suture in rats. *The European Journal of Orthodontics*, 38(3), 281–285. doi: 10.1093/ejo/cjv045.
40. Erdemci, F., Gunaydin, Y., Sencimen, M., Bassorgun, I., Ozler, M., Oter, S., ... Gider, İ. K. (2014). Histomorphometric evaluation of the effect of systemic and topical ozone on alveolar bone healing following tooth extraction in rats. *International Journal of Oral and Maxillofacial Surgery*, 43(6), 777–783. doi: 10.1016/j.ijom.2013.12.007.
41. Ozdemir, H., Toker, H., Balci, H., & Ozer, H. (2013). Effect of ozone therapy on autogenous bone graft healing in calvarial defects: A histologic and histometric study in rats. *Journal of Periodontal Research*, 48(6), 722–726. doi: 10.1111/jre.12060.
42. Toker, H. (2017). The Effects of Allograft Combined with Ozone Therapy on Regeneration of Calvarial Defects in Rats. *Cumhuriyet Dental Journal*, 19(3), 205–205. doi: 10.7126/cumudj.298891.
43. An, J.-X., Wu, G.-P., Niu, K., Wei, Y.-P., Liu, H., Gao, X.-Y., ... Williams, J. P. (2022). Treatment of Femoral Head Osteonecrosis with Ozone Therapy: Pilot Trial of a New Therapeutic Approach. *Pain Physician*, 25(1), E43–E54.
44. Agrillo, A., Petrucci, M. T., Tedaldi, M., Mustazza, M. C., Marino, S. M. F., Gallucci, C., & Iannetti, G. (2006). New Therapeutic Protocol in the Treatment of Avascular Necrosis of the Jaws. *Journal of Craniofacial Surgery*, 17(6), 1080–1083. doi: 10.1097/01.scs.0000249350.59096.d0.
45. Moraes, M. B., Lopes, G. da S., Nascimento, R. D., Gonçalves, F. de C. P., Santos, L. M. dos, & Raldi, F. V. (2016). Use of ozone therapy together to low power laser in osteonecrosis induced bisphosphonates—Clinical case. *Brazilian Dental Science*, 19(1), 129–134. doi: 10.14295/bds.2016.v19i1.1138.
46. Özalp, Ö., Sindel, A., Altay, M. A., Özbudak, İ. H., Bilgin, B., Kocabalkan, B., & Kader, D. (2022). Comparative evaluation of the efficacy of ozone therapy and low level laser therapy on oral mucosal wound healing in rat experimental model. *Journal of Stomatology, Oral and Maxillofacial Surgery*, 123(6), e670–e674. doi: 10.1016/j.jormas.2022.03.018.