

# Technical Considerations on the Transapical Jenavalve® Implantation

## Consideraciones técnicas sobre el implante transapical de la válvula Jenavalve®

MIGUEL RUBIO<sup>MTSAC</sup>, RAÚL A. BORRACCI<sup>MTSAC</sup>, JULIO BALDI (H), DANIEL E. YÑON

### ABSTRACT

**Background:** Senile aortic stenosis is currently the most frequent disease in cardiac surgery, though surgical treatment is limited in high risk patients. In these cases, transcatheter aortic valve implantation (TAVI) is the alternative technique.

**Objective:** The aim of this study was to evaluate and describe in detail the technique with transapical approach as primary or secondary indication when other access sites are not feasible.

**Methods:** Among a total of 51 patients treated with TAVI, the study analyzed 28 patients undergoing transapical approach (TA-TAVI) with Jenavalve™ porcine biological valve from March 2014 to March 2016.

**Results:** The transapical procedure was possible in all the selected patients. Immediate postoperative mortality was 10.71% (3/28) and no causes were attributable to the transapical approach. Morbidity was 28.57% (8/28).

**Conclusions:** In some cases, femoral or axillary access is not feasible, mainly due to inadequate anatomy or existing disease. The transapical approach appears then as strict indication. However, some groups propose its use as a first-choice strategy to facilitate implantation and lower the risk of embolic events. The transapical approach with rigorous technique allows implantation of this type of aortic valve prosthesis. Minimal access is well tolerated by this critical group of patients. The observed mortality was not associated with the approach.

**Key words:** TAVI - Transapical Approach - Jenavalve

### RESUMEN

**Introducción:** La estenosis aórtica senil es hoy la patología más frecuente en la cirugía cardíaca. No obstante, el tratamiento quirúrgico encuentra un límite de aplicación en los pacientes de riesgo alto; en estos casos, la alternativa técnica consiste en el implante de válvula aórtica transcáteter (TAVI).

**Objetivo:** Evaluar y describir en detalle la técnica con abordaje transapical como indicación primaria o secundaria ante la imposibilidad de otro sitio de ingreso.

**Material y métodos:** De un total de 51 pacientes tratados con TAVI se analizaron 28 a los que se les realizó abordaje transapical (TAVI-TA) con implante de válvula biológica porcina Jenavalve® desde marzo de 2014 a marzo de 2016.

**Resultados:** En todos los pacientes propuestos, el abordaje fue posible. La mortalidad inmediata del procedimiento fue del 10,71% (3/28). No hubo causas atribuibles al abordaje apical. La morbilidad fue del 28,57% (8/28).

**Conclusiones:** Las vías femoral y axilar no siempre son posibles de utilizar debido a anatomía inadecuada o patología existente. El abordaje transapical aquí aparece como indicación estricta. Sin embargo, hay quienes proponen este acceso primario para facilitar el implante y disminuir el riesgo de evento embólico. El abordaje transapical realizado con una técnica estricta permite el implante de este tipo de prótesis valvular aórtica. El acceso mínimo es bien tolerado por este grupo crítico de pacientes. La mortalidad observada no se asoció con el abordaje.

**Palabras clave:** TAVI - Abordaje transapical - Jenavalve

### Abbreviations

AV	Atrioventricular	TAVI	Transcatheter aortic valve implantation
3D	Three-dimensional	TA-TAVI	Transapical transcatheter aortic valve implantation
CAT	Computerized axial tomography		

REV ARGENT CARDIOL 2016;84:433-437. <http://dx.doi.org/10.7775/rac.v84.i5.8529>

Received: 05/16/2016 – Accepted: 07/13/2016

Address for reprints: Dr. Miguel Rubio - Juncal 3118 - PB - (1425) Ciudad Autónoma de Buenos Aires - e-mail: [drmiguelrubio@gmail.com](mailto:drmiguelrubio@gmail.com)

## INTRODUCTION

Senile aortic stenosis is currently the most prevalent disease to be treated with cardiac surgery. Technological advances have expanded its therapeutic indication and there are practically no age limits for its correction. (1) There is, however, an unclearly defined barrier establishing who can access surgery with extracorporeal circulation. This has been up to the present the gold standard for aortic valve replacement. Nonetheless, risk scores, patient frailty and common sense limit its application. (2, 3)

Cribier (4) created a vast field of clinical research with his development of a heart valve stent inserted by femoral access, modifying the concept of this pathology. High risk elderly patients constituted the initial groups of application. The implementation of this technique generated two special situations: the first is the non-application of aortic valve replacement since the calcific valve remains crushed in situ with consequent paravalvular leak; the second is the prosthesis trajectory with its navigation system.

The femoral approach for transcatheter aortic valve implantation (TAVI) is technically simple, though it has to overcome the difficulty generated by the local vascular disease, the transit along the aortic arch and the origin of the great vessels. The process, at times tedious, of the retrograde passage through the aortic valve and the incorrect alignment of the aortic valve plane limit this technique. The transapical approach (TA-TAVI) with minimal thoracic incision seems a good alternative avoiding all the above mentioned difficulties and placing the device only a few centimeters from the operator with exquisite manual sensitivity and without prosthesis positioning complications. (5)

The aim of this study was to analyze the technical considerations to perform cardiac apical approach to minimize risk and complications.

## METHODS

Among a total of 51 patients treated with TAVI, 28 patients undergoing TA-TAVI with biological porcine Jenavalve™ from March 2014 to March 2016 were analyzed. The procedures were carried out at Hospital de Clínicas of the Universidad de Buenos Aires and at two associated private hospitals (Sanatorio Otamendi and Clínica Bazterrica). They were all performed by the same surgical team and in association with the Hemodynamic Unit of each institution. Mean age was 83.2 years, and ranged between 70 and 96 years. Fifty-four percent of patients were women and all patients fulfilled logistic EuroSCORE above 20% and functional class above III requirements. In 17.9% of cases (5/28), patients presented with previous cardiac surgery and two had prosthetic mitral valve implant. All cases were analyzed with multislice computerized axial tomography (CAT) and 3D reconstruction to establish anatomic configuration. Patients that did not meet with adequate calcific distribution, or had large aortic valve annulus were excluded from the study due to probable graft instability. The initial indication was in patients who did not have adequate aortoiliac axis, in whom changing the approach facilitated implantation and reduced embolic risk.

The Jenavalve™ Transapical TAVI System, developed in

Germany, was the device used in all cases. It consists of a stent with attached porcine valve of 23, 25 and 27 mm annular diameter and 32 Fr implantation sheath. The design of this prosthesis demands a distance of 8 mm or more from the valve plane to the coronary arteries, a valve annulus diameter between 21 and 27 mm and the length of the aortic valve plane to the aortic arch should be over 65 mm.

As additional requisite the procedure was not performed if there was evidence of endocarditis, active infections or thrombi in the left heart chambers. The physical facility fulfilled the requirements of a hybrid operating room in one of the institutions and the other two had large hemodynamics laboratory, with high-definition radiological systems located in the surgical area and with the necessary equipment for immediate intervention. All the procedures were assisted with transesophageal Doppler echocardiography (TEDE) and were performed under general anesthesia and nonselective endotracheal intubation.

## Surgical technique

To fulfill the objective of minimal incision, CAT with 3D reconstruction must be used to evaluate the patient. This procedure aims at locating the intercostal space where the apex is projected marking the tip with transthoracic echocardiography and placing the incision at its center, with a necessary extension of 6 to 8 cm. A small size sternal retractor is used to avoid pushing down the cardiac surface (Figure 1).

Following thoracotomy, the pericardium is repaired with firm stitches to the skin, stabilizing the heart. The cardiac tip is manually identified to avoid making a very lateral purse-string suture, as this would hamper the prosthetic implantation and also surgical closure, in addition to predisposing to myocardial rupture. The double purse-string suture is done with Teflon patches using 3.0 polypropylene sutures, and must include all cardiac layers. It is necessary to consider that the introducer has more than 11 mm diameter and requires sufficient space. Achieving a symmetrical distribution of sutures allows better hemostatic control and does not alter apical anatomy (Figure 2).

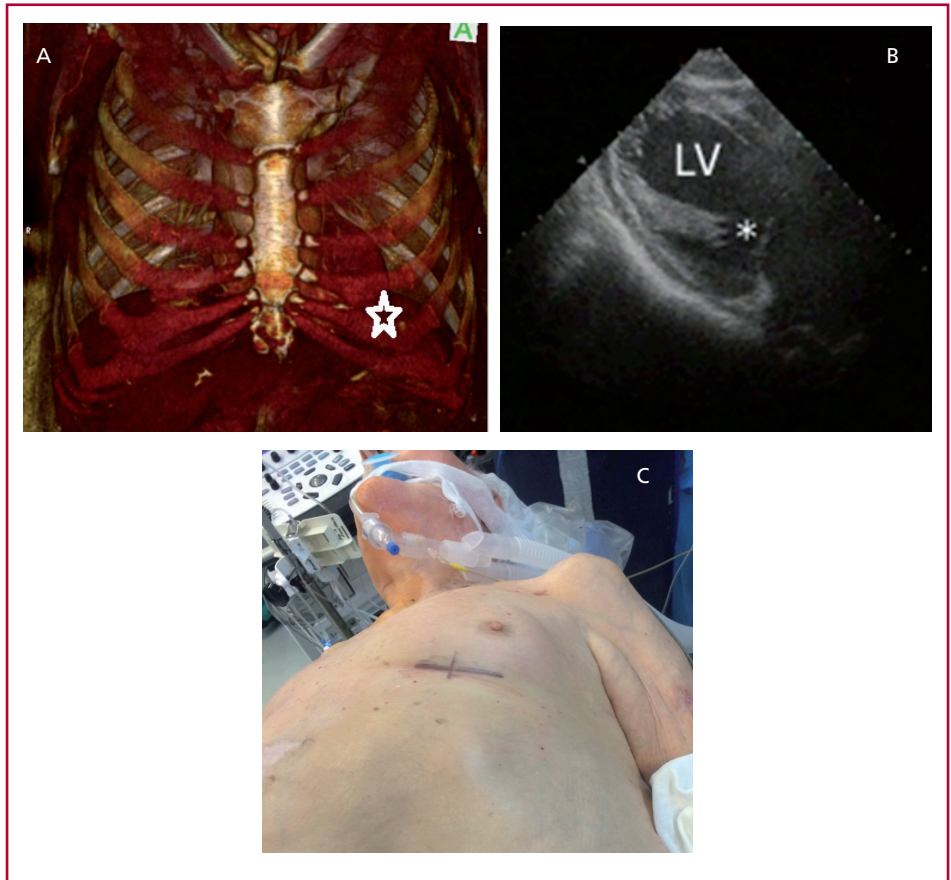
The direction of the puncture needle must be upwards, forwards and to the left, under X-ray control. The left shoulder may be taken as reference. The angle formed by the chord between the apex and the aortic valve plane should always be over 100 degrees, since as it approaches 180 degrees the prosthetic implantation will be easier. It is preferable to place epicardial electrodes of temporary pacemaker (Figure 3).

Placement and removal has two steps for each maneuver, since one is balloon valvuloplasty and the other the prosthesis introducer itself. In balloon valvuloplasty and in the removal of devices at the cardiac tip, the ventricle must always be stimulated at high frequency to generate a marked drop of blood pressure. This positions the balloon and avoids myocardial rupture. Figure 3 shows the implanted aortic Jenavalve™ prosthesis and the pigtail catheter ready for angiographic control. It also shows the relative position of the sternal retractor with the aortic valve plane. Before placing the pleural drainage, aspiration of the pleural cul-de-sac is recommended, as well as the use of soft, small size tubes. The cosmetic result at follow-up is excellent (Figure 4).

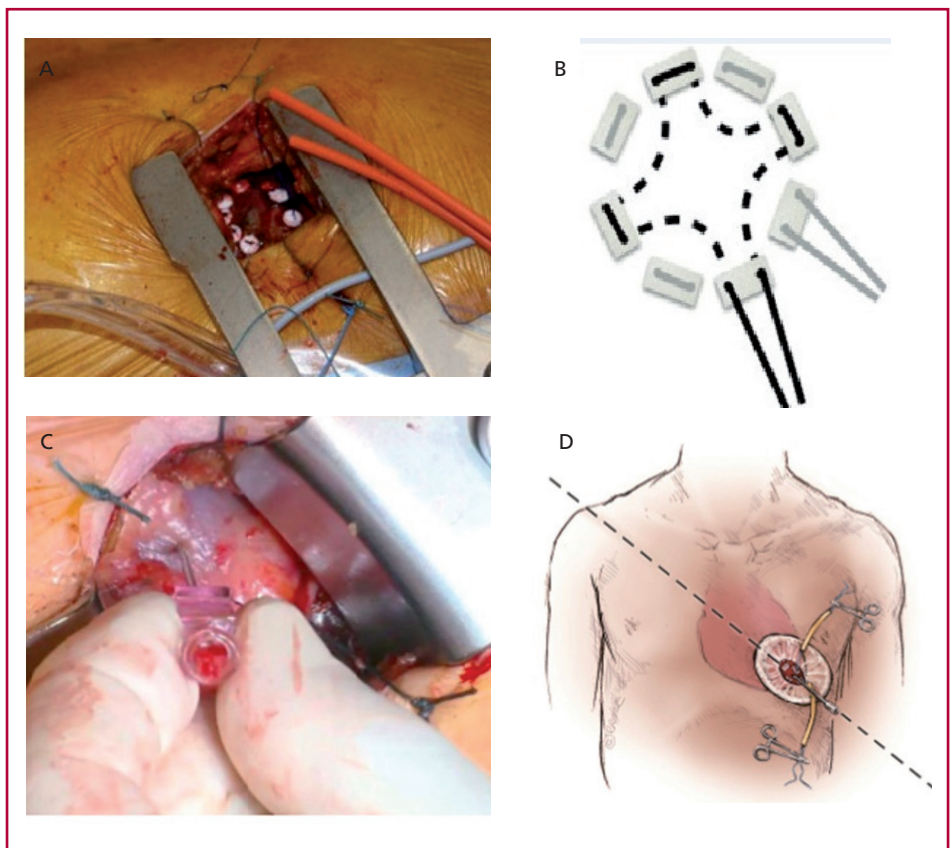
## Ethical considerations

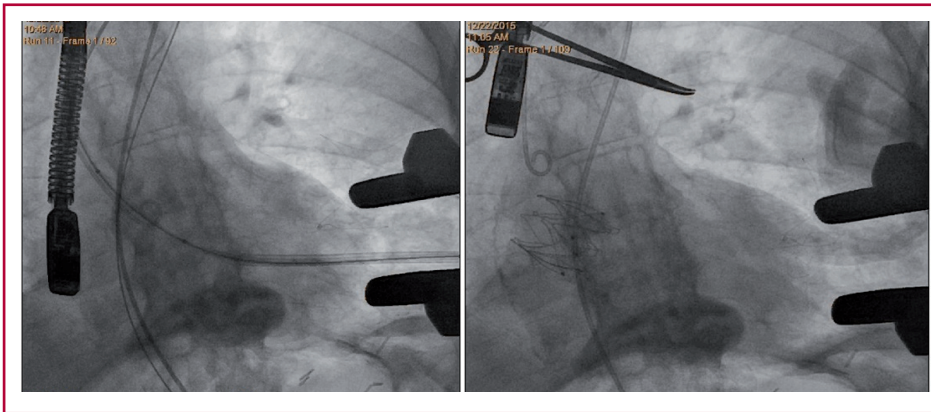
The study was evaluated and approved by the Institutional Review Board

**Fig. 1.** **A.** Diagram showing the thoracic position of the minithoracotomy. **B.** Echocardiographic position of the cardiac apex. **C.** Photograph of the incision at the apical level. LV: Left ventricle.

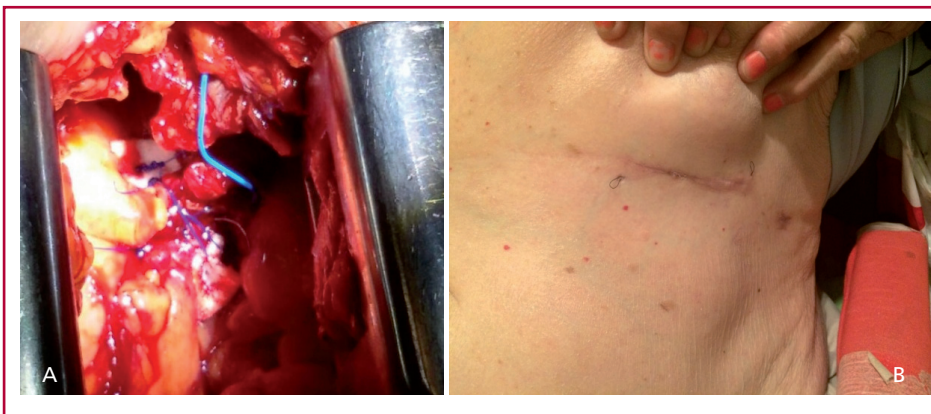


**Fig. 2.** **A.** Intraoperative photograph showing both purse-string sutures beside the cardiac apex. **B.** Diagram illustrating the configuration of purse-string sutures. **C.** Photograph of the incision at the center of the purse-string sutures. **D.** Diagram of the reference angle towards the right shoulder.





**Fig. 3. A.** X-ray image showing the location of the sheath through the transapical approach. **B.** X-ray image of the valve already positioned and deployed.



**Fig. 3. A.** Intraoperative photograph showing both sutures already tightened and the temporary pacemaker lead in situ. **B.** Incision scar 10 days after the procedure.

## RESULTS

Immediate procedural mortality was 10.7% (3/28), none attributable to the apical approach. There was only one intraoperative death due to inadequate prosthetic implant placement, with the prosthesis in sub-aortic intraventricular position and consequent severe shock. A second sudden unexplained death occurred 12 hours after the procedure. In this case, the valve implant controlled by Doppler echocardiography was correctly positioned. The third death was produced by cardiac arrest due to external pacemaker failure in a patient with complete atrioventricular (AV) block.

Immediate morbidity was 28.6% (8/28). Two major complications occurred with high bleeding volumes through the drainages, interpreted as ventricular purse-string suture leak. Only one patient required reintervention. The intraoperative finding was right ventricular perforation by temporary intraventricular pacemaker lead. The patient recovered, though he needed prolonged respiratory assistance. The other patient presented significant hemothorax with complete hemothorax haziness. It was resolved with aspiration with no hemodynamic involvement. The rest of the morbidities included a patient who developed significant subcutaneous emphysema with airway fistula requiring a week-long drainage with favorable outcome. Two patients with bundle branch block required permanent pacemaker. There were two car-

diac muscle ruptures during the procedure; one was resolved through the same access route and the other needed an extended thoracotomy. Only one transient ischemic attack occurred which regressed completely. No moderate/severe periprosthetic leaks were observed. No infection-related complications were recorded.

## DISCUSSION

The initial reason for this transapical approach originated from patients with TAVI indication and inadequate iliofemoral access due to obstruction or unsuitable femoral anatomy. (6) The present study shows its feasibility and the relatively low complications of the technique. The possibility of enabling easier management of the prosthetic application device with the valve annulus at a minimum distance implies that some interventional cardiologists consider the transapical approach as the procedure of choice. (7) It has been previously used to introduce the aortic perfusion cannula in surgical treatments of acute aortic dissection and in mitral commissurotomy. (8)

We should recall that the vascular femoral access may undergo serious complications. (9) The presentation of vascular occlusions, given the frail physical condition of this group of patients, may generate irreversible clinical situations. In the manipulation of these elderly patients with frequent vascular disease,

avoiding the aortic arch seems to decrease the number of neurological events. (10) Use of stiff temporary pacemakers may generate right ventricular perforation, especially with this technique that requires heart displacement. (11) The purse-string suture involving all the wall layers enables complete closure without unexpected tears difficult to resolve. (12, 13) This type of prosthetic valve design, due to its fixation system to the primitive valves, is not associated with high possibility of AV block compared with other devices, (14) and neither requires the routine indication of prior permanent pacemaker implantation. (15) No periprosthetic leak analysis was performed as this was not the purpose of the study and due to the acceptable patient outcome. There is some controversy in the literature regarding this point. Periprosthetic leak seems to be lower with this type of valve prostheses. (16, 17)

There is a tendency to incorporate moderate and low-risk patients for aortic valve replacement using this new technique. (18) The careful analysis of large multicenter studies should be considered before advancing in excess. (19) There is always the possibility of improving the technique (20) reducing the number of complications. (21) In addition, the transapical approach also allows treating other pathologies as endovascular treatment of thoracic aortic disease, closure of paravalvular leaks and even mitral valve repair with neo-chord implantation. (22-24)

## CONCLUSIONS

This study shows that the transapical surgical technique is feasible (25) and with an acceptable number of complications. This approach is not only applicable for the treatment of the aortic valve but also opens a wide path for other cardiovascular diseases. The development of ventricular occluding devices may simplify the technique. The contribution to development with completely percutaneous applications may constitute a valid future alternative.

## Conflicts of interest

None declared. (See authors' conflicts of interest forms in the website/Supplementary material).

## REFERENCES

1. Arsalan M, Szerlip M, Vemulapalli S, Holper EM, Arnold SV, Li Z, et al. Should transcatheter aortic valve replacement be performed in nonagenarians?: Insights from the STS/ACC TVT Registry. *J Am Coll Cardiol* 2016;67:1387-95. <http://doi.org/bqg8>
2. Thourani VH, Kodali S, Makkar RR, Herrmann HC, Williams M, Babaliaros V, et al. Transcatheter aortic valve replacement versus surgical valve replacement in intermediate-risk patients: a propensity score analysis. *Lancet* 2016;387:2218-25. <http://doi.org/bqg9>
3. Rosa VE, Lopes AS, Accorsi TA, Fernandes JR, Spina GS, Sampaio RO, et al. EuroSCORE II and STS as mortality predictors in patients undergoing TAVI. *Rev Assoc Med Bras (1992)* 2016;62:32-7. <http://doi.org/bqhb>
4. Cribier A, Eltchaninoff H, Bash A, Borenstein N, Tron C, Bauer F, et al. Percutaneous transcatheter implantation of an aortic valve prosthesis for calcific aortic stenosis: first human case description.

- Circulation* 2002;106:3006-8. <http://doi.org/cv6smx>
5. Mieres J, Menéndez M, Fernández-Pereira C, Rubio M, Rodríguez AE. Transapical implantation of a 2nd-generation JenaValve device in patient with extremely high surgical risk. *Case Rep Cardiol* 2015;2015:458151.
6. Walther T, Dewey T, Borger MA, Kempfert J, Linke A, Becht R, et al. Transapical aortic valve implantation: step by step. *Ann Thorac Surg* 2009;87:276-83. <http://doi.org/fn4mfk>
7. Shults C, Gunter R, Thourani VH. The versatility of transapical access: Will it lead to a completely new approach to valvular therapy? *Ann Cardiothorac Surg* 2012;1:220-3.
8. Sosnowski AW, Jutley RS, Masala N, Alexiou C, Swanevelde J. How I do it: transapical cannulation for acute type-A aortic dissection. *J Cardiothorac Surg* 2008;3:4. <http://doi.org/cw7fqr>
9. Rougé A, Huttin O, Aslam R, Vaugrenard T, Jouve T, Angioi M, et al. Mid-term results of 150 TAVI comparing apical versus femoral approaches. *J Cardiothorac Surg* 2015;10:147. <http://doi.org/bqhc>
10. Dewey TM, Bowers B, Thourani VH, Babaliaros V, Smith CR, Leon MB, et al. Transapical aortic valve replacement for severe aortic stenosis: results from the nonrandomized continued access cohort of the PARTNER trial. *Ann Thorac Surg* 2013;96:2083-9. <http://doi.org/bqhd>
11. Gomes WJ, Buffolo E. Perforation of the right ventricular wall by temporary pacemaker wire. *Tex Heart Inst J* 2004;31:457.
12. Wong DR, Ye J, Cheung A, Webb JG, Carere RG, Lichtenstein SV. Technical considerations to avoid pitfalls during transapical aortic valve implantation. *J Thorac Cardiovasc Surg* 2010;140:196-202.
13. Généreux P, Cohen DJ, Williams MR, Mack M, Kodali SK, Svensson LG, et al. Bleeding complications after surgical aortic valve replacement compared with transcatheter aortic valve replacement: insights from the PARTNER I Trial (Placement of Aortic Transcatheter Valve). *J Am Coll Cardiol* 2014;63:1100-9. <http://doi.org/f2qrmv>
14. Young Lee M, Chilakamarri Yeshwant S, Chava S, Lawrence Lustgarten D. Mechanisms of heart block after transcatheter aortic valve replacement- Cardiac anatomy, clinical predictors and mechanical factors that contribute to permanent pacemaker implantation. *Arrhythm Electrophysiol Rev* 2015;4:81-5.
15. Rahnavardi M, Santibanez J, Sian K, Yan TD. A systematic review of transapical aortic valve implantation. *Ann Cardiothorac Surg* 2012;1:116-28.
16. Barbash IM, Finkelstein A, Barsheshet A, Segev A, Steinvil A, Assali A, et al. Outcomes of patients at estimated low, intermediate, and high risk undergoing transcatheter aortic valve implantation for aortic stenosis. *Am J Cardiol* 2015;116:1916-22. <http://doi.org/bqhf>
17. Tarantini G, Gasparetto V, Napodano M, Fraccaro C, Gerosa G, Isabella G. Valvular leak after transcatheter aortic valve implantation: a clinician update on epidemiology, pathophysiology and clinical implications. *Am J Cardiovasc Dis* 2011;1:312-20.
18. PARTNER 2 Backs TAVR use in intermediate-risk patients with severe aortic stenosis. *Medscape*. Apr 02, 2016. <http://www.medscape.com/viewarticle/861378>
19. Spadaccio C, Fraldi M, Sablayrolles JL, Nappi F. TAVI in lower risk patients: Revolution or nonsense? Keep calm and select patients. *J Am Coll Cardiol* 2016;67:1380-1. <http://doi.org/bqhg>
20. Sipahi NF, Papadopoulos N, Moritz A, Zierer A. Linear closure of the left ventricular apex following transcatheter-based aortic valve implantation. *Thorac Cardiovasc Surg* 2015;63:508-9.
21. Bleiziffer S, Piazza N, Mazzitelli D, Opitz A, Bauernschmitt R, Lange R. Apical-access-related complications associated with transcatheter aortic valve implantation. *Eur J Cardiothorac Surg* 2011;40:469-74. <http://doi.org/cv6b9d>
22. Uthoff H, Garcia-Covarrubias L, Samuels S, Benenati JF, Moreno NL, Katzen BT. Transapical endovascular aortic repair to treat complex aortic pathologies. *Ann Thorac Surg* 2012;93:1735-7. <http://doi.org/bqhh>
23. Gaia DF, Breda JR, Fischer CH, Palma JH. Off-pump transapical closure of a mitral periprosthetic leak: a new approach to a difficult problem. *Interact Cardiovasc Thorac Surg* 2013;17:1048-50. <http://doi.org/bqhj>
24. Ibrahim M, Rao C, Athanasiou T. Artificial chordae for degenerative mitral valve disease: critical analysis of current techniques. *Interact Cardiovasc Thorac Surg* 2012;15:1019-32. <http://doi.org/bqhk>
25. Battelini R, Walther T, Kempert J, Borger M, Schuler S, Linke A, et al. Transapical Aortic Valve Implantation. *Rev Argent Cardiol* 2009;77:96-100.