

Balloon Cryoablation for Paroxysmal Atrial Fibrillation. Initial Experience

Crioablación con balón en fibrilación auricular paroxística. Experiencia inicial

JOSÉ L. GONZÁLEZ^{MTSAC}, NÉSTOR GALIZIO^{MTSAC}, ALEJANDRO A. PALAZZO[†], FEDERICO ROBLES, GUILLERMO CARNERO, MAURICIO MYSUTA

ABSTRACT

Background: Pulmonary vein isolation is the cornerstone for the treatment of patients with recurrent and symptomatic paroxysmal atrial fibrillation (PAF). Balloon cryoablation (BCA) is an option to radiofrequency with shorter procedural and fluoroscopy times.

Objectives: The aim of this study was to describe the immediate outcomes and the initial experience in the first BCA procedures for PAF in our hospital.

Methods: Between November 2013 and February 2015, 23 patients underwent BCA for PAF. A computed tomography angiography with reconstruction of the left atrium and pulmonary veins was performed before the procedure.

Results: Mean age was 53 ± 11 years, 19 patients were men, left atrial dimension was 40 ± 7 mm and LVEF was $58\% \pm 8\%$. Average CHA₂DS₂VASc score was 0.6. The average procedural time was 169 ± 47 minutes, with a fluoroscopy time of 39 ± 17 minutes. Isolation of the pulmonary veins was achieved in 89/91 pulmonary veins (97.8%), and 2 patients required additional radiofrequency catheter ablation. One patient (4.34%) presented transient paralysis of the diaphragm with spontaneous recovery after 30 minutes. No further complications were observed.

After a median follow-up of 9.2 months, 21 patients (91.3%) remained with sinus rhythm.

Conclusions: In this initial experience, BCA for PAF proved to be a safe and effective technique in selected patients. A high acute success rate was achieved for pulmonary vein isolation. During follow-up, the recurrence rate was low. The real impact of the procedure will be known when long-term outcomes become available.

Key words: Atrial Fibrillation - Catheter Ablation - Cryosurgery - Electrophysiology

RESUMEN

Introducción: El aislamiento eléctrico de las venas pulmonares constituye la piedra angular en el tratamiento curativo de pacientes con fibrilación auricular paroxística (FAP) recurrente y sintomática. La crioablación con balón (CAB) es una alternativa a la radiofrecuencia, con disminución de los tiempos del procedimiento y de radioscopia.

Objetivos: Describir los resultados inmediatos y la experiencia inicial en las primeras intervenciones de CAB de FAP en nuestro hospital.

Material y métodos: Entre noviembre de 2013 y febrero de 2015, 23 pacientes fueron intervenidos con una CAB de FAP. Previo al procedimiento se les realizó una angiotomografía con reconstrucción de la aurícula izquierda y las venas pulmonares.

Resultados: La edad promedio de los pacientes fue de 53 ± 11 años, 19 eran varones, el diámetro de la aurícula izquierda fue de 40 ± 7 mm, la FEVI fue de $58\% \pm 8\%$. El CHA₂DS₂VASc promedio fue de 0,6. La duración promedio de los procedimientos fue de 169 ± 47 minutos, con un tiempo de radioscopia de 39 ± 17 minutos. Se logró el aislamiento en 89/91 venas pulmonares (97,8%); en 2 pacientes se debió completar la lesión con radiofrecuencia. Un paciente (4,34%) presentó parálisis diafragmática transitoria, con recuperación espontánea a los 30 minutos. No hubo otras complicaciones.

Con una mediana de seguimiento de 9,2 meses, 21 pacientes (91,3%) permanecieron en ritmo sinusal.

Conclusiones: En esta experiencia inicial, la CAB de FAP se mostró como una técnica segura y eficaz en pacientes seleccionados. Presentó un éxito agudo alto en el aislamiento de las venas pulmonares. Durante el seguimiento, la tasa de recurrencia fue baja. Resta esperar los resultados del seguimiento extendido para conocer su impacto real.

Palabras clave: Fibrilación auricular - Ablación con catéter - Criocirugía - Electrofisiología

REV ARGENT CARDIOL 2015;83:424-428. <http://dx.doi.org/10.7775/rac.v83.i5.6234>

SEE RELATED ARTICLE: Rev Argent Cardiol 2015;83:424-428. <http://dx.doi.org/10.7775/rac.v83.i5.7264>

Received: 04/08/2015 - Accepted: 07/14/2015

Address for reprints: Dr. Alejandro A. Palazzo - Hospital Universitario Fundación Favaloro - Av. Belgrano 1782 - (C1093AAS) Buenos Aires, Argentina - Phone (54-11) 4378-1200/1300 extension 3660/3650 - e-mail: alejandropalazzo@hotmail.com

Hospital Universitario Fundación Favaloro. Buenos Aires, Argentina.

^{MTSAC} Full Member of the Argentine Society of Cardiology

[†] To apply as Full Member of the Argentine Society of Cardiology

Abbreviations

LA	Left atrium	PAF	Paroxysmal atrial fibrillation
CT-Angio	Computed tomography angiography	LVEF	Left ventricular ejection fraction
PVI	Pulmonary vein isolation	RF	Radiofrequency
BCA	Balloon cryoablation	INR	International normalized ratio
ECG	Electrocardiogram	ET	Esophageal temperature
AF	Atrial fibrillation		

INTRODUCTION

Atrial fibrillation (AF) is the most prevalent arrhythmia (1-2%) in the general population and raises more than 5 times the risk of stroke, affecting quality of life and increasing morbidity and mortality. (1, 2) The electrical isolation of the pulmonary veins or of other AF triggers is a therapeutic intervention for patients with paroxysmal atrial fibrillation (PAF) who remain with symptoms after medical treatment, decreasing the number of hospitalizations and improving survival. (3-5)

Point-by-point radiofrequency (RF) ablation for pulmonary vein isolation (PVI) has shown considerable success for the treatment of PAF, (6, 7) but is associated with major complications as thromboembolic events, cardiac tamponade, lesions of organs or adjacent structures (esophagus, phrenic nerve or aorta) and pulmonary vein stenosis. (6-10) The procedure is complex, takes a long time and the long-term outcomes depend mainly on the operator's experience to achieve a linear lesion without gaps. (11)

Balloon cryoablation (BCA) for PAF is a recently introduced technology, with shorter procedural and fluoroscopy times and with efficacy similar to that obtained with RF. (11, 12) Cryoablation has also demonstrated lower incidence of thrombus formation (endothelial cell preservation) and better limited lesions which improve catheter stability due to enhanced tissue contact. (13-16) However, cryoablation has not proved to be safer than RF catheter ablation, adding an almost exclusive complication, the prevalence of phrenic nerve lesion which ranges from 11% to 24%, and may lead to persistent diaphragmatic paralysis. (11, 17, 18)

The aim of this study was to describe the immediate outcomes and the initial experience in the first BCA procedures in our hospital.

METHODS

Between November 2013 and February 2015, 23 BCA procedures were performed in 23 patients with symptomatic and refractory PAF (with at least one antiarrhythmic drug). All patients had presented more than two episodes of PAF within the past 3 months.

A computed tomography angiography (CT-Angio) with reconstruction of the left atrium (LA) and pulmonary veins (PV) was performed for patient selection. Two operators evaluated the results and excluded those patients with unfavorable anatomy, as common ostium diameter larger than the balloon, a sharp and deep left lateral ridge between the left atrial appendage and left PV or multiple, thin PV.

Patients with LA size ≥ 5 cm, left ventricular ejection fraction (LVEF) $\leq 40\%$, functional class III heart failure or greater, coronary artery disease requiring invasive treatment or history of stroke within the previous 6 months were excluded from the study.

All the patients were receiving anticoagulation therapy with warfarin and had a stable INR between 2 and 3 for at least one month before BCA. Warfarin was replaced by low-molecular-weight heparin on the days before the procedure. Antiarrhythmic drugs were stopped before BCA. Both drugs were reinitiated 8 hours after the procedure and continued for 3 months.

None of the patients underwent prior transesophageal echocardiography.

The procedure was performed under general anesthesia avoiding the use of muscle relaxants, with invasive blood pressure and esophageal temperature (ET) monitoring. Transseptal puncture, performed using a conventional puncture set, was guided by fluoroscopy. The LA was accessed and a 0.035" in diameter and 260 cm in length guide wire was advanced into the left superior PV. Then, it was exchanged for a FlexCath sheath; the balloon catheter was advanced over the sheath with the circular mapping catheter (Achieve, Medtronic Inc.) inside the sheath. During LA approach, the activated clotting time ranged between 250 and 300 milliseconds. Total procedure time was defined as the time interval between patient arrival at the electrophysiology laboratory until the puncture sites were bandaged.

Ablation was performed using a 28-mm first-generation or second-generation balloon catheter (Artic Front and Artic Front Advance Medtronic Inc., respectively).

Before starting BCA, a circular mapping catheter was introduced inside each PV to detect the presence of spontaneous electrical potentials. The need for isolating a PV was determined by left atrial capture during sinus rhythm when that pulmonary vein was paced or by the presence of spontaneous electrical potentials. The balloon catheter was inflated inside the LA and advanced towards the PV ostium, guided by the circular mapping catheter inside the PV. In the first 20 patients, each PV underwent two cycles of 240 seconds after venographic evidence of full occlusion without leak detection and a fall in balloon temperature of -30°C in 30 seconds. In the last 3 cases, each PV received a single application.

Esophageal temperature was controlled during each application, and was stopped if the temperature was -25°C or lower (Figure 1).

During the applications in the right PV, the phrenic nerve was monitored with high-output pacing (20 mV at 1200 ms) and phrenic nerve capture (contraction of the diaphragm) using a catheter placed in the right side of the superior vena cava. The application was immediately interrupted if diaphragmatic contraction ceased or decreased (Figure 2).

Immediately after BCA of each PV, and 30 minutes later, the absence of spontaneous electrical potentials and the presence of bidirectional block (absence of PV potentials and

of LA capture from the PV ostium) during sinus rhythm, were considered primary success findings.

The patients were followed-up at the outpatient clinic 48 hours and 30 days after the procedure (clinical exam and electrocardiogram [ECG]), and at 3, 6 and 12 months (clinical exam, ECG and 24-hour 3-channel Holter monitoring).

Antiarrhythmic drugs and anticoagulants were started again in the immediate postoperative period and maintained during the first 3 months (the blanking period after an AF

intervention), and were subsequently withdrawn. Atrial fibrillation recurrence was defined as the presence of AF lasting at least 30 seconds in any of the follow-up visits after the intervention (ECG or Holter monitoring).

Statistical analysis

The results are expressed as mean ± standard deviation or percentage of patients, median and interquartile range. The procedure was considered successful if PVI was achieved with absence of AF during follow-up.

Ethical considerations

The study protocol was revised and approved by the Institutional Bioethics Committee. All patients signed an informed consent before BCA.

RESULTS

Mean age was 53±11 years and 19 patients were men. Average CHA₂DS₂VASc score was 0.6. Mean LA size was 40±7 mm and LVEF was 58%±8%. Ninety-five percent of the patients had four PV with separate openings into the LA, and one patient had a common trunk of the left pulmonary vein (Table 1).

The Artic Front catheter was used in 12 patients (52%) and the Artic Front Advance in 11 (48%).

Mean procedural time was 169±47 minutes, with fluoroscopy time of 39±17 minutes. As the number of cases increased and the operator’s experience improved, a trend towards a reduction in both times was observed (Figure 3).

All the patients were hospitalized for one day.

Electrical isolation and bidirectional block was achieved with BCA in 89 of 91 PV (97.8%). In two patients, PVI had to be completed with RF ablation using a 4 mm irrigated tip catheter under fluoroscopic guidance: in one patient in the right inferior PV and in the other patient in the left inferior PV.

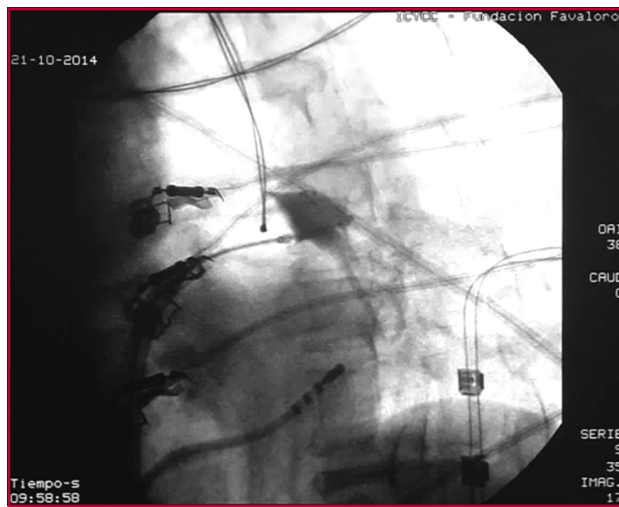


Fig. 1. Venogram of the left superior pulmonary vein. Contrast injection after balloon occlusion of the left superior pulmonary vein is observed with no evidence of contrast leakage. The esophageal temperature probe can be seen close to the site of cryoablation application.

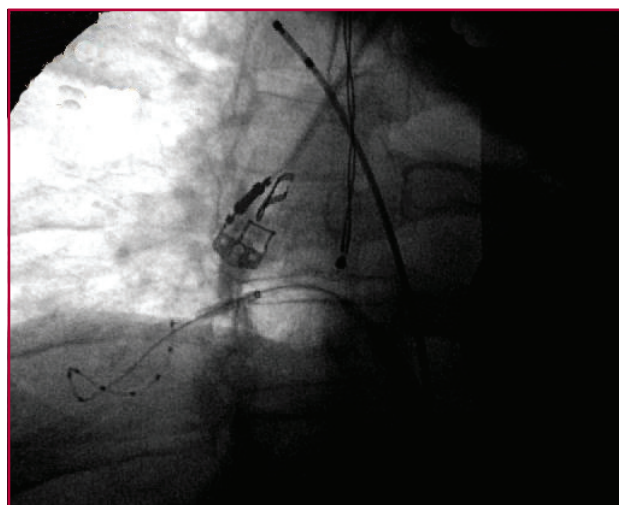


Fig. 2. Venogram of the right inferior pulmonary vein. Contrast injection after balloon occlusion of the right inferior pulmonary vein is observed. The circular mapping catheter is seen deployed and distal to the ostium, which, in this case, provides support for the adequate contact of the balloon with the right inferior pulmonary vein ostium. The bipolar catheter can be seen in the superior vena cava (where phrenic capture is revealed through stimulation) and the esophageal temperature probe placed close to the site of cryoablation application.

Table 1. Baseline characteristics

n=23	
Age, years	53±11
Male gender, %	82
HTN, %	39
AMI, %	13
DM, %	8
Stroke, %	4
Left atrium, mm	40±7
LVEF, %	58±8
PV size, mm	
RSPV	20±2
RIPV	17±1.5
LSPV	16±1.2
LIPV	14±1.4

HTN: Hypertension. AMI: Acute myocardial infarction. DM: Diabetes mellitus. LVEF: Left ventricular ejection fraction. PV: pulmonary vein. RSPV: Right superior pulmonary vein. RIPV: Right inferior pulmonary vein. LSPV: Left superior pulmonary vein. LIPV: Left inferior pulmonary vein.

One patient (4.34%) presented transient paralysis of the diaphragm during BCA of the right superior PV (using a second-generation balloon) that did not prevent PVI and showed spontaneous recovery after 30 minutes. Esophageal temperature presented a marked reduction during BCA of the left inferior PV in two patients (using a second-generation balloon). Cryoablation was terminated to prevent esophageal injury; nevertheless, PVI was successful and no complications were reported during follow-up.

During a median follow-up of 9.2 months (IQR 25%-75%=5.5), 91.3% of patients did not present AF recurrences (Table 2).

DISCUSSION

Balloon cryoablation for PAF is a technique developed to facilitate PVI in certain difficult cases. In our series, PVI was achieved in 97.8% of cases, a result similar to the one reported by international publications (Andrade et al, average primary success of 98.4%), (11) and to the outcomes attained with RF in our country. (19, 20)

Only a few patients completed more than one-year follow-up. International publications did not find differences in AF recurrence one year after ablation with RF ablation or BCA procedures using first-generation balloons (RF 77% vs. BCA 72%), (21) however, the use of second-generation CAB resulted in lower rate of AF recurrence compared with RF in the long-term follow-

up (76% vs. 60%, respectively). (22)

Despite being the beginning of the learning curve, the mean procedural time was similar to the ones previously reported. The FAST-PVI study comparing AF ablation using non-fluoroscopic navigation systems vs. BCA included more than 400 procedures in 9 centers in Germany. The study, designed to evaluate hospital costs and procedure times, showed that BCA is faster, reducing total times by 36% with average lab occupancy of 262 minutes for 3D navigation versus 170 minutes for BCA. (23)

In this series, the incidence of transient phrenic nerve paralysis was 4.3% using a second-generation balloon. In the STOP AF trial, Packer et al. (17) described an incidence of 11.2% transient and <1% persistent phrenic nerve palsy in 163 patients with first-generation balloons; with the advent of diaphragmatic monitoring by means of pacing during the application, this complication decreased to 6%. (11) Phrenic nerve paralysis has been reported to occur in a significantly larger number of patients (19.5%) with second-generation balloons. This complication might be prevented by avoiding the pulmonary vein ostia during right-sided pulmonary vein ablation and allowing a small degree of contrast leak. (18)

Despite the application had to be stopped in two patients due to a marked decrease in ET, pulmonary vein isolation was successful. The occurrence of atrial-esophageal fistula has been described with first-generation (24) and second-generation balloons. (25) The incidence of esophageal ulcers is higher with second-generation balloons and has a direct association with esophageal cooling. (26)

Pulmonary vein isolation was not achieved in two patients who required additional RF catheter ablation. Both failures were observed using a first-generation balloon; in one case, in the right inferior PV which presented a branch with a different orientation and proximal to the PV ostium, while in the second case, the reason for failure in the left inferior PV could not be recognized. The limitations to achieve PVI using first-generation balloons, which include anatomical variations in the PV and the LA (sharp left lateral ridge between the left superior PV and the left atrial appendage, a narrow carina between the left PV, a proximal non-perpendicular angle between the axis of the right inferior PV and the ostial plane and early branching PV with change in the axis angle) could be identified as predictors for failure in PVI. (27) Imaging techniques might be necessary to evaluate these variations. Probably, the use of second-generation balloons would overcome these limitations, as they use 8 injection tubes to produce lesions with the entire anterior hemisphere and not with the equator of the balloon as first-generation balloons do.

Study limitations

The follow-up period in this series was short, particularly considering that the presence or absence of ar-

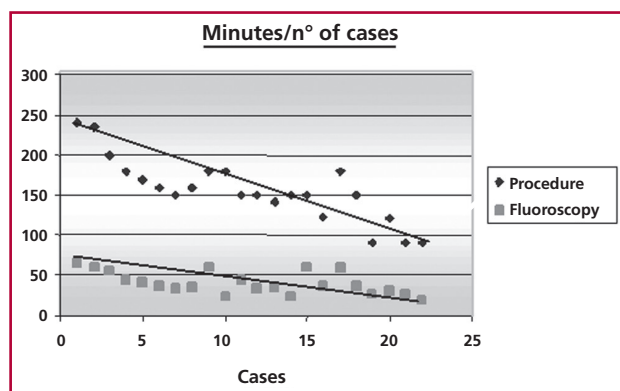


Fig. 3. Relationship between the procedure time and the number of cases.

Table 2. Series results

Procedure time, min	169±47
Fluoroscopy time, min	39±17
Transient phrenic palsy, %	4.34
Hospital length of stay, days	1
PV isolation, %	97.8
First-generation balloon, %	52
Follow-up (median), months	9.2
Recurrence, %	8.7

PV: pulmonary veins.

rhythmias during the 3-month blanking period after AF ablation does not modify the outcome. Selection of patients after CT-angiography limited results to patients with similar characteristics.

CONCLUSIONS

In this initial experience, BCA for PAF proved to be a safe and effective technique in selected patients. A high acute success rate was achieved for PVI. During follow-up, the recurrence rate was low. The real impact of the procedure will be known when long-term outcomes become available.

Conflicts of interest

None declared

(See author's conflicts of interest forms in the web / Supplementary Material)

REFERENCES

1. Wolf PA, Abbott RD, Kannel WB. Atrial fibrillation: a major contributor to stroke in the elderly. The Framingham Study. *Arch Intern Med* 1987;147:1561-4. <http://doi.org/d8mjkr>
2. Wang TJ, Larson MG, Levy D, Vasani RS, Leip EP, Wolf PA, et al. Temporal relations of atrial fibrillation and congestive heart failure and their joint influence on mortality: the Framingham Heart Study. *Circulation* 2003;107:2920-5. <http://doi.org/c2m7hq>
3. Bunch TJ, Crandall BG, Weiss JP, May HT, Bair TL, Osborn JS, et al. Patients treated with catheter ablation for atrial fibrillation have long-term rates of death, stroke, and dementia similar to patients without atrial fibrillation. *J Cardiovasc Electrophysiol* 2011;22:839-45. <http://doi.org/cvv6fs>
4. Piccini JP, Lopes RD, Kong MH, Hasselblad V, Jackson K, Al-Khatib SM. Pulmonary vein isolation for the maintenance of sinus rhythm in patients with atrial fibrillation: a meta-analysis of randomized, controlled trials. *Circ Arrhythm Electrophysiol* 2009;2:626-33. <http://doi.org/c8bq9n>
5. Wokhlu A, Monahan KH, Hodge DO, Asirvatham SJ, Friedman PA, Munger TM, et al. Long-term quality of life after ablation of atrial fibrillation: the impact of recurrence, symptom relief, and placebo effect. *J Am Coll Cardiol* 2010;55:2308-16. <http://doi.org/dp4zrv>
6. Natale A, Raviele A, Arentz T, Calkins H, Chen SA, Haissaguerre M. Venice Chart international consensus document on atrial fibrillation ablation. *J Cardiovasc Electrophysiol* 2007;18:560-80. <http://doi.org/ck3982>
7. Calkins H, Brugada J, Packer DL, Cappato R, Chen SA, Crijns HJ, HRS/EHRA/ECAS expert Consensus Statement on catheter and surgical ablation of atrial fibrillation: recommendations for personnel, policy, procedures and follow-up. *Heart Rhythm* 2007;4:816-61. <http://doi.org/frdqkg>
8. Dagues N, Hindricks G, Kottkamp H, Sommer P, Gaspar T, Bode K. Complications of atrial fibrillation ablation in a high-volume center in 1,000 procedures: still cause for concern? *J Cardiovasc Electrophysiol* 2009;20:1014-9. <http://doi.org/bmd87g>
9. Cappato R, Calkins H, Chen SA, Davies W, Lesaka Y, Kalman J. Updated worldwide survey on the methods, efficacy, and safety of catheter ablation for human atrial fibrillation. *Circ Arrhythm Electrophysiol* 2010;3:32-8. <http://doi.org/fcn658>
10. Calkins H, Reynolds MR, Spector P, Sondhi M, Xu Y, Martin A. Treatment of atrial fibrillation with antiarrhythmic drugs or radiofrequency ablation: two systematic literature reviews and meta-analyses. *Circ Arrhythm Electrophysiol* 2009;2:349-61. <http://doi.org/djsfz2>
11. Andrade J, Khairy P, Guerra P, Deyell M, Rivard L, Dubuc M. Efficacy and safety of cryoballoon ablation for atrial fibrillation: A systematic review of published studies. *Heart Rhythm* 2011;8:1444-51. <http://doi.org/fscbq7>
12. Linhart M, Bellmann B, Mittmann-Braun E, Schrichele JW, Bitzen A, Andrié R, et al. A Comparison of cryoballoon and radiofrequency ablation of pulmonary veins in 40 patients with paroxysmal atrial fibrillation: A case-control study. *Cardiovasc Electrophysiol* 2009;20:1343-8. <http://doi.org/bfhpb7>
13. Khairy P, Chauvet P, Lehmann J, Lambert J, Macle L, Tanguay JF. Lower incidence of thrombus formation with cryoenergy versus radiofrequency catheter ablation. *Circulation* 2003;107:2045-50. <http://doi.org/c6j2fm>
14. Khairy P, Dubuc M. Transcatheter cryoablation part I: preclinical experience. *Pacing Clin Electrophysiol* 2008;31:112-20. <http://doi.org/d5t2fk>
15. Lemola K, Dubuc M, Khairy P. Transcatheter cryoablation part II: clinical utility. *Pacing Clin Electrophysiol* 2008;31:235-44. <http://doi.org/c6wdw4>
16. Sarabanda AV, Bunch TJ, Johnson SB, Mahapatra S, Milton M, Leite L. Efficacy and safety of circumferential pulmonary vein isolation using a novel cryothermal balloon ablation system. *J Am Coll Cardiol* 2005;46:1902-12. <http://doi.org/dnpdtt>
17. Packer D, Kowall RC, Wheelam KR, Irwin J, Ruskin J. Cryoballoon ablation of pulmonary veins for paroxysmal atrial fibrillation: first results of the North American Arctic Front (STOP AF) pivotal trial. *J Am Coll Cardiol* 2013;61:1713-23. <http://doi.org/f2m68n>
18. Casado-Arroyo R, Chierchia GB, Conte G. Phrenic nerve paralysis during cryoballoon ablation for atrial fibrillation: A comparison between the first- and second-generation balloon. *Heart Rhythm* 2013;10:1318-24. <http://doi.org/578>
19. Labadet C, Dubner S, Hadid C, Azocar D, Di Toro D, Valsechi C. Efficacy and Safety of Radiofrequency Catheter Ablation in Patients with Atrial Fibrillation. *Rev Argent Cardiol* 2014;82:285-91. <http://doi.org/576>
20. Scazzuso F, Rivera S, Sammartino, V, Albina G, Laiño R, Giniger A. Pulmonary Vein Isolation for Treatment of Atrial Fibrillation. *Rev Argent Cardiol* 2012;80:21-6.
21. Kojodjojo P, O'Neill MD, Lim PB, Malcolm-Lawes L, Whinnett ZI, Salukhe TV. Pulmonary venous isolation by antral ablation with a large cryoballoon for treatment of paroxysmal and persistent atrial fibrillation: medium-term outcomes and non-randomised comparison with pulmonary venous isolation by radiofrequency ablation. *Heart* 2010;96:1379-84. <http://doi.org/cnzzh2>
22. Aryana A, Singh SM, Kowalski M, Pujara D, Cohen A, Singh SK. Acute and Long-term outcomes of ablation of atrial fibrillation using the second-generation cryoballoon versus open-irrigated radiofrequency: A multicenter experience. *J Cardiovasc Electrophysiol* 2015 Apr 27 [Epub ahead of print] <http://doi.org/577>
23. Klein G, Lickfett L, Schreieck J. Comparison of 'Anatomically designed' and 'Point-by-point' Catheter Ablations for Human Atrial Fibrillation in terms of procedure timing and costs in German hospitals. *FAST-PVI Study. Europace* 2015;17:1030-7. <http://doi.org/579>
24. Stockigt F, Schirckel JW, Andrié R, Lickfett L. Atrioesophageal fistula after cryoballoon pulmonary vein isolation. *J Cardiovasc Electrophysiol* 2012;23:1254-7. <http://doi.org/58b>
25. Lim HW, Cogert GA, Cameron CS, Cheng VY, Sandler DA. Atrioesophageal fistula during cryoballoon ablation for atrial fibrillation. *J Cardiovasc Electrophysiol* 2014;25:208-13. <http://doi.org/58c>
26. Fürnkranz A, Bordignon S, Schmidt B, Böhmig M, Böhrer MC, Bode F, et al. Luminal esophageal temperature predicts esophageal lesions after second-generation cryoballoon pulmonary vein isolation. *Heart Rhythm* 2013;10:789-93. <http://doi.org/58d>
27. Knecht S, Kuhne M, Altmann D. Anatomical predictors for acute and mid-term success of cryoballoon ablation of atrial fibrillation using the 28 mm balloon. *J Cardiovasc Electrophysiol* 2013;24:132-8. <http://doi.org/58f>