

Original paper

Why Ozone Therapy in Multiple Sclerosis?

Dr. Vincenzo Simonetti

Dr. William Liboni

Prof. Filippo Molinari

Keywords

Ozone therapy

Abstract

Ozone (O₃), an allotrope of the Oxygen (O₂), is normally present in atmosphere and it preserves us from solar ultraviolet rays. It was used for first time like antiseptic during First World War. In '30 years Payr⁸² extends its use to other diseases too. The same period it ascends the use of ozone for drinking in important citis, like Zurich, Marseilles, Singapore, Florence, Moscow, Konstanz.

It has been shown ozone has an immunostimulatory effect at low concentration (20-35 µg/ml), while it is immunosoppressive if it is used at high concentration (45-65 µg/ml)⁶⁰.

In 2002 Marx and Bardi¹⁴ have demonstrated like in nature IgG excised a bactericidal action releasing O₃.

Suggestion on how to quote this paper:

Simonetti, V.; Liboni, W.; Molinari, F. (2014). Why Ozone Therapy in Multiple Sclerosis?. *Revista Española de Ozonoterapia*. Vol. 4, nº 1, pp. 51-68.


Rational of therapy

Ozone (O_3), an allotrope of the Oxygen (O_2), is normally present in atmosphere and it preserves us from solar ultraviolet rays. It was used for first time like antiseptic during First World War. In '30 years Payr ⁸² extends its use to other diseases too. The same period it ascends the use of ozone for drinking in important cities, like Zurich, Marseilles, Singapore, Florence, Moscow, Konstanz.

It has been shown ozone has an immunostimulatory effect at low concentration (20-35 $\mu\text{g/ml}$), while it is immunosuppressive if it is used at high concentration (45-65 $\mu\text{g/ml}$) ⁶⁰.

In 2002 Marx and Bardi ¹⁴ have demonstrated like in nature IgG exercised a bactericidal action releasing O_3 .

More Chemical Evidence for an Antibody Killing Mechanism



Way of ABOx in human neutrophils: antibodies create, while oxidation way of water, (H_2O_2 and O_3) both with bactericide effect, for action of phagocyte oxidase (Phox), myeloperoxidase (MPO) and IgG. Picture with E.M. of bacterium E. Coli killed by antibody with way of the water oxidation: it's important morphology of breaking of cell wall and membrane after fagocytosis.

Bardi JS. News and Views; The Scripps Research Institute 2002

Numerous articles have largely described anti-inflammatory effects ³⁴, analgesic ³⁸, antibacterial ^{20,40-42,49,53,54,78,80}, virus-static ^{17,27,66,67} and perfusion improvement of microcirculation ⁵⁹, in addition to the subsequent disappearance of ischemic pain, the functional recovery of muscle and joint groups, the healing of trophic ulcers ^{62,64}; these effects contribute significantly to improve the quality of patients' life, to make the most effective many pharmacological or rehabilitation therapy, to repair some iatrogenic damages ^{15,16,19,36,48,58,65}.

In a study that we presented to IV world congress oxygen ozone therapy Rome 26-28 September 2013, using NIRS technology (Near Infra Red Signal), we have shown in 50 patients (part of healthy part with various brain disorders and with MS), an increase of activity on the signal of neurons cyt-c (Cytochrome-c-oxidase) 40 minutes after the end of reinfusion; it

demonstrates that ozone, activating mitochondrial metabolism with recovery of cyt-c in di brain reduces oxidative stress chronic. This effect was particularly evident in MS group due to the initial condition of hyper-oxidative stress and to lower levels of basal cyt-c. We believe that ozone may favor also the reduction of states of chronic oxidative stress at the basis of other neuro-vegetative diseases. The average values of cerebral oxygenation, measured by NIRS, are shown in the graph below. The NIRS technique allows measuring relative rather than absolute magnitude. Therefore, all the values reported, are reported at the initial monitoring, said “zero” instant.

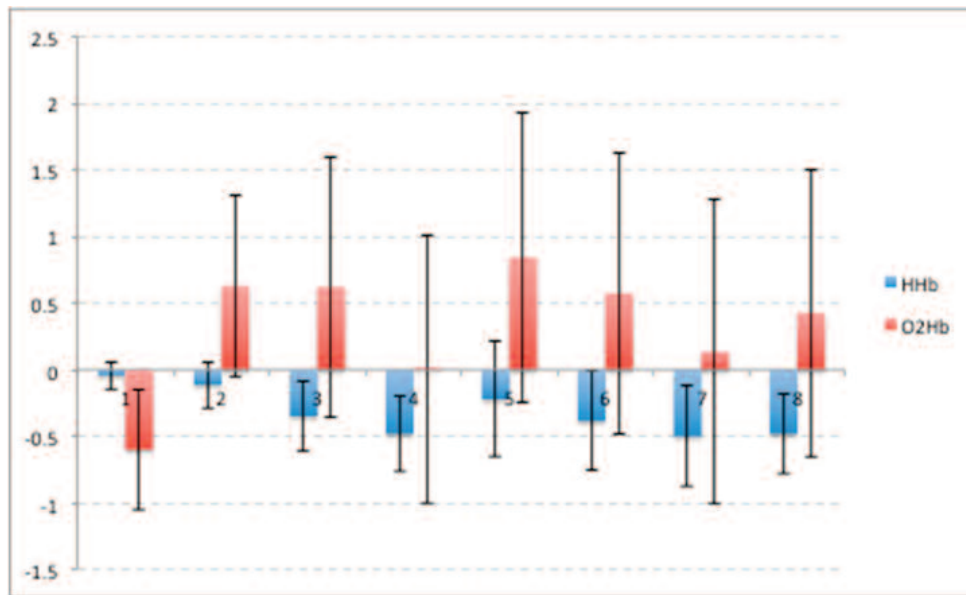
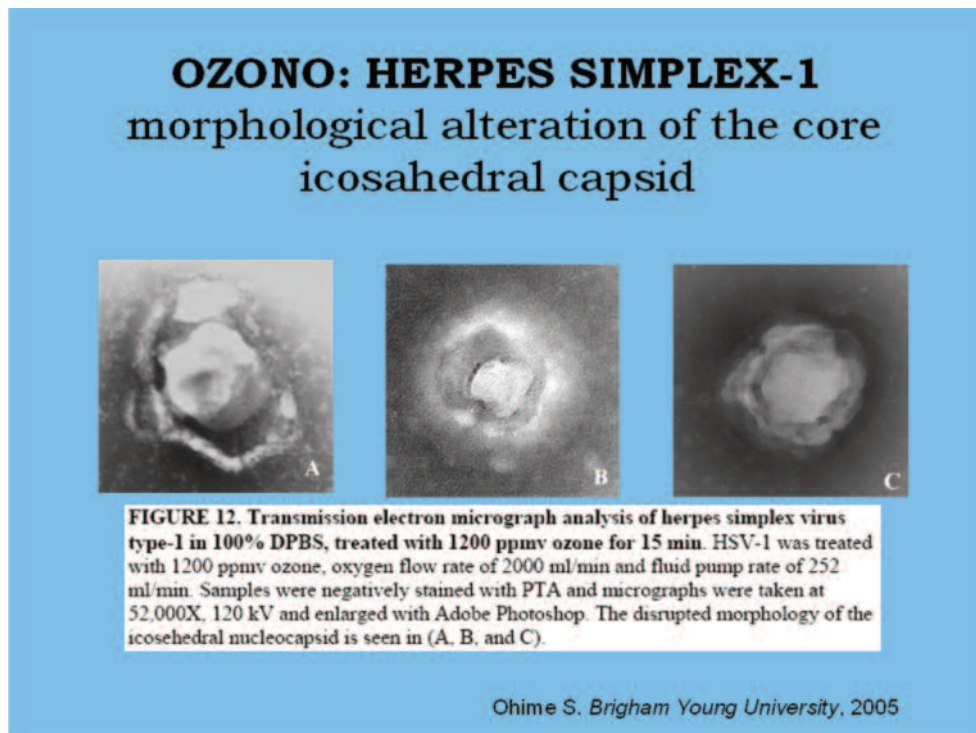


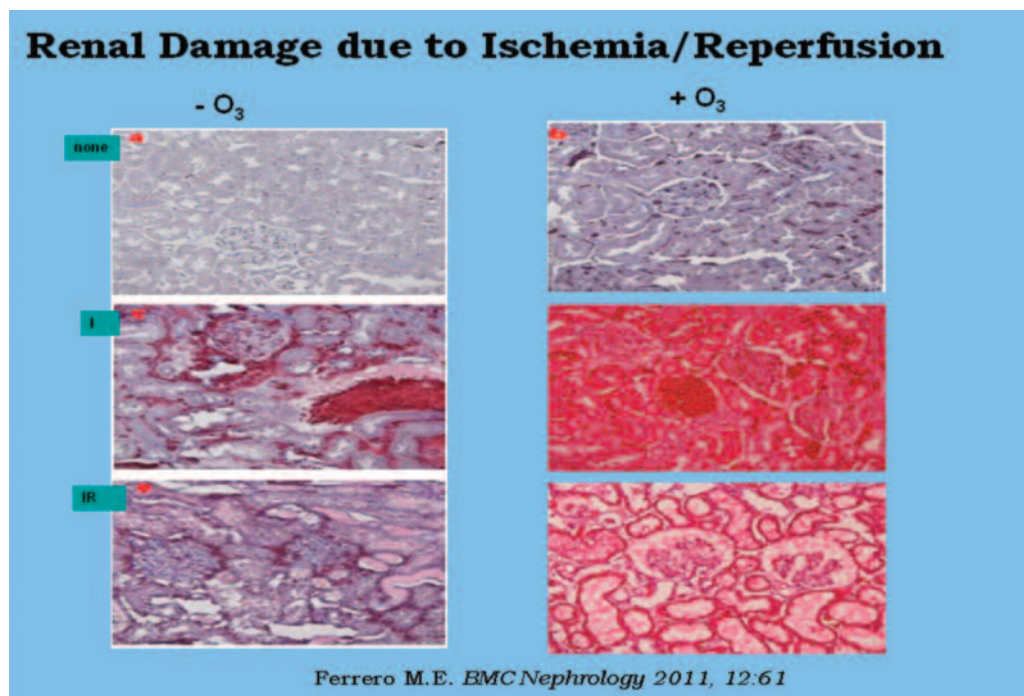
Figure 1 Mean values of relative concentration of O₂Hb (red) and HHb (blue) in the eight windows of protocol analysis to monitoring of long-term effects. The error bars represent the standard error.

Figure 1 shows the time course of O₂Hb and HHb concentration in the eight slots listed above. You can see how starting from the window V in particular (corresponding to 20 minutes after reinfusion), the concentration of oxygenated hemoglobin has a marked increase. Concentration of O₂Hb in V window is the first to be statistically superior than in I window (initial baseline) (Student test, $p < 0.05$). The concentration of deoxygenated hemoglobin HHb is decreasing since the beginning of the protocol. Already in III window (beginning of reinfusion of oxygenated blood), concentration of HHb is statistically lower than baseline ($p < 0.05$).



Improving perfusion of the microcirculation allows optimization in the use of oxygen and glucose³⁹, stimulates activation and disposal of catabolites, which accumulate that contribute to inflammatory noxa. Furthermore Amato² has shown that the hemoreologic properties of ozone^{43,68,77} are greater than those of pentosifilline. Insulin-dependent diabetic patients, already during cycle of MAT (= Major Autohemotherapy), often had to reduce the therapeutic dose of insulin and antihypertensive drugs.

Bocci and Sammartino^{3,6,10} have documented that ozone, in right doses, not only does not seem to induce side effects, but induce an activation of enzymes (catalasi, superoxidodismutasi, glutathione...) instructed to inactivate free radicals^{3,6,26}. The final effect of activation of glutathione is reduction of disulfide bridges, with an effect of repairing proteins⁵².



A decreased activity of antioxidant enzymes is present in renal failure (superoxide dismutase, catalase, glutathione peroxidase), followed by an inevitable oxidative stress and an increased inflammatory response⁸¹. The effects of antioxidants and anti-inflammatory hemoreologic of ozone help to improve the deficit situation described above^{70,76}.

These results were crucial to stimulate us to experience the oxygen-ozone therapy as well as in vascular and degenerative diseases of the brain, even in autoimmune neurological disorders. The MAT bring significant clinical improvements, which allow a reduction, if not the suspension of corticosteroids and NSAIDs in patients with rheumatoid arthritis 33; clinical cure of recurring herpes skin infections in clinical particularly severe, a marked improvement in the pathology of asthma, such to allow a reduction of the load pharmacological.

In a study on the effect of ozone immunomodulatory published in 2001¹³, we have observed changes in lymphocyte subpopulations of 38 patients: results of particular interest are the data on the population examined 13 patients suffering from demyelinating disease and autoimmune (10 subjects with multiple sclerosis and 3 with rheumatoid arthritis). These patients were subjected periodically for 6 years in MAT. The analysis of the findings showed that T cells "helper / inducer" (subpopulation CD4 +), indicating adequate immune competence, were stable over time, and those related to activated T cells (subpopulation CD3 + HLA-DR +) were not increased

Concentrazioni (x10⁹/L) medie delle sottopopolazioni linfocitarie e rapporto CD4+/CD8+ prima e dopo il trattamento con ossigeno ozono

Sottopopolazioni linfocitarie	Prima	Dopo	P
CD 3 + (linfociti T)	1,477	1,570	0,270
CD3 + CD4 + (T helper/inducer)	0,994	1,103	0,078
CD3 + CD8 + (T suppressor/citototoxic)	0,474	0,438	0,442
CD19+ (linfociti NK)	0,255	0,227	0,302
CD3+ HLA DR+ (linfociti T attivati)	0,029	0,029	1
CD4+ /CD8+	2,371	2,821	0,045

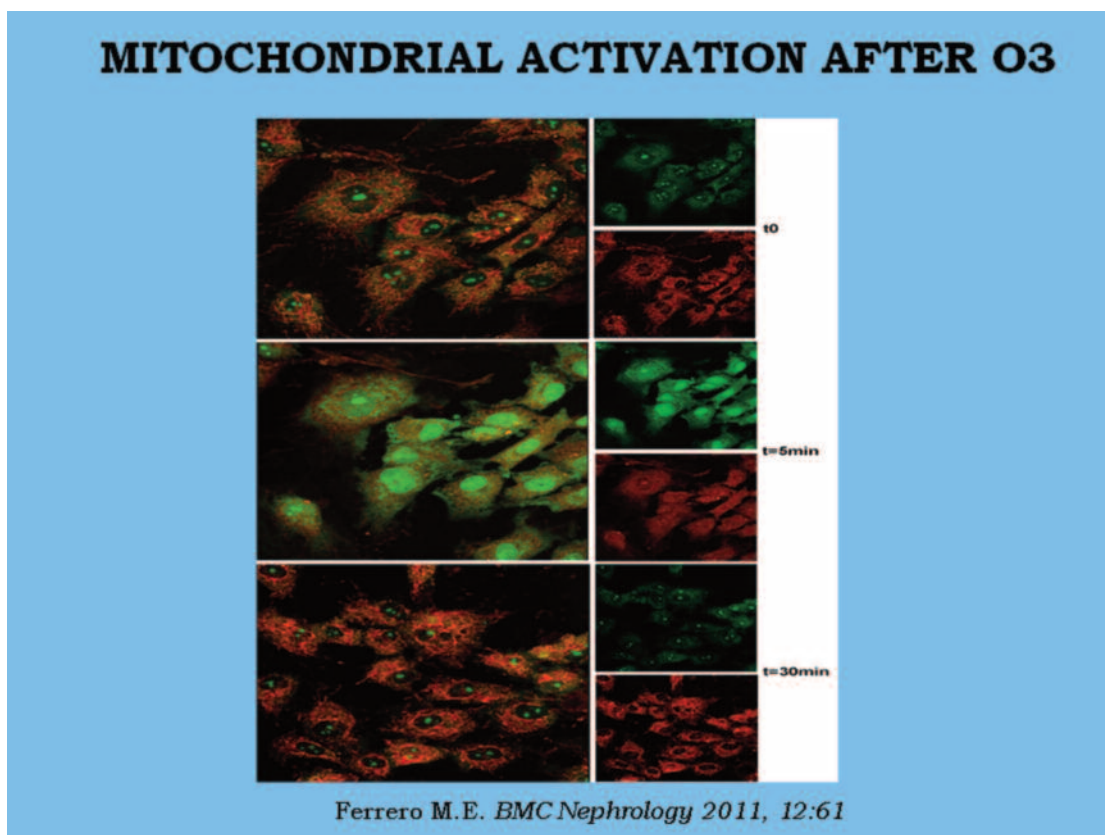
Il test T di Student evidenzia l'aumento significativo del rapporto CD4+/CD8+ e la stabilità della sottopopolazione linfocitaria CD3+ HLA DR+, indice di attività autoimmunitaria.

V. Simonetti, W. Liboni, P. Biancotti, A. Grillo. La malattia ischemica periferica (Franco Manusia), Tip Aurelia Grosseto, novembre 2001

Ohtsuka in 2006 showed that the ozone, at low concentrations, increases the ratio CD4⁺ / CD8⁺, because it stimulates the activity of T lymphocytes, whereas at higher concentrations leads to an increased production of anti-inflammatory cytokines, which is followed by a reduction of the CD14⁺, which normally appear already reduced in inflammatory diseases as they are recruited by cytokines in the peripher ⁵⁷.

Mezey and others have shown that stem cells from the bone marrow of adult animals transplanted in the brain of rats suffering from lymphoid leukemia, generate different types of brain cells, including endothelial cells, and white matter neurons, mainly in the hippocampus and cerebral cortex⁸⁷. According to some Bocci Lops induced by ozone would come up to the "substantia nigra", by activating stem cells silent and it would cause the differentiation together with a up regulation of cellular synthesis of antioxidant enzymes, crucial for a rebalancing of the cellular redox system. Probably these effects are due to an increase in the release of dopamine and / or neuronal growth factors determined precisely by Lops⁸⁶.

The clinical efficacy of ozone therapy and found no side effects^{28,30}, instead often present in many other drug therapy protocols, the clear successes of pain symptoms muscle, joint, astheniform, intercurrent infections and lymphedema¹², we have driven to test the application of ozone therapy in patients with multiple sclerosis (MS), after informed consent of the patient.



MULTIPLE SCLEROSIS¹²

Multiple sclerosis (MS) is a disease characterized by chronic inflammation and selective destruction of myelin in the central nervous system. The multifocal scarring typical of this disease are called plaques.

The incidence is 1/1.100 inhabitants. In Italy there are 54,000 patients and 1,800 new cases are diagnosed annually. The age of onset is between 15 and 50 years, most often between 20 and 30 years. In recent years we are seeing early even in subjects with more than 60 years. It is more common in women with a female / male ratio of 2:1. The most aggressive forms, however, are more common in men.

It is believed that the etiology is autoimmune, with a susceptibility determined by genetic and environmental factors such as viral infections, chronic poisoning by heavy metals and possibly a metabolic imbalance. In 2009, Prof Zamboni has speculated that an obstacle to the jugular venous outflow could be in correlation with the event and / or with the progression of MS. This hypothesis has been validated by several authors^{100, 101, 102}, but has not yet shared by many neurologists. We have noticed an obstructed outflow of the jugular veins in over 80% of the patients examined. As the venous defect is not the same in all patients, nor by extension or by type, we believe that percutaneous balloon angioplasty alone may not be sufficient to correct the flaw of all. In fact, we found small valvular thickening, hypoplasia more or less extensive,

markets and abnormal bifid into the subclavian... there seems to justify the clinical improvements, often not lasting after percutaneous angioplasty simple: you have to search for vascular surgical techniques and prosthetic materials other than those used so far. Remains to be seen whether the slow flow of the jugular is a cause, contributing cause or consequence of inflammatory disease brain.

As far as genetic predisposition, have been observed more than 140 mutations of genes: it seems that the mutation loci IL7R and IL2R (receptors for interleukins 7:02 respectively), increase by 30% the risk of developing the disease. This would explain the nature of the immune pathology, since the IL7R is involved in the activity of regulatory T cells, capable of suppressing the immune response. IL2R, however, facilitate the expression of MS, but I diabetes and autoimmune thyroiditis⁸⁸. It has been demonstrated the presence of Epstein Barr virus in all plaques at autopsy from patients with multiple sclerosis⁹⁷. Moreover, it seems also involved Herpes virus type 6A in relapsing-remitting⁹⁸.

In most cases, the MS starts with recurrent attacks of focal neurological dysfunction, which may last weeks or months, with a subsequent recovery of variable degree. In other cases, the disease presents with a slowly progressive neurological deterioration. Stressful conditions lead to a worsening of symptoms.

The manifestations are variable and include: weakness and / or sensory symptoms affecting a limb, visual difficulties, abnormal gait and coordination, urinary urgency or frequency, important asthenia. The most common sensory disturbances are localized paresthesias , sensations of " needle puncture " or " falling asleep " of a limb. Optic neuritis may cause fogging or blurring of vision , often associated with pain retro orbital. The involvement of the brain stem can cause diplopia , nystagmus , dizziness, facial pain, facial numbness and weakness , emispasmo or myokymia . The cerebellar involvement instead causes ataxia, tremor and dysarthria . The symptom of Lhermitte , ie a feeling of electric shock due to the flexion of the neck , is due to involvement of the cervical cord.

MS is a chronic disease. After about 15 years after diagnosis 20% of the cases has not functional limitations, in about half of patients the disease has progressed to secondary progressive MS with a need for assistance in walking.

For the purposes of diagnosis are needed medical history, neurological examination and magnetic resonance imaging of the brain. They are certainly useful for a differential diagnosis evoked potentials and examination of the cerebrospinal fluid.

There are 4 types of MS:

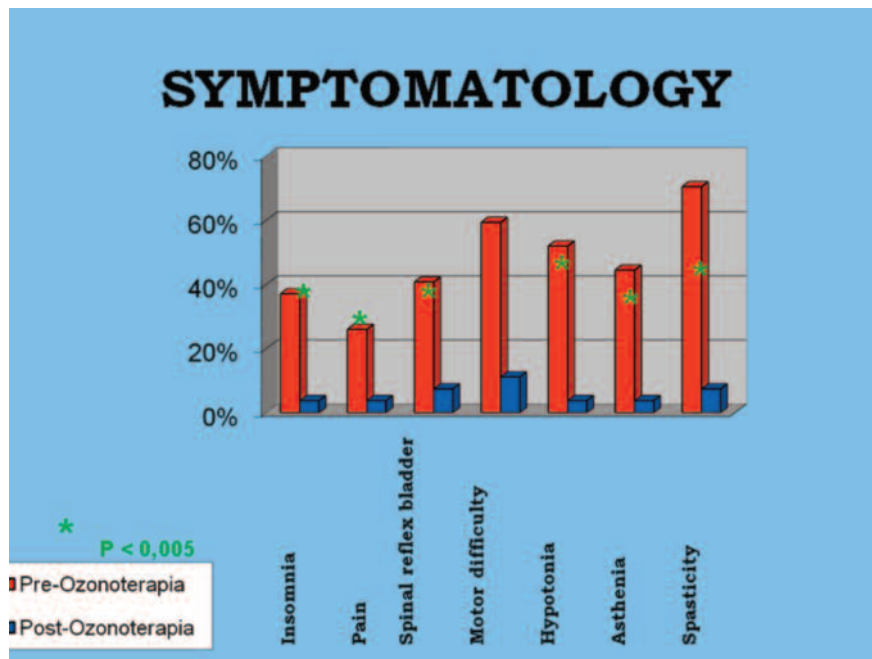
- 1) relapsing-remitting MS: recurrent attacks of neurological dysfunction with or without recovery. Not observed between the progression of neurological attacks
- 2) secondary progressive, starting with a picture of relapsing-remitting MS, but evolves gradually progressive
- 3) progressive primitive gradual progression of disability from the outset, affects approximately 15% of cases
- 4) progressive-relapsing: rare form that begins with progressive trend of primitive type, with subsequent occurrence of relapses

With regard to our series from 1996 to now, we have treated 43 MS patients including 23 progressive relapsing-remitting and 11 primary / secondary. Our end point was:

- 1) reduction of pain resulting from spasticity and / or postural changes
- 2) improvement of the sleep-wake rhythm
- 3) functional improvement of microcirculation venous lymphatic compromised by alterations in neuro-vegetative regulation and postural
- 4) improvement of neuro-vegetative functions and sphincters' control
- 5) slowing in the progression of the disease
- 6) improvement of kinesthetic
- 7) favorable influence on the timing of remission of pousses (especially short if treated within 72 hours of onset)
- 8) clinical cure urgent urination

It should be emphasized that the most obvious results were obtained in patients with relapsing-remitting MS, and were more nuanced in those suffering from a progressive primary / secondary, characterized by chronicity of symptoms and relief of major changes in the brain parenchyma and medullary . This improvement is manifested clinically by a recovery more or less evident depending on the severity, depending, that is, if the inflammatory lesion is still confined to the white matter or gray matter interest already, and chronicity of the disease state reached.

The clinical observations of patients treated enable us to state that the current tables of disability (FIM Ashwort ...) do not provide for the gradual enough to highlight the benefits of ozone, which also appear to significantly improve the quality of life of patients. Our clinical results are consistent with the proposed objectives.



PROTOCOL

- Indications: relapsing-remitting MS
- Contraindications: pregnant women (there are no studies on the possible teratogenicity effects of ozone) , hyperthyroidism, deficiency of glucose -6 -phosphate dehydrogenase .
- Interactions: not known interaction with other drugs
- Pharmacological action : anti-inflammatory and immunomodulatory effects ^{13,57 34} , muscle relaxant , improving perfusion of the microcirculation ⁵⁹ , activation of the mitochondrial antioxidant system , making it much more effective drug therapies ³⁷ or rehabilitation as it improves both the use and metabolism , while also allowing them a dose reduction , and the ability to repair some damage iatrogenic ^{15,16,19,36,48,58,65} . The reduction of spasticity and pain associated with the improvement of the autonomic functions and sphincter control, improving kinesthetic , reducing the time to remission of pousses and slowing the progression of the disease, involving a significant improvement in quality of life of these patients.
- Side effects: It is not nephrotoxic , hepatotoxic or not cardiotoxic , does not induce tumors or other metabolic disorders , does not increase the risk of thrombosis , it is not allergenic and does not induce the formation of autoantibodies ²⁸⁻³⁰ . The only side effects, in addition to those due to the needle puncture, can be consequent to emotional causes (vaso- vagal reflexes) .
- Twenty MAT, 2/week, 120-240 gr + blood Ozone-Oxygen 120 - 240ml / 40-55mcgr/ml followed by 1 session every 50 - 60gg . In case of POUSSE : immediately MAT every 2 days until disappearance of symptoms POUSSE

CONCLUSIONS

The Ozone, because of its actions referred to above, is a valid therapy for the pathophysiological changes and symptoms in the MS where it can make a significant improvement in the quality and expectancy of life, with no side effects and low cost therapeutic intervention. We believe that his association with the commonly used treatment protocols may improve clinical outcomes with a lower incidence of side effects. In addition, ozone therapy could represent a real therapeutic alternative for patients who can not be subjected to traditional drug treatment.

REFERENCES

- 1) Amato G. Valutazione dell'efficacia dell'ozonoterapia nel trattamento delle flebopatie degli arti inferiori. Impiego Ospedaliero - sezione scientifica 1992
- 2) Amato G. Valutazione dell'efficacia dell'ozonoterapia nelle arteriopatie croniche ostruttive degli arti inferiori: confronto con la terapia con Pentossifillina. Acta Toxic Ther, 1996;17:2-3
- 3) Bocci V. Verso una razionalizzazione dell'ozonoterapia. Acta Toxic Ther, 1996;17:2-3

- 4) Iliakis E. Utilizzo dell'ossigeno-ozonoterapia nella pratica ortopedica. *Acta Toxic Ther*, 1996;17:2-3
- 5) Lettieri B. Efficacia dell'ozonoterapia nella prevenzione della recidiva dell'infarto miocardico. *Acta Toxic Ther* 1996; 17:2-3
- 6) Sammartino A, Portolano. Biochimica e fisiologia dell'ozono. *Acta Toxic Ther* 1996;17:2-3
- 7) Raso A. Manuale di medicina e chirurgia vascolare. Ed Minerva Medica 1990
- 8) Riva Sanseverino E. Effects of oxygen-ozonotherapy on age-related degenerative retinal maculopathy. *Panminerva Medica* 1990; 32:77-84
- 9) Rokitansky O. Ossigeno-ozonoterapia nelle arteriopatie. Atti II congresso nazionale di ossigeno-ozonoterapia – Bergamo 19/10/'85
- 10) Sammartino A, Luongo C. Monitoraggio dei parametri biumorali negli epatopatici cronici trattati con ozonoterapia. *Acta Toxic Ther* 1996; 17:2-3
- 11) Valdenassi, Richelmi, Franzini M. L'ossigeno-ozonoterapia nell'insufficienza venosa cronica: studio clinico di efficacia e tollerabilità. *Flebologia* 1995
- 12) Kesslerling J. Multiple Sclerosis. Cambridge University Press 1997
- 13) Simonetti V, Liboni W, Biancotti P, Grillo A. La malattia ischemica periferica. *Manusia F Tip Aurelia* 2001
- 14) Marx J. Antibodies kill by producing Ozone. *Science*, 2002; 298:1319
- 15) Ajamieh HH, Menéndez S, Martínez-Sánchez G, Candelario-Jalil E, Re L, Giuliani A, Fernández OS. Effects of ozone oxidative preconditioning on nitric oxide generation and cellular redox balance in a rat model of hepatic ischaemia-reperfusion. *Liver Int* 2004; 24(1):55-62.
- 16) Barber E, Menendez S, Leon OS, Barber MO, Merino N, Calunga JL, et al. Prevention of renal injury after induction of ozone tolerance in rats submitted to warm ischemia. *Mediators Inflamm* 1999; 8:37–41
- 17) Bassi P, Strascini S. Ozone in the treatment of Herpes zoster. *Riv Neurobiol* 1982; 28(3-4): 328-333
- 18) Bezrukova IV, Petrukhina NB, Voinov PA. Experience in medical ozone use for root canal treatment. *Stomatologiya (Mosk)* 2005;84(6):20-2
- 19) Bocci V, Brito GS. Ozone therapy in critical patients. Rational of the therapy and proposed guidelines. *Rivista Italiana di Ossigeno-Ozono terapia* 2006; 5:7-11

- 20) Bocci V, Di Paolo N, Cappelletti F, Petrini G, Gaggiotti E. Necrotizing fasciitis successfully treated with extracorporeal blood oxygenation and ozonation (EBOO). *Int J Artif Organs* 2002; 25(12):1194-8.
- 21) Bocci V, Di Paolo N, Salvo DP, Palasciano G, Biagioli M, Meini S, Galli F, Ciari I, Maccari F, Cappelletti F, Di Paolo M, Gaggiotti E. Extracorporeal blood oxygenation and ozonation (EBOO): a controlled trial in patients with peripheral artery disease. *Int J Artif Organs* 2005; 28(10):1039-50.
- 22) Bocci V, Larini A. Effects of ozone on isolated peripheral blood mononuclear cells. *Toxicol In Vitro* 2005;19(1):55-61.
- 23) Bocci V, Luzzi E, Corradeschi F, Paulesu L, Di Stefano A. Studies on the biological effects of ozone: 3. An attempt to define conditions for optimal induction of cytokines. *Lymphokine Cytokine Res* 1993;12:121-6
- 24) Bocci V, Paulesu L. Studies on the biological effects of ozone 1. Induction of interferon gamma on human leucocytes. *Haematologica* 1990; 75:510-5
- 25) Bocci V, Travagli V, Zanardi I. A realistic evaluation of the action of ozone on whole human blood. *Int J Biol Macromol.* 2006; 39(4-5):317-20
- 26) Bocci V, Valacchi G, Corradeschi F, Aldinucci C, Silvestri S, Paccagnini E, et al. Studies on the biological effects of ozone: 7. Generation of reactive oxygen species (ROS) after exposure of human blood to ozone. *J Biol Regul Homeost Agents* 1998; 12:67-75
- 27) Bocci V. Does ozone therapy normalize the cellular redox balance? Implications for therapy of human immunodeficiency virus infection and several other diseases. *Med Hypotheses* 1996;46:150-154
- 28) Bocci V. Is it true that ozone is always toxic? The end of a dogma. *Toxicol Appl Pharmacol* 2006; 216(3):493-504
- 29) Bocci V. Ozone as a bioregulator. *Pharmacology and toxicology of ozonotherapy today.* *J Biol Regul Homeost Agents* 1996; 10(2-3):31-53
- 30) Bocci V. Ozone as Janus: this controversial gas can be either toxic or medically useful. *Mediators of Inflammation* 2004; 13(1):3-11
- 31) Bocci V. Ozonotherapy as a possible biological response modifier in cancer. *Forsch Komplementarmed (Research in Complementary Medicine)* 1998; 5:54-60
- 32) Bonetti M, Fontana A, Coticelli B, et al. Intraforaminal O₂-O₃ versus periradicular steroidal infiltrations in lower back pain: randomized controlled study. *Am J Neuroradiol* 2005; 26:996-1000

- 33) Chang JD, Lu HS, Chang YF, Wang D. Ameliorative effect of ozone on cytokine production in mice injected with human rheumatoid arthritis synovial fibroblast cells. *Rheumatol Int.* 2005; 26(2):142-51
- 34) Christian DL, Chen LL, Scannell CH, Ferrando RE, Welch BS, Balmes JR. Ozone-induced inflammation is attenuated with multiday exposure. *Am J Respir Crit Care Med* 1998;158:532–537
- 35) Chuprunova IN. Osteoplasty and ozone therapy in the treatment of a severe degree of generalized periodontitis. *Stomatologija (Mosk)* 1996; Spec No:90-1
- 36) Clavo B, Gutiérrez D, Martín D, Suárez G, Hernández MA, Robaina F. Intravesical ozone therapy for progressive radiation-induced hematuria. *J Altern Complement Med* 2005; 11(3):539-41
- 37) Clavo B, Perez JL, Lopez L et al. Ozone therapy for tumor oxygenation: a pilot study. *eCAM* 2004; 1(1):93-98
- 38) Clavo B, Perez JL, Lopez L, Suarez G, Lloret M, Rodriguez V, et al. Effect of ozone therapy on muscle oxygenation. *J Altern Complement Med* 2003;9:251–6
- 39) Coppola L, Giunta R, Verrazzo G, Luongo C, Sammartino A, Vicario C, Giugliano D. Influence of ozone on haemoglobin oxygen affinity in type-2 diabetic patients with peripheral vascular disease: in vitro studies. *Diabete Metab* 1995; 21(4):252-5
- 40) Daulbaeva AA, Bažakova GT. Effect of ozone on antibiotic sensitivity of microorganisms. *Stomatologija (Mosk)* 2003; 82(2):36-8
- 41) Dobkin VG, Sadovnikova SS et al. Local ozone therapy in the complex surgical treatment of pulmonary and peural tuberculosis patients. *Probl Tuberk* 2001; (7): 18-20
- 42) Fedorov AA, Gromov AS, Sapronek SV, Kurochkin Vlu, Zhernakova ZM. Ozone therapy in gastroduodenal pathology associated with *Helicobacter pylori*. *Vopr Kurortol Fizioter Lech Fiz Kult.* 2006; 6:34-7
- 43) Giunta R, Coppola A, Luongo C, Sammartino A, Guastafierro S, Grassia A, et al. Ozonized autohemotransfusion improves hemorheological parameters and oxygen delivery to tissues in patients with peripheral occlusive arterial disease. *Ann Hematol* 2001; 80:745–8
- 44) Hernandez F, Menendez S, Wong R. Decrease of blood cholesterol and stimulation of antioxidative response in cardiopathy patients treated with endovenous ozone therapy. *Free Radic Biol Med* 1995;19:115–9
- 45) Jacobson JS, Grann VR, Gnat MA, Hibshoosh H, Austin JH, Millar WS, Neugut AI. Cancer outcomes at the Hufeland (complementary/alternative medicine) klinik: a best-case series review. *Integr Cancer Ther* 2005; 4(2):156-67

- 46) Kelleher DK, Hummel M, Vaupel P. Lack of tumor oxygenation improvement upon ozone therapy in experimental tumors. *Strahlenther Onkol* 2000; 176:115
- 47) Kiniapina ID, Durnovo EA. The efficacy of using ozone in the combined treatment of disseminated odontogenic phlegmons of the maxillofacial area. *Stomatologija (Mosk)*. 1996;Spec No:60-1
- 48) Kiriakov VA, Saarkoppel' LM, Zheglova AV. Pathogenetic basis for ozone therapy as a modality to treat vibration disease (literature review). *Med Tr Prom Ekol* 2006;(5):12-6
- 49) Kudriavtsev EP, Miroshin SI, Semenov SV, Snigorenko AS, Sidorovich IA. Ozone therapy of diffuse peritonitis in the early postoperative period. *Khirurgija (Mosk)* 1997; (3):36-41
- 50) Kulikov AG, Turova EA, Shcherbina TM, Kisileva OM. Efficacy of different methods of ozone therapy in vascular complications of diabetes mellitus. *Vopr Kurortol Fizioter Lech Fiz Kult*. 2002; 5:17-20.
- 51) Lapina IM, Sinel'shchikova IV. Ozone therapy in ophthalmology. *Vestn Oftalmol*. 1998; 114(6):51-4
- 52) Leon OS, Menendez S, Merino N, Castillo R, Sam S, Perez L, et al. Ozone oxidative preconditioning: a protection against cellular damage by free radicals. *Mediators Inflamm* 1998; 7:289–94.
- 53) Madej P, Plewka A, Janusz A. Ozone Therapy in Induced Endotoxemic Shock. II. The Effect of Ozone Therapy Upon Selected Histochemical Reactions in Organs of Rats in Endotoxemic Shock. *Inflammation*, 2007
- 54) Mustafaev EM, Martov AG, Naumov AG, Siniukhin VN, Shakir F, Merinov DS, Amelin AV, Al'bitskaia Alu. The role of ozone therapy in prevention of pyoinflammatory complications after transurethral resection of prostatic adenoma. *Urologija*. 2007; 1:18-23, 27.
- 55) Nedogoda VV, Razvaliaeva OV, Kulikov AG. Effect of ozonotherapy on lipid peroxidation in patients with chronic diffuse liver diseases. *Vopr Kurortol Fizioter Lech Fiz Kult* 2001; 4:19-21
- 56) Neroev VV, Zueva MV, Tsapenko IV. Effects of ozone therapy on the functional activity of the retina in patients with involutinal central chorioretinal dystrophy. *Vestn Oftalmol* 2003;119(6):18-21
- 57) Ohtsuka H, Ogata A, Terasaki N, Koiwa M, Kawamura S. Changes in leukocyte population after ozonated autohemoadministration in cows with inflammatory diseases. *J Vet Med Sci* 2006; 68(2):175-8
- 58) Pawlak O, Kaźmierczak H, Kaźmierczak W, Szpoper M. Ozone therapy and pressure-pulse therapy in Ménière's disease. *Int Tinnitus J* 2004; 10(1):54-7

- 59) Peralta C, Leon OS, Xaus C, Prats N, Jalil EC, Planell ES, et al. Protective effect of ozone treatment on the injury associated with hepatic ischemia-reperfusion: antioxidant-prooxidant balance. *Free Radic Res* 1999; 31:191–6
- 60) Plopper CG, Duan X, Buckpitt AR, Pinkerton KE. Dose-dependent tolerance to ozone. IV. Site-specific elevation in antioxidant enzymes in the lungs of rats exposed for 90 days or 20 months. *Toxicol Appl Pharmacol* 1994;127(1):124-31.
- 61) Romero A, Menendez S, Gomes M, Ley J. La ozonoterapia en los estadios avanzados de la aterosclerosis obliterante. *Angiologia* 1993;45:146-8
- 62) Rovira G, Ralindo N. La ozonoterapia en el tratamiento de las úlceras crónicas de las extremidades inferiores. *Angiologia* 1991;2:47-50
- 63) Sroczyński J, Antoszewski Z, Matyszczyk B, Krupa G, Rudzki H, Zbrońska H, Skowron J. Clinical assessment of treatment results for atherosclerotic ischemia of the lower extremities with intraarterial ozone injections. *Pol Tyg Lek* 1992 ;47(42-43):964-6.
- 64) Sroczyński J, Antoszewski Z, Rudzki H, Matyszczyk B, Kuźniewicz R. Various parameters of lipid metabolism after intra-arterial injections of ozone in patients with ischemia of the lower extremities and diabetes mellitus. *Pol Tyg Lek*1990; 45(47-48):953-5.
- 65) Subbotin VM, Zitta DV, Terekhina NA. Prophylaxis of acute postoperative gastroduodenal ulcers at the patients with colorectal cancer. *Khirurgiia (Mosk)*. 2007;3:4-6.
- 66) Sunnen GV. Hepatitis C and Ozone therapy. *Ozone in Medicine*,2001
- 67) Sunnen GV. Possible mechanism of viral inactivation by ozone. *Ozone in Medicine*,1994
- 68) Terekhina NA, Zitta DV, Subbotin VM. The activity of adenosinetriphosphatase of erythrocytes in peripheral blood of patients with colorectal cancer. *Klin Lab Diagn* 2005;5:20-2.
- 69) Turczyński B, Sroczyński J, Antoszewski Z, Matyszczyk B, Krupa G, Młynarski J, Strugala M. Ozone therapy and viscosity of blood and plasma, distance of intermittent claudication and certain biochemical components in patients with diabetes type II and ischemia of the lower extremities. *Pol Tyg Lek* 1991; 46(37-39):708-10.
- 70) Tylicki L, Biedunkiewicz B, Lizakowski S, Skibońska A, Niewegłowski T, Chamienia A, Debska-Slizien A, Rutkowski B. Blood coagulation unaffected by ozonated autohemotherapy in patients on maintenance hemodialysis. *Arch Med Res* 2006; 37(8):1034-7.
- 71) Tylicki L, Biedunkiewicz B, Niewegłowski T, Burakowski S, Rutkowski B. Clinical efficacy of ozonated autohemotherapy in hemodialyzed patients with intermittent claudication: an oxygen-controlled study. *Int J Artif Organs* 2004; 27(1):29-34

- 72) Tylicki L, Biedunkiewicz B, Nieweglowski T, Chamienia A, et al. Ozonated autohemotherapy in patients on maintenance hemodialysis: influence on lipid profile and endothelium. *Artif Organs* 2004; 28(2):234-7
- 73) Tylicki L, Biedunkiewicz B, Nieweglowski T, Grabowska M, Chamienia A, Slizien AD, Rutkowski B. Fistula function and dialysis adequacy during ozonotherapy in chronically hemodialyzed patients. *Artif Organs* 2004; 28(5):513-7
- 74) Tylicki L, Biedunkiewicz B, Rachon D, et al. No effects of ozonated autohemotherapy on inflammation response in hemodialyzed patients. *Mediators of Inflammation*, 2004; 13(5/6):377-380
- 75) Tylicki L, Biedunkiewicz B, Rachon D, Hak L, et al. Natural killer cell activity unaffected by ozonated autohemotherapy in patients with end-stage renal disease on maintenance renal replacement therapy. *Int J Artif Organs* 2004; 27(9):766-71
- 76) Tylicki L, Niew głowski T, Biedunkiewicz B, Burakowski S, Rutkowski B. Beneficial clinical effects of ozonated autohemotherapy in chronically dialysed patients with atherosclerotic ischemia of the lower limbs--pilot study. *Int J Artif Organs* 2001; 24(2):79-82.
- 77) Valacchi G, Bocci V. Studies on the biological effects of ozone: 11. Release of factors from human endothelial cells. *Mediators Inflamm* 2000; 9:271-6
- 78) Vasil'ev IT, Markov IN, Mumladze RB, Belopol'skiĭ AA, Vasina TA. The antibacterial and immunocorrective action of ozone therapy in peritonitis. *Vestn Khir Im I I Grek* 1995; 154(3):56-60
- 79) Verazzo G, Coppola L, Luongo C, Sammartino A, Giunta R, Grassia A, Ragone R, Tirelli A. Hyperbaric oxygen, oxygen-ozone therapy, and rheologic parameters of blood in patients with peripheral occlusive arterial disease. *Undersea Hyperb Med* 1995; 22(1):17-22.
- 80) Wentworth P Jr, Mc Dunn Je, et al. Evidence for antibody-catalysed ozone formation in bacterial killing and inflammation.. *Science* 2002; 298: 2195-2199
- 81) Vaziri ND, Dicus M et al. *Kidney Int.* 2003;63(1):179-85
- 82) Payr E. *Über Ozonbehandlung in der chirurgie. Munch. Med. Wochenschr* 1935;82:220-291
- 83) *Bollettino d'informazione sui farmaci*, n. 2, 2007
- 84) www.farmaciaonline.it
- 85) European Medicines Agency (EMA), 5-2006
- 86) *Ozone: a new medical drug.* Springer 2005;147-148

- 87) Mezey E, Key S, Vogelsang G, Szalayova I, Lange GD, Crain B. Transplanted bone marrow generates new neurons in human brains. *Proc Natl Acad Sci USA* 2003;100(3):1364-9
- 88) Hafler DA, Compston A, Sawcer S et al. Risk alleles for multiple sclerosis genetics consortium. *N Engl J Med* 2007; 357
- 89) Frisullo G et al. Glucocorticoid treatment reduces T-bet and pSTAT1 expression in mononuclear cells from relapsing remitting multiple sclerosis patients. *Clinical immunology on line* 2007
- 90) Rogoff K. Il Sole 24 ore 19/08/2007
- 91) Khan OA, Tselis AC, Kamholz JA, Garbern JY, Lewis RA, Lisak RP. A prospective, open-label treatment trial to compare the effect of IFN beta-1a (Avonex), IFNbeta-1b (Betaseron), and glatiramer acetate (Copaxone) on the relapse rate in relapsing-remitting multiple sclerosis. *Eur J Neurol* 2001;8(2):141-148
- 92) Limmroth V, Malessa R, Zettl UK et al. Quality Assessment in Multiple Sclerosis Therapy (QUASIMS): a comparison of interferon beta therapies for relapsing-remitting multiple sclerosis. *J Neurol* 2007;254(1):67-77
- 93) Polman CH et al. A Randomized, Placebo-Controlled Trial of Natalizumab for Relapsing Multiple Sclerosis. *N Engl J Med* 2006; 354:899-910
- 94) Rudick RA et al. Natalizumab plus Interferon Beta-1a for Relapsing Multiple Sclerosis. *N Engl J Med* 2006;354:911-923
- 95) Lugesesi A, Caporale C, Farina D, Marzoli F, Bonanni L, Muraro PA, De Luca G, Iarlori C, Gambi D. Low-dose oral methotrexate treatment in chronic progressive multiple sclerosis. *Neurol Sci* 2001;22(2):209-10
- 96) Gladstone DE, Zamkoff KW, Krupp L et al. High-dose cyclophosphamide for moderate to severe refractory multiple sclerosis. *Arch Neurol* 2006; 63: 1388-1393
- 97) Aloisi F et al. Dysregulated Epstein-Barr virus infection in the multiple sclerosis brain. *J Exp Med* Nov.2007
- 98) Alvarez-Lafuente R et al. Human herpesvirus-6 and multiple sclerosis: relapsing-remitting versus secondary progressive. *Mult Scler* 2007; 13:578-583
- 99) Zamboni P. Chronic cerebrospinal venous insufficiency in patients whit multiple sclerosis. *J.Neurol.Neurosurg Psychiatry* 2009;80:392-9
- 100) Yamout B. Extracranial venous stenosis is an unlikely cause of Multiple Sclerosis *Mult Scler* 2010 Nov.;16:1341

101) Simka M. Prevalence of extracranial venous abnormalities: results from a sample of 586 multiple sclerosis patients J Endovasc Ther 2011;18:314-23

102) Lugli M. The hypothesis of patho-physiological correlation between chronic cerebrospinal venous insufficiency and multiple sclerosis. Rationale of treatment. Flebology 2012;01:24-25