

Atypical Mycobacterial Infection after a Routine Transcutaneous Blepharoplasty: A Case and Review of the Current Literature



Jillian W. Wong, M.S.
Clinical Research Investigator at the University of California, San Francisco, Department of Dermatology, Psoriasis and Skin Treatment Center. Medical Student at the University of Utah School of Medicine.



Siegrid S. Yu, M.D.
Assistant Professor of Clinical Dermatology at the University of California, San Francisco, Dermatologic Surgery and Laser Center.

INTRODUCTION

Atypical mycobacteria, also referred to as nontuberculous mycobacteria or environmental mycobacteria, are characterized by their lack of pigmentation and rapid growth in culture^{1,2}. These organisms are found in soil, dust, and water, and may colonize gastric secretions, sputum, and the skin. Often, when they cause cutaneous infections, they are preceded by minor trauma, injections, or surgery³. Immunocompromised patients are more likely to be affected. However, other risk factors include advanced age, malnutrition, diabetes mellitus, obesity, chronic renal failure, and corticosteroid use.

These rapidly growing organisms are classified according to Runyon groups I-IV. Runyon subtype IV atypical mycobacteria are known to have greater pathogenicity than subtypes I-III, and demonstrate rapid growth of colonies within three to seven days. The most dominant human pathogens of Runyon group IV are *Mycobacterium chelonae*, *Mycobacterium fortuitum*, and *Mycobacterium abscessus*.

Atypical mycobacterial infection is uncommon after dermatological cosmetic surgery. Indeed, wound infections following micrographic procedures occur in less than 3% of cases⁴. More typical infections complicating

surgical procedures are secondary to *Staphylococcus epidermidis*, *Staphylococcus aureus*, and *Pseudomonas aeruginosa*⁴⁻⁸. Herein, we report a case of atypical mycobacterial infection following a routine upper and lower transcutaneous blepharoplasty in a healthy, non-immunocompromised patient.

CASE REPORT

A healthy 60-year-old Caucasian female presented with painful, draining erythematous papules on her eyelids six weeks after a transcutaneous blepharoplasty. No peri-operative complications were noted by the plastic surgeon. She had no significant medical history, medication history, or review of systems. She had no exposure to marine life, aquariums, or nail salons.

Examination showed eyelid edema and multiple 4- to 6-mm erythematous, tender draining papules on the eyelids, bilaterally localized to the surgical incision sites (Figures 1-3). Nodules expressed seropurulent discharge.

Differential diagnosis included suture reaction versus infection. Culture of the nodules grew rare gram-positive rods, 'possibly diphtheroids', but a two-week course of levofloxacin showed minimal improve-

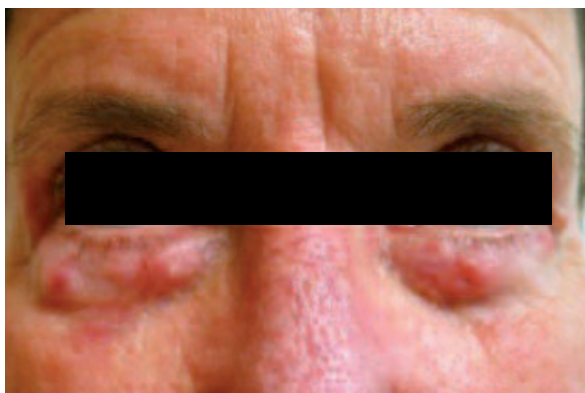

Figura 1. Post-operative infection: Visible nodules six weeks after blepharoplasty.

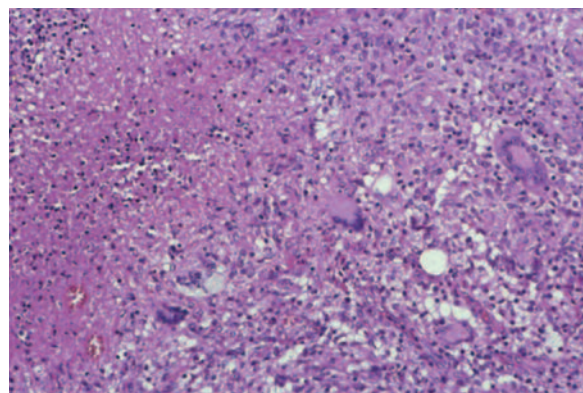


Figura 4. Histological examination of nodule: Suppurative and granulomatous dermatitis.

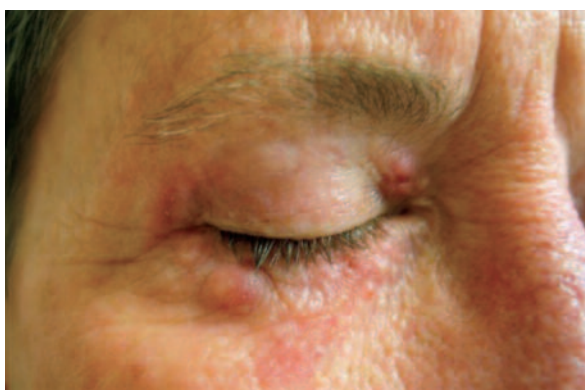

Figura 2. Right upper and lower eyelids: Erythema and visible nodules six weeks after blepharoplasty.

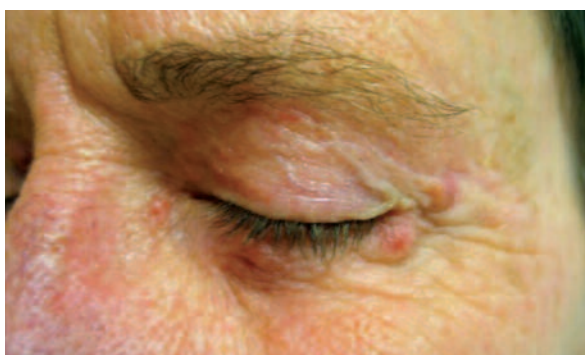

Figura 3. Left upper and lower eyelids: Erythema and visible nodules six weeks after blepharoplasty.

ment. A skin biopsy was then performed and histopathology demonstrated suppurative and granulomatous dermatitis, confirming an infection

(Figure 4). Acid-fast bacilli stain and bacterial, fungal, and atypical mycobacterial cultures were negative. Based on the clinical presentation, atypical mycobacterial infection was suspected, and the patient was treated empirically with clarithromycin 500 mg twice daily for four months. On examination at one-month follow-up, the patient showed a 70 % improvement, with complete resolution of the infection on follow-up at six months.

DISCUSSION

Clinically, an atypical mycobacterial infection presents as multiple or single nodules, which may involve the suture line, or as a periocular or orbital mass. Orbital cellulitis may precede development of the nodules. There may also be inflammatory signs such as tenderness and erythema, and development of abscesses with drainage. Unlike the usual period of presentation for post-operative staphylococcal infections, the presentation of atypical mycobacterial infections is delayed. The median time for presentation of infection following surgical procedures is longer, 30 days, ranging from 18 to 24 days⁹. Our patient began presenting symptoms six weeks after surgery, which was even more delayed compared to staphylococcal infections, and outside the typical range for presentation of atypical mycobacterial infection. The median time

from illness onset to diagnosis of mycobacterium infection is 21 days, ranging from 8 to 38 days⁹. Although disseminated disease has been reported in immunosuppressed cases, in general, there are no associated systemic manifestations.

Diagnosis of mycobacteria can be made by tissue biopsy or culture. Examination of the sample tissue demonstrates non-caseating granulomas, necrosis, polymorphonuclear microabscesses, and giant cells¹⁰. Acid-fast bacilli staining may be positive in some cases¹¹.

Treatment of an atypical mycobacterial infection is determined by the clinical symptoms and antibiotic susceptibility. In general, these organisms are resistant to the usual antituberculous therapies. Often, patients can be given single or combination therapy with amikacin, cefoxitin, clarithromycin, sulfonamide, imipenem, doxycycline, and ciprofloxacin. All foreign bodies should be removed if present. If medication and abscess drainage are ineffective, surgical intervention may be needed¹. Treatment usually resolves without scarring. However, patients may have prolonged post-inflammatory hyperpigmentation.

REFERENCES

1. American Thoracic Society, Medical Section of the American Lung Association. Diagnosis and treatment of disease caused by nontuberculous mycobacteria. *Am J Respir Crit Care Med.* 1997; 156: S1-25. PMID: 9279284.
2. Ulsan DZ, Kowalski TJ, Wengenack NL, Virk A, Wilson JW. Skin and Soft Tissue infections Due to Rapidly Growing Mycobacteria. *Arch Dermatol.* 2006; 142: 1287-92. PMID: 17043183.
3. Wallace Jr RJ, Swenson JM, Silcox VA, et al. Spectrum of disease due to rapidly growing mycobacteria. *Rev Infect Dis.* 1983; 5: 657-79. PMID: 6353528.
4. Futoryan T, Grande D. Postoperative wound infection rates in dermatologic surgery. *Dermatol Surg.* 1995; 21:509-14. PMID: 7773598.
5. Christian MM, Behroozan DS, Moy RL. Delayed infections following full-face CO2 laser resurfacing and occlusive dressing use. *Dermatol Surg.* 2000;26:32-6. PMID: 10632683.
6. Ross EV, Amesbury EC, Barile A, Proctor-Shipman L, Feldman BD. Incidence of postoperative infection or positive blood culture after facial laser surgery: a pilot study, a case report, and a proposal for a rational approach to antibiotic prophylaxis. *J Am Acad Dermatol.* 1998;39: 975-81. PMID: 9843012.
7. Sriprachya-Anunt S, Fitzpatrick RE, Goldman MP, Smith SR. Infections complicating pulsed carbon dioxide laser resurfacing for photoaged facial skin. *Dermatol Surg* 1997;23:527-35. PMID: 9236870.
8. Walia S, Alster TS. Cutaneous CO2 laser resurfacing infection rate with and without prophylactic antibiotics. *Dermatol Surg.* 1999;25:857-61. PMID: 10594597.
9. Centers for Disease Control. Mycobacterium chelonae Infections Associated with Face Lifts – New Jersey, 2002-2003. *MMWR* 2004; 53: 192-4. PMID: 15017374.
10. Garman ME, Orengo I. Unusual infectious complications of dermatologic procedures. *Dermatol Clin.* 2003; 21:321-35. PMID: 12757255.
11. Wallace Jr RJ, Tanner D, Brennan PJ, et al. Clinical trial of clarithromycin for cutaneous (disseminated) infection due to Mycobacterium chelonae. *Ann Intern Med.* 1993; 119: 482-6. PMID: 8357113.